Cervical Radiculopathy

John M. Rhee, MD
Tim Yoon, MD
K. Daniel Riew, MD

Abstract

Cervical radiculopathy is a disorder involving dysfunction of cervical nerve roots that commonly manifests as pain radiating from the neck into the distribution of the affected root. Acute cervical radiculopathy generally has a self-limited clinical course, with up to a 75% rate of spontaneous improvement. Thus, nonsurgical treatment is the appropriate initial approach for most patients. When nonsurgical treatment fails to relieve symptoms or if a significant neurologic deficit exists, surgical decompression may be necessary. Surgical outcomes for relief of arm pain range from 80% to 90% with either anterior or posterior approaches.

Dr. Rhee is Assistant Professor, Orthopaedic Surgery, Emory University School of Medicine, Atlanta, GA. Dr. Yoon is Assistant Professor, Orthopaedic Surgery, Emory University School of Medicine. Dr. Riew is Professor, Orthopaedic Surgery, Washington University, St. Louis, MO.

None of the following authors or the departments with which they are affiliated has received anything of value from or owns stock in a commercial company or institution related directly or indirectly to the subject of this article: Dr. Rhee, Dr. Yoon, and Dr. Riew.

Reprint requests: Dr. Rhee, Emory Spine Center, Emory University School of Medicine, Suite 3000, 59 Executive Park South, Atlanta, GA 30329.

J Am Acad Orthop Surg 2007;15:486-494

Cervical radiculopathy typically manifests as pain radiating from the neck into the distribution of the affected root. The exact location and pattern of pain may vary widely, and a classic dermatomal distribution of pain is not always present. Associated sensory, motor, and reflex disturbances may or may not be present. Because acute cervical radiculopathy generally has a self-limited clinical course, nonsurgical treatment is the appropriate initial approach for most patients. Surgical treatment may be considered when nonsurgical treatment fails and in the patient with a significant neurologic deficit.

Pathoanatomy

Cervical nerve root compression may occur through several causes. First, nuclear material arising from acute soft disk herniations may impinge on the exiting nerve root posterolaterally at its take-off from the spinal cord (Figure 1), or intraforaminally as it traverses the neuroforamen. Second, chronic disk degeneration with resultant disk height loss may lead to so-called hard disk pathology (Figure 2), caused by annular bulging without frank herniation or by the formation of degenerative osteophytes, which typically arise from the uncinate regions of the posterolateral vertebral body (uncovertebral osteophytes). Both tend to compress the exiting nerve root as it enters the neuroforamen. It can be difficult to differentiate soft versus hard disk pathology on magnetic resonance imaging (MRI) alone. Myelography is not routinely needed in the patient with a high-quality MRI when the purpose is to delineate hard versus soft disk pathology. A noncontrast computed tomography (CT) scan can be used in such circumstances to complement information obtained on MRI. Third, disk height loss may result in loss of foraminal height; combined with superior migration of the superior facet joint from the subjacent vertebra, this can lead to subsequent foraminal root compression. Finally, hypertrophy of the facet joints may cause foraminal encroachment. Overall, anteriorly based pathology arising from soft and hard disks accounts for most instances of nerve root compression.

In addition to the effect of direct compression, stretching of the nerve

Figure 1

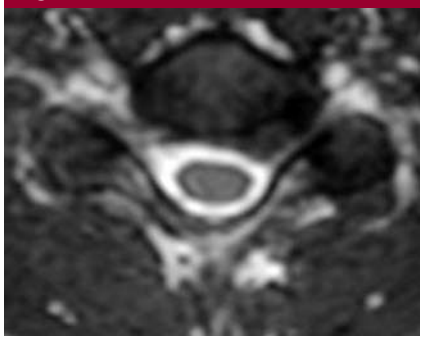

Axial T2-weighted magnetic resonance imaging scan demonstrating left posterolateral soft disk herniation with compression of the exiting root.

Figure 2

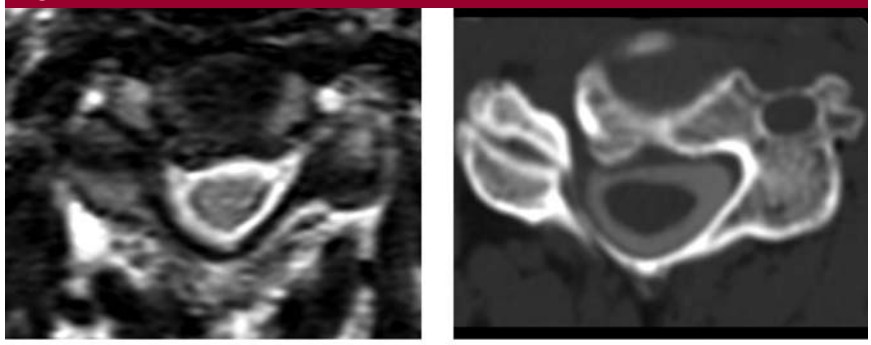

A B

A, Axial T2-weighted magnetic resonance imaging scan demonstrating an uncovertebral spur, greater on the right side than on the left. **B,** Axial postmyelogram computed tomography scan confirms that the compressive entity in panel A is an uncovertebral spur rather than soft disk material. The axial slice cuts obliquely through the disk space and through the foramen on the right, versus the pedicle on the left.

root may generate pain. The dorsal and ventral rootlets arise from the spinal cord and coalesce into the root proper, after which the root courses ventrolaterally at an approximately 45° angle to enter the neuroforamen. This trajectory renders the root vulnerable to stretch over ventral lesions, such as disk herniations and osteophytes emanating from the uncinate region. In some patients, significant pain relief may be obtained by abducting the arm, which presumably decreases the amount of stretch and tension the nerve root encounters over the compressive lesion (ie, shoulder abduction relief sign).

Stimulation of the nerve root by chemical pain mediators within the disk also may contribute to the production of symptoms. Herniated disk materials may incite the production of various inflammatory cytokines, such as interleukin (IL)-1 and IL-6. Substance P, bradykinin, tumor necrosis factor-α, and prostaglandins are other pain mediators known to be involved in radiculopathy.

Clinical Evaluation

The patient with cervical radiculopathy typically reports variable degrees of pain and/or neurologic dysfunction along a nerve root distribution. In contrast to the patient with isolated axial neck pain, the patient with radiculopathy more frequently has unilateral neck pain that then radiates ipsilaterally into the distribution of the affected nerve root. Common pain and neurologic patterns associated with radiculopathies of the cervical nerve roots are listed in Table 1. The most common levels of root involvement are C6 and C7; high cervical radiculopathies (C2-C4) are less common. It is important to note, however, that the absence of radiating symptoms in a dermatomal distribution does not rule out the presence of symptomatic nerve root compression. Regardless of the root level that is compressed, a patient may report upper trapezial and interscapular pain. In many patients with cervical root compression, the focal point of pain is not uncommonly the shoulder girdle area, regardless of the root level involved, and the symptoms may not radiate any farther down the arm.

A careful physical examination should be performed to identify the nerve root involved, with the caveat that crossover between myotomes and dermatomes may be present. Cervical nerve roots exit above their correspondingly numbered pedicles; for example, the C6 root exits between C5 and C6. The exception to this rule is the C8 root, which exits above the T1 pedicle. In contrast to the lumbar spine, where posterolateral pathologies usually impinge on the traversing nerve roots and foraminal pathologies on the exiting nerve roots, compressive lesions in the cervical spine tend to produce radiculopathy of the exiting nerve root. For example, both a posterolateral C5-C6 disk herniation and C5-C6 foraminal stenosis from an uncovertebral osteophyte usually lead to C6 radiculopathy. It is possible, however, for a large central to midlateral disk herniation or stenosis to affect the subjacent root.

Motor strength is graded on a standard 0-5 scale. Sensory testing should include at least one function from the dorsal columns (eg, joint position sense, light touch) and the spinothalamic tract (eg, pain, temperature sensation). To determine the presence of coexisting myelopathy or other neurologic disorder, the patient also should be evaluated for upper motor neuron signs, such as Hoffmann's sign, inverted brachioradialis reflex, clonus, and Babinski's sign, as well as gait instability.

Table 1

Common Cervical Radiculopathy Patterns

Root	Symptoms	Affected Motor Function	Reflex
C2	Posterior occipital headaches, temporal pain	—	—
C3	Occipital headache, retro-orbital or retroauricular pain	—	—
C4	Base of neck, trapezial pain	—	—
C5	Lateral arm pain	Deltoid	Biceps
C6	Radial forearm pain, pain in the thumb and index fingers	Biceps, wrist extension	Brachioradialis
C7	Middle finger pain	Triceps, wrist flexion	Triceps
C8	Pain in the ring and little fingers	Finger flexors	—
T1	Ulnar forearm pain	Hand intrinsics	—

— = no reflex associated

Figure 3

The Spurling sign is elicited by extending and rotating the neck toward the symptomatic side. Reproduction of symptoms suggests cervical root compression as the etiology.

Several provocative tests may elicit or reproduce symptoms of radiculopathy. The Spurling test is performed by maximally extending and rotating the neck toward the involved side (Figure 3). Doing so narrows the neuroforamen and may reproduce the patient's symptoms. When positive, this test is particularly useful in differentiating cervical radiculopathy from other etiologies of upper extremity pain, such as peripheral nerve entrapment disorders, because the maneuver stresses only the structures within the cervical spine. Improvement or relief of symptoms may occur when the patient subsequently flexes and rotates the neck to the opposite side, as this maneuver opens up the neuroforamen.

The differential diagnosis of cervical radiculopathy includes peripheral nerve entrapment syndromes (eg, carpal or cubital tunnel syndromes); brachial plexus injury; Parson Turner's syndrome; and tendinopathies of the shoulder, elbow, and wrist. Selective cervical nerve root injections can be useful in confirming the source of symptoms if they improve for a time after the injection. Electromyography and nerve conduction tests may help differentiate radiculopathy from peripheral entrapment disorders. Because false positive and negative electrodiagnostic studies are not uncommon, however, the results must be interpreted in the context of the entire clinical and radiographic presentation and should never be the sole determinant for planning treatment. Visceral disorders, such as coronary artery disease and cholecystitis, both of which cause referred pain to the upper extremity, also should be considered in the differential diagnosis.

Radiographic Evaluation

Plain radiographs may reveal decreased disk height and osteophyte formation. However, advanced imaging is usually obtained to better visualize neural anatomy in the patient who does not respond well to nonsurgical management or who has severe symptoms. Because MRI evidence of nerve root compression may occur in 19% of asymptomatic individuals,[1] the diagnosis is made only by matching clinical signs and symptoms with the radiologic abnormality. In addition to standard radiographs, MRI scans are helpful in demonstrating herniated disks as well as central and foraminal stenosis (Figure 4).

CT myelography is an invasive study that can demonstrate mechanical blocks to the flow of cerebrospinal fluid. MRI is noninvasive and may be better at identifying disk herniations (particularly those that are intraforaminal) and intrinsic spinal cord lesions, whereas CT myelography may be better at detecting foraminal stenosis and delineating whether root compression arises from hard versus soft disk pathology.[2] The images obtained with either modality depend in part on the position of the neck at the time of acqui-

sition. MRI and postmyelogram CT images are most commonly obtained with the patient supine, which promotes a neutral or slightly flexed sagittal contour to the neck. This positioning may result in underdiagnosis of conditions that are symptomatic in the extremes of flexion (eg, mild disk herniation) or extension (eg, mild foraminal stenosis).

Nonsurgical Management

Natural History

In the classic study by Lees and Turner,[3] the natural history of cervical radiculopathy was demonstrated to be generally favorable. At long-term follow-up (2-19 years) of 51 patients with radiculopathy, 45% had only a single episode of pain without recurrence, 30% had mild symptoms, and only 25% had persistent or worsening symptoms. No radiculopathic patient progressed to myelopathy in this series. Because the natural history often seems to favor resolution, nonsurgical treatment is the initial treatment of choice in most patients. The literature does not define a regimen of effective nonsurgical care, however. Because there are no controlled trials comparing the various nonsurgical regimens (eg, physical therapy, modalities, traction, medication, manipulation, immobilization) versus the natural history (ie, no treatment at all), it remains unclear whether nonsurgical management actually improves on the natural history of the disorder or simply treats the symptoms as the disorder runs its course.

Immobilization

Immobilization of the neck with a cervical collar is thought to diminish inflammation around an irritated nerve root and may also diminish muscle spasm. Alternatively, the warmth provided by wearing the collar may be therapeutic. The efficacy of collars in limiting the duration or severity of radiculopathy has not been demonstrated, however.[4] Even in patients without radiculopathy who have only neck pain, soft collars have not demonstrated an effect on the duration or degree of neck pain. Although short-term use of collars may be beneficial, prolonged immobilization of more than 1 to 2 weeks should be avoided to prevent atrophy of the cervical musculature. Some patients may be more comfortable wearing a soft collar backward, which promotes relative flexion of the neck and thus, enlargement of neuroforaminae.

Figure 4

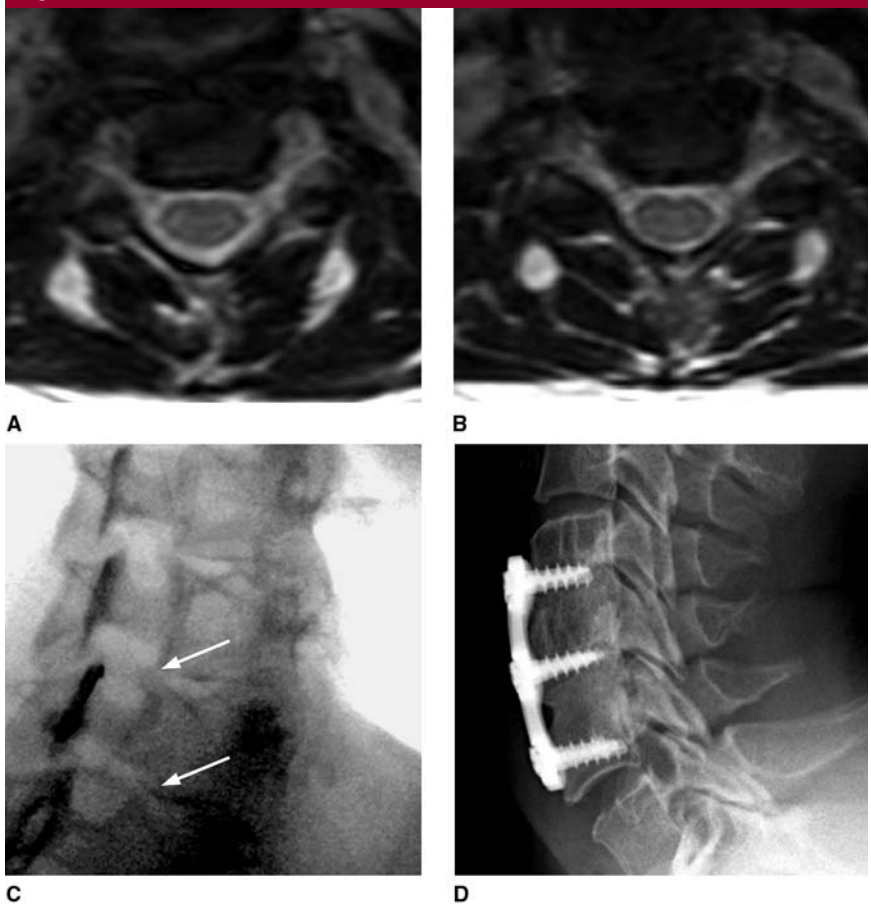

Patient with severe right arm pain in a C6 distribution who had a relatively unimpressive magnetic resonance imaging scan through C4-5 **(A)** and C5-6 **(B)**. **C,** Oblique fluoroscopic image taken at the time of selective nerve root injection demonstrating uncovertebral osteophytes, causing foraminal narrowing at C4-5 and C5-6 (arrows). **D,** Two-level anterior cervical diskectomy and fusion resolved the patient's symptoms.

Traction

Home cervical traction is of unproven benefit for cervical radiculopathy.[5] Anecdotally, intermittent home traction may help relieve symptoms by temporarily enlarging the neuroforaminal space and probably does not cause harm. Traction should be avoided in the patient with myelopathy to prevent stretching of a compromised spinal cord over a compressive lesion.

Medication

Although equivalent evidence is not available for cervical radiculop-

athy, meta-analysis suggests evidence to support the efficacy of nonsteroidal anti-inflammatory drugs (NSAIDs) for acute low back pain.[6] The patient on long-term NSAID therapy should be monitored for potential liver, kidney, and gastrointestinal toxicity. Selective cyclooxygenase-2 (COX-2) inhibitors may diminish the incidence of gastrointestinal side effects, but in controlled trials of osteoarthritis, they do not appear to be any more efficacious than nonselective NSAIDs.[7]

Narcotic analgesics may be necessary for symptom relief in the early, severe stages of cervical radiculopathy. Because of their addictive potential, however, narcotics are not ideal for the long-term treatment of most patients. In general, narcotics should be used as breakthrough supplements to NSAIDs or in patients who cannot tolerate NSAIDs. The patient should be weaned off the narcotic as soon as possible. Muscle relaxants also may provide symptomatic relief as a means of decreasing narcotic requirements.

Antidepressants and anticonvulsants are used to manage chronic neuropathic pain syndromes. Amitriptyline demonstrated a modest analgesic benefit in a placebo-controlled trial of low back pain and lumbar radiculopathy.[8] Gabapentin has been used to manage epidural fibrosis in failed back surgery syndrome.[9] To our knowledge, however, no such studies exist for the treatment of cervical radiculopathy.

Oral corticosteroids are commonly prescribed because anecdotal evidence suggests that they are effective in diminishing acute radicular pain. However, their long-term benefit in favorably altering the natural history of cervical radiculopathy has not been demonstrated. Because rare but significant complications (eg, infection, hyperglycemia, osteonecrosis) can occur, patients should be carefully counseled as to the risks and benefits of oral corticosteroids. Methylprednisolone is often prescribed as a prepackaged dose pack that tapers from 24 to 0 mg over 7 days.

Physical Therapy

Physical therapy has not been demonstrated to alter the natural history of cervical radiculopathy.[10] A graduated program of physical therapy is commonly prescribed after an initial period of short-term rest and/or immobilization. Massage and modalities such as heat, ice, electrical stimulation, and ultrasound have not been proved to be beneficial in the long term.[11] Postural education, ergonomics, and lifestyle modifications also may be beneficial. As the acute pain resolves, isometric exercises are instituted to strengthen the cervical musculature. Aerobic conditioning may be helpful in relieving symptoms. Stationary bicycling, walking, use of stair climbing machines, and other nonimpact aerobic exercises are preferred to avoid jarring the cervical spine. Active range of motion and resistive exercises may be added as tolerated.

Cervical Manipulation

The efficacy of cervical manipulation for radiculopathy has not been established. For neck pain and cervicogenic headaches, manipulation probably provides short-term benefits, with a complication rate between 5 and 10 per 10 million manipulations.[12] Reported complications of cervical manipulation include radiculopathy, myelopathy, spinal cord injury, and vertebral artery injury.[13] The actual incidence of these complications is unknown but is probably low. Nevertheless, in the absence of objective evidence demonstrating any proven benefit, and given the known (albeit low probability) risks, cervical manipulation is not routinely recommended for the patient with cervical radiculopathy and should be avoided in the patient with known myelopathy.

Cervical Steroid Injection

Spinal steroid injection is commonly used in the nonsurgical management of radiculopathy, both in the lumbar and cervical spine. Purported mechanisms of action include: (1) an anti-inflammatory effect, with inhibition of prostaglandin synthesis; (2) interruption of nociceptive input from somatic nerves; (3) a direct neural membrane–stabilizing effect; (4) blockade of pain-mediating neuropeptide synthesis; (5) sympathetic blockade; (6) the mechanical effect of the injectate breaking up epidural adhesions; and (7) blockade of C-fiber activity in the dorsal root ganglion. The clinical use of cervical epidural and nerve root injections is based largely on these theoretical and other anecdotal considerations; well designed, placebo-controlled studies are lacking.[14]

Selective nerve root blocks are variants of epidural steroid injections. Instead of coating the epidural space with steroids, however, the perineural space surrounding selected root(s) is injected. Proposed advantages over epidural injection include: (1) specific targeting of problematic root(s) and the dorsal root ganglion, resulting in a greater local concentration of steroid at the desired location; (2) diagnostic information obtained by blocking the pain associated with a symptomatic root, which may be used in surgical planning or prognostication;[15] (3) avoidance of the spinal canal and, thus, of potential complications associated with entry into the epidural space; (4) a smaller volume of injectate versus the interlaminar epidural approach; and (5) targeting the area anterior to the nerve root, where most compressive cervical lesions arise. In a prospective study, Vallee et al[16] found 50% good to excellent results at 12 months with selective nerve root blocks, but this study of 32 patients did not demonstrate improvement over the natural history. Complications of cervical injections include dural puncture, meningitis, epidural

abscess, intraocular hemorrhage, adrenocortical suppression, epidural hematoma, and root or spinal cord injury.[17-19] Fortunately, these complications are rare.

Surgical Treatment

Commonly accepted indications for surgery include severe or progressive neurologic deficit (weakness or numbness) or significant pain that fails to respond to nonsurgical treatment. Depending on the pathology, cervical radiculopathy may be surgically addressed either anteriorly or posteriorly (Table 2).

Table 2

Common Surgical Approaches for Cervical Radiculopathy

	Advantages	Disadvantages
Anterior cervical diskectomy and fusion	Direct removal of anterior pathology without neural retraction Bone graft restores height and provides indirect foraminal decompression Fusion prevents recurrent neural compression Muscle-sparing approach	Fusion-related issues Autograft harvest morbidity Nonunion Plate complications May accelerate adjacent segment degeneration
Posterior laminoforaminotomy	Avoids fusion Can be done with minimally invasive techniques	Symptoms may recur at the surgical segment Removal of anterior pathology would require neural retraction

Anterior Decompression and Fusion

Anterior cervical diskectomy and fusion (ACDF) allows direct removal of most lesions that cause cervical radiculopathy (eg, herniated disk, uncovertebral spur) without neural retraction. Another advantage of ACDF is that placement of an anterior bone graft in the disk space opens up the neuroforamen, thereby providing indirect decompression of the nerve root. The associated fusion also may help to improve any component of neck pain arising from disk degeneration and spondylosis. Other advantages of the anterior approach include extremely low rates of infection and wound complications. Anterior cervical incisions also tend to be cosmetically preferable: especially when placed in the creases of the neck, the incision heals with a virtually imperceptible scar. The anterior approach requires little muscle dissection and thus is generally associated with little perioperative pain.

The major disadvantage of the anterior approach is the potential for pseudarthrosis and other graft-related complications. Several factors affect the pseudarthrosis rate, including patient variables (eg, smoking), graft type (eg, autograft versus allograft), number of levels operated on, and plating. Unfortunately, the current literature is extremely difficult to interpret because of these conflicting factors, making it impossible to compare studies. However, to avoid donor site morbidity and given the acceptable results with allograft, plated ACDF with allograft is a popular option for one- and two-level cervical radiculopathy. Fusion rates with three-level ACDF have historically been considered suboptimal, but it is unclear whether that holds true in the modern era of plated anterior cervical surgery.[20] With involvement of more than two levels, some authors have reported poor fusion rates even with plated autograft and instead recommend a corpectomy construct.[21] Others, however, have had excellent fusion rates with multilevel ACDF with allograft and plates.[22] Although no uniform recommendations can be made, plating is popular when performing more than a single-level ACDF and when allograft is used at one or more levels.

Other disadvantages of the anterior approach are persistent speech and swallowing complications[23] associated with anterior exposure and retraction of the esophagus and laryngeal nerves. Although the incidence of these complications is unknown, estimates range from 2% to 5%.[23]

Anterior decompression may be performed without fusion. Anterior cervical diskectomy without fusion was historically popular but has recently fallen out of favor because of the potential for local kyphosis and worsening neck pain.[24] Another option is anterior microforaminal decompression via an approach medial to the vertebral artery, with preservation of most of the disk space.[25] A high rate of failure has been reported by other authors using this approach, however.[26]

Cervical Disk Replacement

Disk replacement is an emerging technology that may be available in the near future for the surgical management of cervical radiculopathy (Figure 5). Several cervical disk replacements have completed or are currently in US Food and Drug Administration–sponsored clinical trials. The surgical approach and method of neural decompression are essentially identical to that of ACDF, but an artificial disk is placed into the decompressed disk space, rather than bone supplemented with plates and screws. Proposed advantages over fusion include maintenance of motion, avoidance of nonunion, and avoidance of plate-and-screw complications, such as backout, esophageal erosion, and periplate ossification.[27] The primary long-term benefit, how-

Figure 5

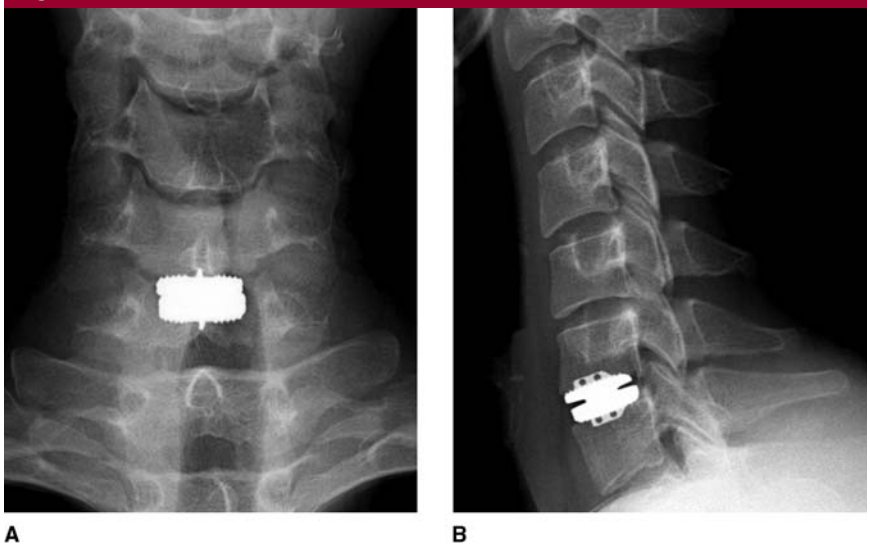

Anteroposterior **(A)** and lateral **(B)** radiographs of a patient after cervical disk replacement for soft disk herniation.

ever, may be the as-yet-unproved potential to reduce the incidence of adjacent segment degeneration. It is argued that cervical fusion at one or more levels leads to accelerated rates of degeneration at adjacent segments by placing greater stress on those segments. These concerns are bolstered by biomechanical data demonstrating increased disk pressure and mobility at disks adjacent to fusion.[28] However, clinical series to date have failed to prove that accelerated adjacent segment degeneration is a consequence of fusion rather than a manifestation of natural history in the patient who, by virtue of developing symptomatic degeneration at one level, has already demonstrated a propensity toward spondylosis at other levels. In fact, the currently available evidence, most of which is nonrandomized and retrospective, suggests that symptomatic adjacent segment disease occurs at a rate of approximately 3% per year, regardless whether the index operation for radiculopathy was anterior diskectomy with fusion,[29] anterior diskectomy without fusion,[30] or posterior foraminotomy[31] without fusion. Once available, long-term rates of adjacent segment degeneration derived from current randomized trials comparing cervical disk replacement with anterior cervical fusion should help settle this issue.

The preliminary results of cervical disk replacement using a variety of prostheses have been favorable,[32] which likely reflects the fact that neural decompression is the cornerstone of early clinical improvement. Mechanical failure of devices over time is a distinct possibility, as it has been in every other form of joint arthroplasty. Furthermore, because motion is retained, the potential exists for recurrent radiculopathy to develop with cervical arthroplasty due to formation or reformation of spondylotic bone spurs. A wider decompression (perhaps to include nonsymptomatic foraminal spurs on the opposite side) may be necessary with arthroplasty than with fusion, as the retained motion and lack of bone remodeling with arthroplasty may lead to growth rather than regression of osteophytes.

Posterior Decompression

In the patient with anterolateral disk herniation or foraminal stenosis, posterior laminoforaminotomy can be used to decompress the nerve root without significantly destabilizing the spine (Figure 6). When considering this approach, the compressive lesion ideally should be located such that unroofing the foramen will adequately decompress the root. The disk herniation or anterior osteophyte can be removed, but does not necessarily need to be, as long as the compressed span of nerve root is freed up posteriorly. When a disk herniation is to be removed posteriorly, it may be necessary to drill away the superior pedicle of the inferior vertebra to allow safe access to the disk space without necessitating undue neural retraction.

A major advantage of the posterior approach is that it can be performed with minimal patient morbidity. Additionally, it avoids fusion and its attendant complications. However, disadvantages include the possibility for incomplete decompression in the setting of anterior compressive lesions, the inability to restore disk and foraminal height at the diseased level, and the potential for deterioration of results with time if the degenerative process continues in the absence of fusion. Reported outcomes of laminoforaminotomy have enjoyed success rates of up to 91.5%.[31]

There are few, if any, absolute indications for a preference of decompressing the nerve root either anteriorly or posteriorly.[33] For the patient who has had prior surgery from one approach, it may be advantageous to perform surgery from the opposite approach to avoid working through scar tissue. For example, a common salvage procedure for the patient with persistent radiculopathy after ACDF is posterior foraminotomy. However, a revision anterior procedure could be performed and would avoid any morbidity associated with a posterior approach.[34] Anatomic factors other than the presence of scar tissue might provide incentive for the surgeon to select one ap-

proach versus another. Revision anterior surgery is favored when the graft appears poorly incorporated or resorbed, and when anterior plates and screws are backing out or are prominent and need to be removed or repositioned. Posterior surgery may be favored in the absence of significant graft fragmentation or implant prominence. When preoperative MRI or CT scans demonstrate an aberrant vertebral artery that would be in jeopardy with an anterior approach, posterior surgery may be favored if all other factors remain equal.

Outcomes of Surgical Treatment

Success rates are very high for surgical decompression of cervical nerve roots for radiculopathy. Reported outcomes for relief of arm pain, as well as improvements in motor and sensory function are typically in the 80% to 90% range[35] with either anterior or posterior approaches. In the patient in whom nonsurgical treatment has failed, it is clear that surgery can permanently alter the natural history of symptoms arising from the involved motion segment. Any surgeon who has seen a patient suffer for months, only to wake up in the recovery room with immediate postoperative relief of arm pain, never to return again, can attest to that fact. Rather, the unresolved issue remains in how to determine when and for whom surgery should be recommended, given that not every patient has an excellent result from surgery, that surgery has the potential for complications, and that the natural history of cervical radiculopathy tends to be favorable in most patients. The available literature is not sufficient to resolve this question. Most comparative studies of surgical versus nonsurgical management suffer from lack of randomization and selection bias. In some studies, patients with more severe symptoms are treated surgically.[36,37] Other studies lack appropriate control groups.[38]

Figure 6

A B

A, Oblique radiograph demonstrating multilevel foraminal stenosis at C3-6 in a woman with unilateral right-sided neck and shoulder girdle pain. **B,** Axial magnetic resonance image of C3-4 in the same patient. Multilevel posterior laminoforaminotomy was performed, with complete resolution of radiculopathy.

Summary

It is impossible at the onset of symptoms to predict whether a given patient will not respond well to nonsurgical treatment or whether the patient has an unfavorable natural history. Thus, in the absence of severe or progressive neurologic deficit, nonsurgical treatment should be attempted for most patients with cervical radiculopathy. Although many forms of nonsurgical management are thought to provide at least some short-term pain reduction, none of the commonly used nonsurgical therapies has been proved to alter the natural history of the disorder in a controlled, prospective manner. For the patient with progressive neurologic dysfunction or the patient who does not show improvement despite time and nonsurgical treatment, surgical management provides excellent and predictable outcomes. Either anterior or posterior approaches can be selected in the appropriate circumstances, understanding that neither is perfect and that each carries its own set of advantages and disadvantages.

References

Evidence-based Medicine: There are several level I and II prospective, randomized or controlled studies referenced (7, 8, 33, and 36); the remaining references are level III/IV case presentations, case-control cohort studies, or expert opinion (references 2, 10, 13, and 20).

Citation numbers printed in **bold type** indicate references published within the past 5 years.

1. Boden SD, McCowin PR, Davis DO, Dina TS, Mark AS, Wiesel S: Abnormal magnetic-resonance scans of the cervi-

cal spine in asymptomatic subjects: A prospective investigation. *J Bone Joint Surg Am* 1990;72:1178-1184.
2. Rhee JM, Riew KD: Evaluation and management of neck pain, radiculopathy, and myelopathy. *Seminars in Spine Surgery* 2005;17:174-185.
3. Lees F, Turner JW: Natural history and prognosis of cervical spondylosis. *Br Med J* 1963;2:1607-1610.
4. Naylor JR, Mulley GP: Surgical collars: A survey of their prescription and use. *Br J Rheumatol* 1991;30:282-284.
5. Swezey RL, Swezey AM, Warner K: Efficacy of home cervical traction therapy. *Am J Phys Med Rehabil* 1999; 78:30-32.
6. Deyo RA: Drug therapy for back pain: Which drugs help which patients? *Spine* 1996;21:2840-2849.
7. Bensen WG, Fiechtner JJ, McMillen JI, et al: Treatment of osteoarthritis with celecoxib, a cyclooxygenase-2 inhibitor: A randomized controlled trial. *Mayo Clin Proc* 1999;74:1095-1105.
8. Atkinson JH, Slater MA, Williams RA, et al: A placebo-controlled randomized clinical trial of nortriptyline for chronic low back pain. *Pain* 1998; 76:287-296.
9. Braverman DL, Slipman CW, Lenrow DA: Using gabapentin to treat failed back surgery syndrome caused by epidural fibrosis: A report of 2 cases. *Arch Phys Med Rehabil* 2001;82:691-693.
10. Levine MJ, Albert TJ, Smith MD: Cervical radiculopathy: Diagnosis and nonoperative management. *J Am Acad Orthop Surg* 1996;4:305-316.
11. Santiesteban AJ: The role of physical agents in the treatment of spine pain. *Clin Orthop Relat Res* 1983;179:24-30.
12. Hurwitz EL, Aker PD, Adams AH, Meeker WC, Shekelle PG: Manipulation and mobilization of the cervical spine: A systematic review of the literature. *Spine* 1996;21:1746-1759.
13. Malone DG, Baldwin NG, Tomecek FJ, et al: Complications of cervical spine manipulation therapy: 5-year retrospective study in a single-group practice. *Neurosurg Focus* 2002;13:ecp1.
14. Stav A, Ovadia L, Sternberg A, Kaadan M, Weksler N: Cervical epidural steroid injection for cervicobrachialgia. *Acta Anaesthesiol Scand* 1993;37: 562-566.
15. Sasso RC, Macadaeg K, Nordmann D, Smith M: Selective nerve root injections can predict surgical outcome for lumbar and cervical radiculopathy: Comparison to magnetic resonance imaging. *J Spinal Disord Tech* 2005; 18:471-478.
16. Vallee JN, Feydy A, Carlier RY, Mutschler C, Mompoint D, Vallee CA: Chronic cervical radiculopathy: Lateral-approach periradicular corticosteroid injection. *Radiology* 2001; 218:886-892.
17. Hodges SD, Castleberg RL, Miller T, Ward R, Thornburg C: Cervical epidural steroid injection with intrinsic spinal cord damage: Two case reports. *Spine* 1998;23:2137-2142.
18. Huston CW, Slipman CW, Garvin C: Complications and side effects of cervical and lumbosacral selective nerve root injections. *Arch Phys Med Rehabil* 2005;86:277-283.
19. Rosenkranz M, Grzyska U, Niesen W, et al: Anterior spinal artery syndrome following periradicular cervical nerve root therapy. *J Neurol* 2004;251:229-231.
20. Rhee JM, Park JB, Yang JY, Riew DK: Indications and techniques for anterior cervical plating. *Neurol India* 2005;53:433-439.
21. Hilibrand AS, Fye MA, Emery SE, Palumbo MA, Bohlman HH: Increased rate of arthrodesis with strut grafting after multilevel anterior cervical decompression. *Spine* 2002;27: 146-151.
22. Samartzis D, Shen FH, Matthews DK, Yoon ST, Goldberg EJ, An HS: Comparison of allograft to autograft in multilevel anterior cervical discectomy and fusion with rigid plate fixation. *Spine J* 2003;3:451-459.
23. Winslow CP, Winslow TJ, Wax MK: Dysphonia and dysphagia following the anterior approach to the cervical spine. *Arch Otolaryngol Head Neck Surg* 2001;127:51-55.
24. Watters WC III, Levinthal R: Anterior cervical discectomy with and without fusion: Results, complications, and long-term follow-up. *Spine* 1994;19: 2343-2347.
25. Jho HD, Kim WK, Kim MH: Anterior microforaminotomy for treatment of cervical radiculopathy: I. Disc-preserving "functional cervical disc surgery". *Neurosurgery* 2002;51(5 suppl):S46-S53.
26. Hacker RJ, Miller CG: Failed anterior cervical foraminotomy. *J Neurosurg* 2003;98(2 suppl):126-130.
27. Park JB, Cho YS, Riew KD: Development of adjacent-level ossification in patients with an anterior cervical plate. *J Bone Joint Surg Am* 2005;87: 558-563.
28. Eck JC, Humphreys SC, Lim TH, et al: Biomechanical study on the effect of cervical spine fusion on adjacent-level intradiscal pressure and segmental motion. *Spine* 2002;27:2431-2434.
29. Hilibrand AS, Carlson GD, Palumbo MA, Jones PK, Bohlman HH: Radiculopathy and myelopathy at segments adjacent to the site of a previous anterior cervical arthrodesis. *J Bone Joint Surg Am* 1999;81:519-528.
30. Lunsford LD, Bissonette DJ, Jannetta PJ, Sheptak PE, Zorub DS: Anterior surgery for cervical disc disease: I. Treatment of lateral cervical disc herniation in 253 cases. *J Neurosurg* 1980;53:1-11.
31. Henderson CM, Hennessy RG, Shuey HM Jr, Shackelford EG: Posterior-lateral foraminotomy as an exclusive operative technique for cervical radiculopathy: A review of 846 consecutively operated cases. *Neurosurgery* 1983;13:504-512.
32. Wigfield CC, Gill SS, Nelson RJ, Metcalf NH, Robertson JT: The new Frenchay artificial cervical joint: Results from a two-year pilot study. *Spine* 2002;27:2446-2452.
33. Herkowitz HN, Kurz LT, Overholt DP: Surgical management of cervical soft disc herniation: A comparison between the anterior and posterior approach. *Spine* 1990;15:1026-1030.
34. Zdeblick TA, Hughes SS, Riew KD, Bohlman HH: Failed anterior cervical discectomy and arthrodesis: Analysis and treatment of thirty-five patients. *J Bone Joint Surg Am* 1997;79:523-532.
35. Bohlman HH, Emery SE, Goodfellow DB, Jones PK: Robinson anterior cervical discectomy and arthrodesis for cervical radiculopathy: Long-term follow-up of one hundred and twenty-two patients. *J Bone Joint Surg Am* 1993;75:1298-1307.
36. Sampath P, Bendebba M, Davis JD, Ducker T: Outcome in patients with cervical radiculopathy: Prospective, multicenter study with independent clinical review. *Spine* 1999;24:591-597.
37. Heckmann JG, Lang CJ, Zobelein I, Laumer R, Druschky A, Neundorfer B: Herniated cervical intervertebral discs with radiculopathy: An outcome study of conservatively or surgically treated patients. *J Spinal Disord* 1999;12:396-401.
38. Saal JS, Saal JA, Yurth EF: Nonoperative management of herniated cervical intervertebral disc with radiculopathy. *Spine* 1996;21:1877-1883.