Review Article

Hemiarthroplasty for Three- and Four-part Proximal Humerus Fractures

Edwin R. Cadet, MD

Christopher S. Ahmad, MD

Abstract

Displaced three- and four-part proximal humerus fractures are among the most challenging shoulder conditions to manage. Because of the risk of symptomatic malunion, nonunion, and humeral head osteonecrosis, surgical management is preferred. Locking plate technology has provided an alternative to hemiarthroplasty for certain three- and four-part fracture patterns, even in the setting of osteopenic bone. Prosthetic humeral head replacement has been advocated for head-splitting fractures and fracture-dislocations as well as four-part fractures with significant initial varus displacement (>20°). Technical challenges, including obtaining proper humeral head height, retroversion, and optimal positioning and fixation of the tuberosities, have a substantial effect on patient outcomes.

From Columbia Orthopaedics, Columbia University Medical Center, New York, NY.

Dr. Cadet or an immediate family member has received research or institutional support from Smith & Nephew. Dr. Ahmad or an immediate family member serves as a paid consultant to Acumed and Arthrex and has received research or institutional support from Arthrex, Major League Baseball, and Stryker.

J Am Acad Orthop Surg 2012;20: 17-27

Proximal humerus fractures account for approximately 4% to 5% of all fractures.[1,2] Three- and four-part proximal humerus fractures and fracture-dislocations are among the most severe and account for only 5% of all proximal humerus fractures.[3]

Fracture patterns vary based on the mechanism of injury and bone density at the time of injury. In older patients (aged >60 years), three- and four-part proximal humerus fractures are usually the result of low-energy trauma.[4] These fractures are often considered fragility fractures, and they serve as a clinical indication of existing osteopenia or osteoporosis. When warranted, the patient should be evaluated and treated for osteoporosis as part of fracture management. In younger patients, proximal humerus fractures can be the result of high-energy trauma. Greater consideration is given to humeral head preservation with fracture osteosynthesis in this patient population.

Anatomy

The proximal humerus can be divided into four anatomic areas: humeral head, greater tuberosity, lesser tuberosity, and surgical neck.[5,6] The average humeral neck-shaft angle measures approximately 140°.[7] Humeral head version is quite variable depending on which anatomic landmarks are used.[8,9] Historically, 30° of humeral head retroversion has been considered normal. In a study of 120 cadaveric humeri, Hernigou et al[9] used CT to measure humeral retroversion and reported that the average humeral head retroversion was 28.8° with reference to the forearm axis. However, Boileau et al[8] determined that average retroversion was 17.9° with respect to the transepicondylar axis and 21.5° with respect to the

trochlear tangent axis in 65 cadaveric humeri. They also noted an 8.9° difference between humeral head retroversion of the right and left humeri.

The supraspinatus, infraspinatus, and teres minor muscles insert on the greater tuberosity; the subscapularis muscle inserts on the lesser tuberosity. In the setting of proximal humerus fracture, the direction of tuberosity displacement is affected by the tendons attached to the individual fragments. Greater tuberosity fracture fragments migrate superiorly and posteriorly, following the vector of the superior and posterior rotator cuff. The lesser tuberosity translates anteriorly and medially along the vector of the subscapularis. The superior and posterior rotator cuff is responsible for varus malalignment of the proximal humerus in the setting of displaced fractures.

The long head of the biceps travels within the intertubercular groove of the anterior humeral shaft, extends toward the rotator interval, and inserts onto the supraglenoid tubercle and superior labrum.[10] The tendon is an extrasynovial structure in the glenohumeral joint and serves as a critical landmark in tuberosity reconstruction in patients with three- and four-part proximal humerus fractures. The long head of the biceps may be incarcerated within the fracture fragments and may impede fracture reduction. The bicipital groove is another reliable anatomic landmark that can be used to determine humeral head retroversion.[8]

The pectoralis major tendon can also create a deforming force in the setting of proximal humerus fractures. The pull of the tendon acts to adduct and translate the humeral shaft anteriorly. The superior margin of the pectoralis major tendon inserts approximately 5.6 cm distal to the top of the humeral head[11] or 4.2 cm distal to the superomedial corner of the greater tuberosity.[12] These anatomic landmarks are useful in estimating humeral height for hemiarthroplasty of proximal humerus fractures.

Vascularity of the proximal humerus is an important factor in assessing fracture pattern severity; thus, a thorough knowledge of the vascular anatomy is important. Historically, the anterior circumflex humeral artery and its terminal branch, the arcuate artery, have been noted as the preeminent source of perfusion to the proximal humerus.[13] In a cadaver study, Brooks et al[14] investigated the vascularity of the humeral head using a four-part fracture model. The authors noted that the primary source of perfusion to the proximal humerus was via the anterior circumflex humeral and arcuate arteries, with significant intraosseous anastamoses existing between the arcuate artery and the posterior circumflex humeral artery, metaphyseal arteries, and the vessels of the greater and lesser tuberosities. The authors also reported that, in most cases, four-part proximal humerus fracture disrupted perfusion to the humeral head. They also noted that the posteromedial vessels play a vital role in maintaining proximal humerus perfusion in certain fracture patterns.

However, debate continues regarding whether the anterior circumflex humeral artery is the dominant source of perfusion to the humeral head. Recent studies have demonstrated that the posterior circumflex humeral artery plays a greater role than does the anterior circumflex artery in supplying blood to the proximal humerus.[15,16] Duparc et al[15] argued that the posterior and anterior circumflex humeral arteries are equally important in humeral head perfusion. Interestingly, the authors noted that the posterior circumflex humeral artery was consistently larger in diameter than the anterior circumflex humeral artery. In a cadaver study, Hettrich et al[16] quantitatively assessed the vascularity of the proximal humerus and found that the posterior circumflex humeral artery contributes 64% of the blood supplied to the proximal humerus, whereas the anterior circumflex humeral artery contributes just 36%.

Preservation of proximal humerus vascularity is important when distinguishing between valgus impacted and varus angulated three- and four-part proximal humerus fractures. The valgus impacted fracture is characterized by intact medial soft tissues, which can potentially preserve the blood supply to the humeral head.[17] Acceptable results have been achieved with reduction and percutaneous pinning or plate osteosynthesis in patients with these fractures.[4,17-21] In the markedly displaced four-part proximal humerus fracture with significant varus malalignment, disruption of the medial soft-tissue envelope can potentially compromise perfusion to the humeral head.

Classification

In 1934, Codman[6] classified proximal humerus fractures based on the anatomic location of the fracture. He divided the proximal humerus into four parts (ie, head, greater tuberosity, lesser tuberosity, surgical neck) based on epiphyseal lines[5,6] (Figure 1). Neer[5] expanded this classification scheme to include fracture displacement and angulation to define the severity of the fracture pattern (Figure 2). He defined a fracture part as a fragment displaced >1 cm or angulation >45°. The probability of humeral head necrosis increases with the severity of the fracture. The AO classification, which is less frequently used than the Neer and Codman classification systems, emphasizes determination of whether

Figure 1

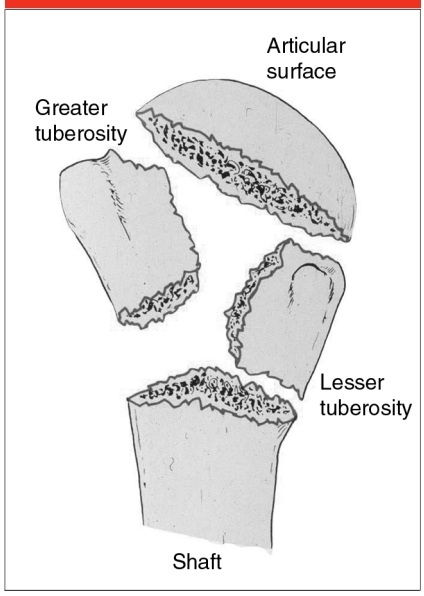

Codman classification of proximal humerus fracture. (Reproduced with permission from Green A, Norris TR: Part II: Proximal humeral fractures and fracture dislocations, in Browner BD, Jupiter JB, Levine AM, Trafton PG, eds: *Skeletal Trauma: Basic Science, Management, and Reconstruction,* ed 3. Philadelphia, PA, Saunders, 2002, p 1514.)

Figure 2

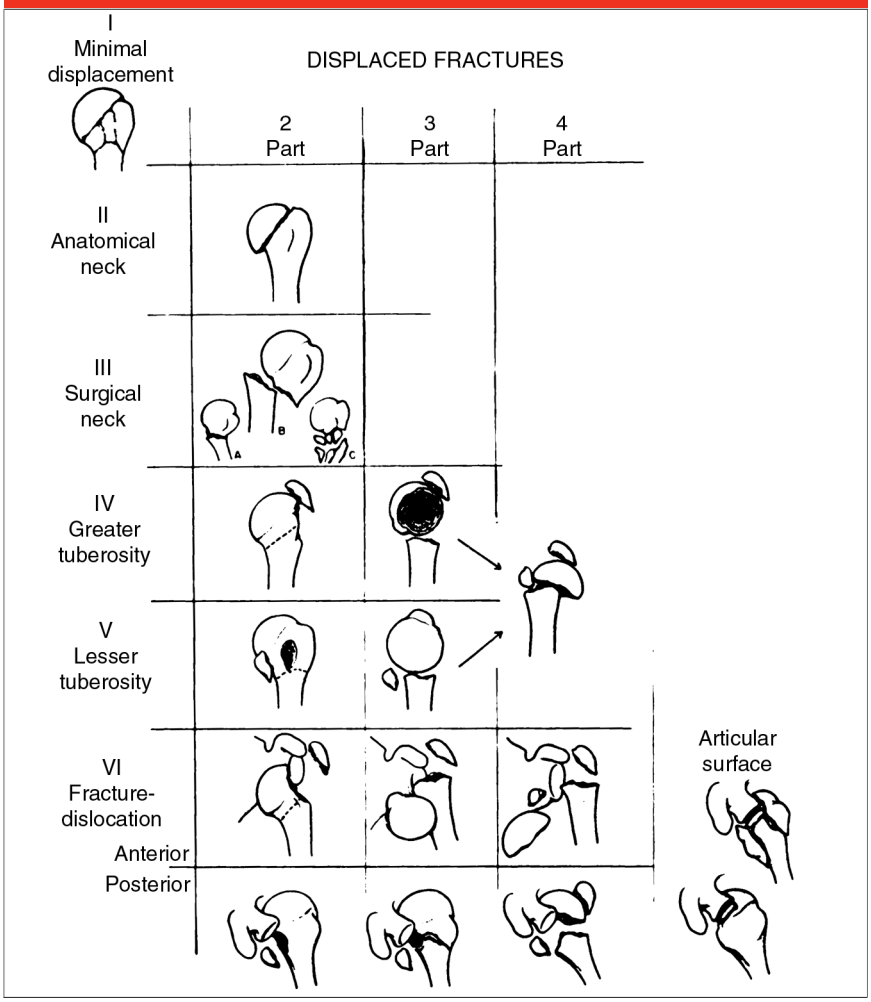

The Neer classification of proximal humerus fractures is based on fragment displacement and angulation. (Reproduced with permission from Neer CS II: Displaced proximal humeral fractures: I. Classification and evaluation. *J Bone Joint Surg Am* 1970:52[6]:1079.)

vascularity to the articular fragment is significantly compromised. Type A is an extra-articular unifocal fracture that involves one of the tuberosities with or without a concomitant metaphyseal fracture (Figure 3). Type B is an extra-articular bifocal fracture or fracture-dislocation with tuberosity and metaphyseal involvement. Type C is a fracture or fracture-dislocation of the articular surface; this type is considered the most severe because the vascular supply is thought to be at the greatest risk of injury, thereby making the humeral head susceptible to the development of osteonecrosis.

Fracture classification can be performed using plain radiographs, advanced imaging, or a combination of both. Several studies have assessed the interobserver and intraobserver reliability of plain radiographs and CT in defining proximal humerus fractures using the Neer and AO classification systems[22-25] (Figure 4). Although additional imaging is routinely used to further characterize these fractures, Sjödén et al[26] demonstrated that the addition of CT and three-dimensional imaging did not improve interobserver reproducibility of either the Neer or AO classification system.[26] Bernstein et al[22] found that the interobserver reproducibility of the Neer classification had a mean kappa coefficient of 0.52 with plain radiographs alone and 0.50 with radiographs and CT scans. The authors noted a slight increase in intraobserver reliability when CT was added to plain radiographic interpretation (0.64 versus 0.72); however, no increase in interobserver reproducibility was observed with the addition of CT. In general, we recommend CT when the delineation of fracture parts and patterns are unclear to the surgeon; however, CT is not absolutely required to classify all proximal humerus fractures.

Management Options

Neer[27] reported poor results with nonsurgical management and osteosynthesis of displaced three- and four-part proximal humerus fractures compared with prosthetic humeral head replacement. He reported high rates of symptomatic nonunion, malunion, tuberosity resorption, and osteonecrosis of the humeral head in significantly displaced four-part fractures managed without proximal humeral head replacement. Neer[27] found that patients had better outcomes with humeral head replacement than with open reduction and internal fixation. He concluded that humeral head replacement was the treatment of choice for displaced four-part proximal humerus fractures, thus shaping treatment algorithms that are still used today.

Locked Plating

Locked plating can be used to manage Neer three- and four-part fractures. Successful open reduction and internal fixation of displaced three- and four-part proximal humerus fractures requires medial support via an anatomic reduction of the metaphysis, inferomedial screw placement along the calcar of the proximal humerus, or augmented support of the medial column with a structural endosteal implant[28,29] (Figure 5). Solberg et al[18] compared the mean Constant scores of patients aged ≥55 years with three- or four-part proximal humerus fractures treated with locked plating or hemiarthroplasty. At a mean 36-month follow-up, the authors found significantly higher mean Constant shoulder scores in the locked plate group ($P < 0.001$). Despite the higher complication rate in this group, better outcomes were achieved with locked plating than with hemiarthroplasty, especially in patients with three-part fractures. Of 38 patients in the locked plate group, 6 developed osteonecrosis following surgery, 6 had evidence of screw perforation of the humeral head, 4 had loss of fixation, and 3 developed wound infection. In contrast, 7 of 48 patients in the hemiarthroplasty group had nonunion of the tuberosity fragments, and 3 patients developed wound infection. The authors noted that loss of fixation in the locked plate group was seen only in patients with initial varus malalignment of the humeral

Figure 3

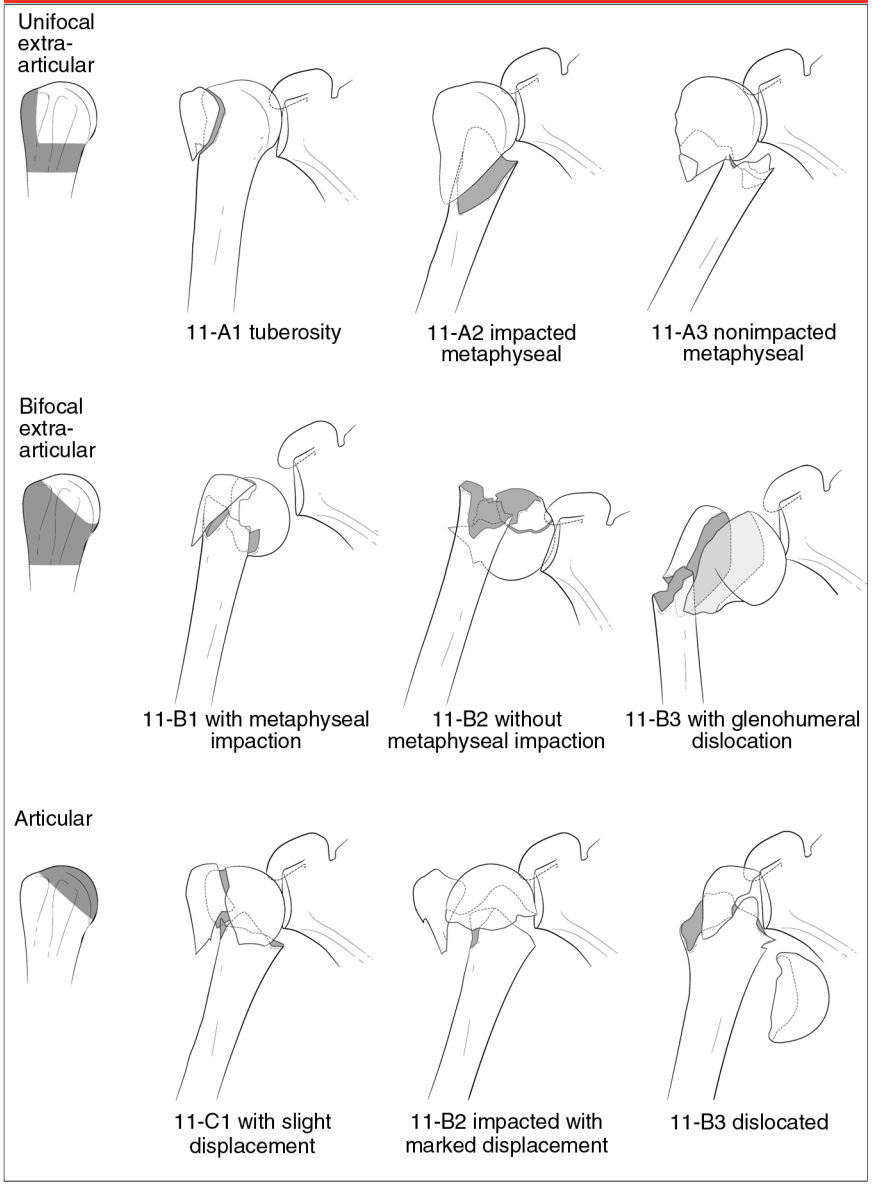

The AO classification of proximal humerus fractures emphasizes the vascularity of the articular fragment. Type A fractures are unifocal and extra-articular, whereas type B fractures are bifocal and extra-articular. Type C fractures are articular and are considered the most severe due to potential disruption of the vascular supply, which can lead to osteonecrosis. (Redrawn with permission from AO Foundation: Müller classification of fractures: Long bones. Available at: www.aofoundation.org/Documents/mueller_ao_class.pdf. Accessed September 12, 2011.)

head of >20°.

In a series of 70 patients aged ≥55 years with Neer three- or four-part fractures treated with locked plating, Solberg et al[4] found that patients with valgus impacted fractures with a metaphyseal segment length >2 mm experienced better clinical outcomes than did patients with fracture patterns with initial varus malalignment. In addition, the authors noted that humeral head angulation had the greatest effect on final clinical outcomes. Metaphyseal segment length <2 mm was predictive of developing osteonecrosis.

Hemiarthroplasty

Besch et al[30] assessed the clinical outcomes of 34 patients with four-part fractures treated with hemiarthroplasty in primary and revision settings. Eighteen patients were treated with primary hemiarthroplasty, and 16 underwent hemiarthroplasty following failed initial osteosynthesis. The authors noted better clinical outcomes and a lower incidence of tuberosity malalignment with associated severe loss of function in patients treated with primary hemiarthroplasty.

We recommend hemiarthroplasty in medically stable patients who are able to protect the shoulder in a sling after surgery to allow healing of the tuberosities. Based on the current literature and our clinical experience, we reserve hemiarthroplasty for patients with proximal humerus fractures with initial varus malalignment >20° in whom anatomic reduction cannot be achieved intraoperatively; patients with moderate or severe osteopenia that can compromise osteosynthesis fixation techniques; patients aged >55 years with Neer three- or four-part fracture-dislocations; and patients with malunion, nonunion, hardware failure, or osteonecrosis of the humeral head following osteosynthesis (Figure 6). Patients with valgus impacted fractures and adequate bone quality are excel-

Figure 4

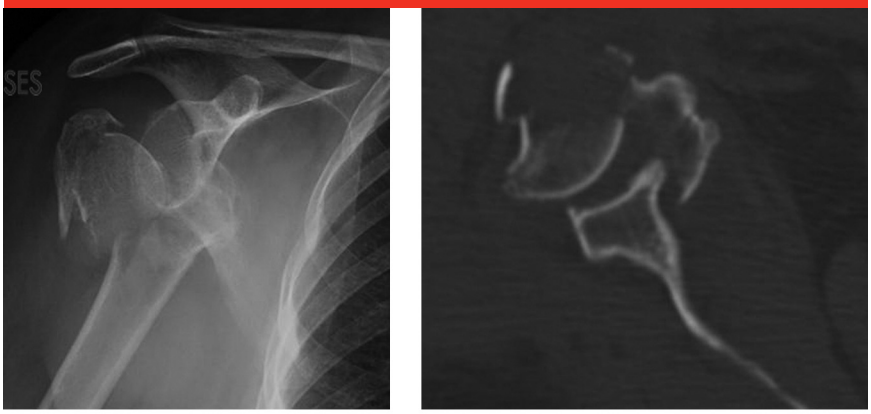

A B

A, AP radiograph demonstrating a four-part fracture of the proximal humerus. **B,** Axial CT scan of a four-part proximal humerus fracture showing a displaced fragment of the lesser tuberosity and a head-splitting fracture of the humeral head. (Courtesy of Columbia University, Center for Shoulder, Elbow and Sports Medicine, New York, NY.)

Figure 5

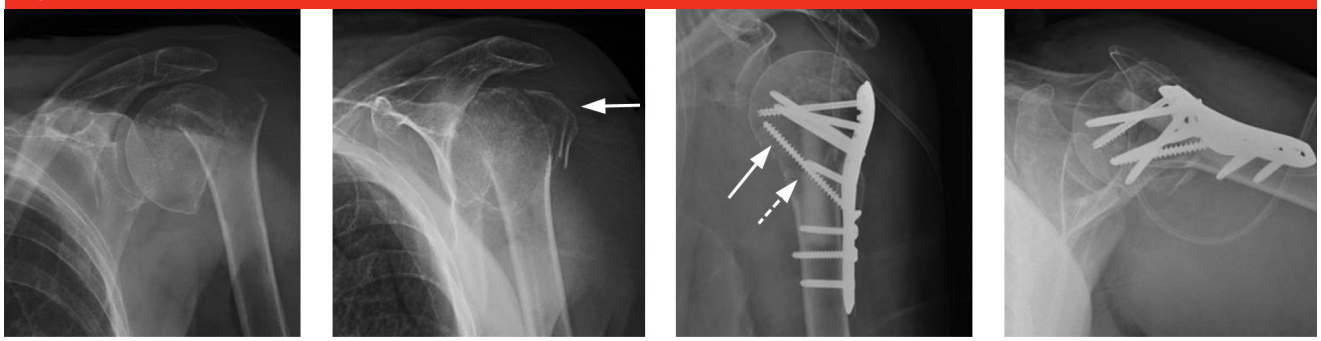

A B C D

A and **B,** Preoperative AP radiographs demonstrating a three-part proximal humerus fracture with significant varus malalignment in an 81-year-old woman. Note the displacement of the greater tuberosity fracture (arrow). Postoperative AP (**C**) and axillary (**D**) radiographs of the proximal humerus following open reduction and internal fixation with a proximal humerus locking plate. Medial calcar support was achieved with anatomic reduction of the medial metaphysis, a medial calcar screw (solid arrow) and a cortical strut graft (dashed arrow). (Courtesy of Columbia University, Center for Shoulder, Elbow and Sports Medicine, New York, NY.)

Figure 6

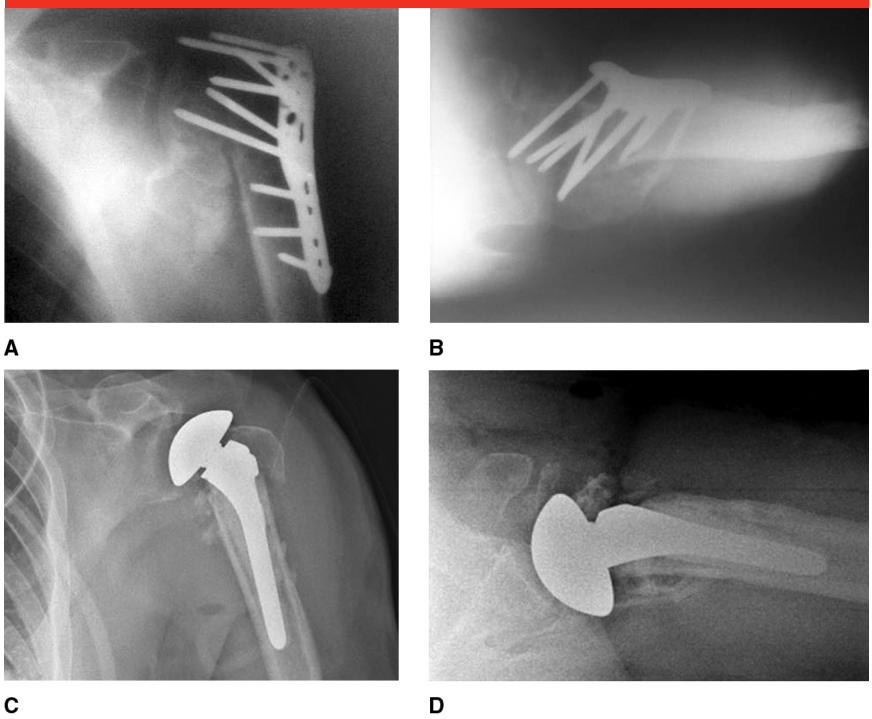

AP (**A**) and axillary (**B**) radiographs demonstrating screw perforation of the humeral head several months after open reduction and internal fixation (ORIF) of a three-part proximal humerus fracture sustained by a 51-year-old pedestrian struck by a motor vehicle. The patient had persistent pain and poor function following ORIF. Postoperative AP (**C**) and axillary (**D**) radiographs following hemiarthroplasty for failed proximal humerus osteosynthesis. (Courtesy of Columbia University, Center for Shoulder, Elbow and Sports Medicine, New York, NY.)

lent candidates for osteosynthesis with locked plating or percutaneous pinning techniques; these techniques are especially recommended for younger patients (aged <55 years). Hemiarthroplasty or reverse total shoulder arthroplasty (RTSA) may be more appropriate in lower demand patients and in older patients (aged >70 years) with poor bone quality and an inability to participate in a supervised physical therapy program.

Critical Components of Successful Hemiarthroplasty

Tuberosity Position and Healing

Successful hemiarthroplasty for three- and four-part proximal fractures requires union and proper positioning of the tuberosity. Recently, experienced surgeons have found that surgical technique and prosthetic design influence tuberosity position and healing, which in turn affects overall patient outcome. Boileau et al[31] assessed clinical and radiologic parameters in a study of 66 patients who underwent hemiarthroplasty for displaced proximal humerus fracture. Initial tuberosity malposition was present in 18 patients (27%), and tuberosity displacement occurred in 15 patients (23%). Tuberosity migration was observed after initial malpositioning and after initial anatomic positioning. Overall, final tuberosity malposition occurred in 33 patients (50%). Factors significantly associated with failure of tuberosity healing were poor initial positioning of the prosthesis (ie, excessive height and/or retroversion), poor positioning of the greater tuberosity, and female sex with advanced age (>75 years). Tuberosity displacement and malposition may help to explain less than exemplary results. With regard to subjective outcomes, 29 patients were very satisfied, 9 were satisfied, and 28 were unsatisfied. Postoperative active elevation averaged only 101° ± 33°, external rotation averaged 18° ± 15°, and internal rotation averaged to the level of L3. The average absolute Constant score was 56 of 100 points (range, 20 to 95 points).

Loebenberg et al[32] demonstrated that active range of motion (ROM) following hemiarthroplasty for four-part humerus fracture is affected by the placement of the greater tuberosity fragment relative to the superior margin of the prosthetic head. The authors concluded that tuberosity placement 10 to 16 mm distal to the superior margin of the prosthetic head resulted in significantly improved active forward elevation and external and internal rotation compared with tuberosities positioned too proximal (3 to 9 mm) or too distal (17 to 28 mm). A recent study found a significant correlation between fatty infiltration of the supraspinatus and infraspinatus muscles and greater tuberosity malposition and between fatty infiltration of the subscapularis and lesser tuberosity malposition.[33] The authors noted that fatty infiltration of the cuff was significantly associated with lower clinical scores, reinforcing the importance of muscular integrity in the setting of rotator cuff function.

The tuberosities should be reapproximated to the prosthesis and the shaft with horizontal sutures around the stem and vertical sutures from

Figure 7

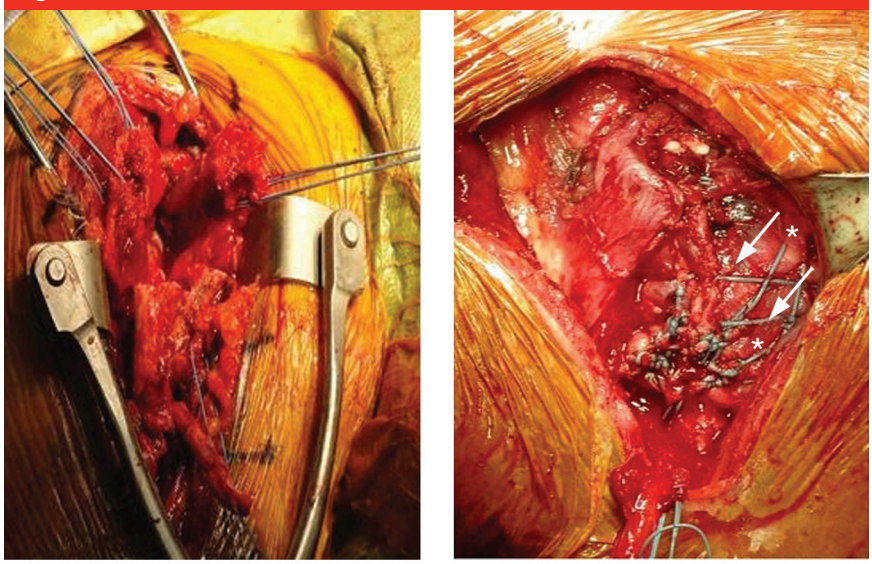

A, Intraoperative photograph demonstrating exposed fracture fragments in a displaced four-part proximal humerus fracture. Traction sutures are placed at the rotator cuff tendon-bone junction to avoid comminution of the bone fragments. **B,** Intraoperative photograph demonstrating suture configuration of tuberosity reconstruction following final tensioning. Horizontal sutures (arrows) compress the greater and lesser tuberosities together. Vertical sutures connect the tuberosities (asterisks) to the proximal humeral shaft. (Courtesy of Columbia University, Center for Shoulder, Elbow and Sports Medicine, New York, NY.)

the shaft. Frankle et al[34] have shown that adding a medial cerclage suture around the prosthesis is critical to decrease interfragmentary strain and motion, thereby maximizing fracture stability. This construct neutralizes the complex forces acting on the tuberosities.

Reduction of the tuberosities should begin by placing horizontal sutures that connect the greater and lesser tuberosities to avoid over-reduction inferiorly. Four suture strands (two each in the posterior and anterior rotator cuff) should be passed through a hole commonly found near the lateral fin of the humeral prosthesis. Use of different colored sutures may facilitate suture management at the time of final tensioning. Sutures originally placed at the greater tuberosity are passed around the the humeral prosthesis and are then passed through the subscapularis tendon-bone junction of the lesser tuberosity. Fluoroscopy can be used to confirm proper tuberosity positioning. Two humeral cortical sutures placed both anterior and posterior to the intertubercular groove before stem insertion are passed through the supraspinatus tendon and subscapularis tendon-bone junction, respectively (Figure 7). Final tensioning of the sutures should occur with the arm slightly flexed and in neutral to slight external rotation.

Wire fixation can be used as an alternative or as a complement to suture fixation and may provide greater fixation strength and compression. A fine balance exists between application of appropriate tension, which facilitates tuberosity healing, and overcompression, which can compromise bone that may already be comminuted and osteopenic. Bone graft from the humeral head is strategically placed at the interface between the tuberosity and the stem and between the humeral shaft and stem before final tensioning of the sutures. Finally, the rotator interval is closed with the arm in neutral to slight external rotation to prevent significant loss of external rotation.

Humeral Height

Determining proper prosthetic height is critical to the success of prosthesis humeral replacement and is challenging due to frequent fracture disruption of the medial metaphyseal calcar. Placing the prosthesis too low or high can cause improper tensioning of the deltoid and supraspinatus. Stem height position is extremely important. Boileau et al[31] reported that humeral lengthening >10 mm caused by a proud prosthesis significantly correlated with tuberosity detachment and proximal migration of the prosthesis under the acromial arch, resulting in limited function. Humeral lengthening created excessive tension on the supraspinatus. Shortening of the humerus was better tolerated clinically. Functional results were not significantly altered until humeral shortening reached or exceeded 15 mm.[31,35]

Intraoperatively, humeral height can be estimated based on the position of the prosthesis in the superior-inferior position where the greater and lesser tuberosity fragments reduce anatomically and under minimal tension at the prosthetic interface. Cement fixation helps maintain proper humeral height. An anatomic approach to determining proper humeral height is performed by placing the top of the prosthetic humeral head approximately 5.6 cm proximal to the superior border of the pectoralis major tendon.[11] When the pecto-

Figure 8

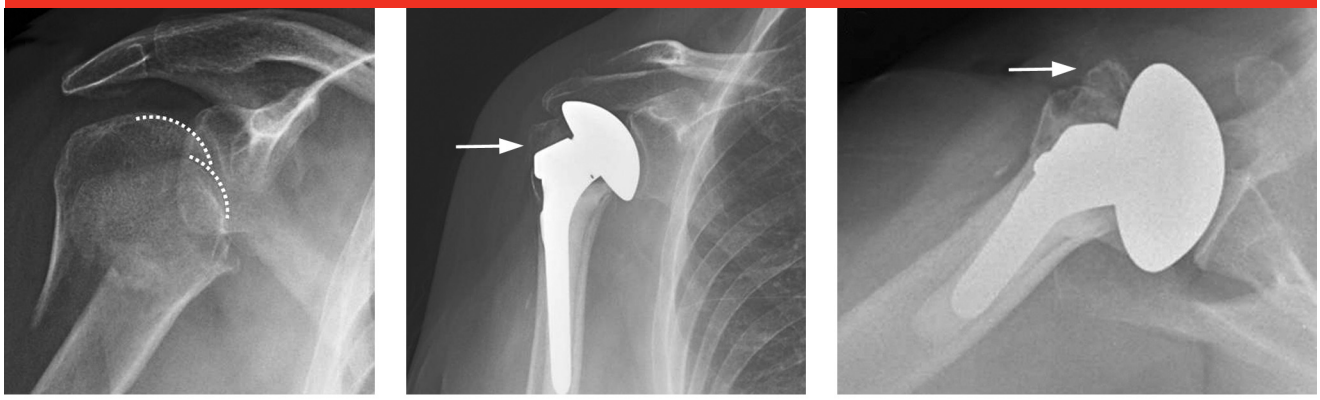

A B C

A, AP radiograph demonstraing head-split proximal humerus fracture in a 70-year-old woman with right-hand dominance. Note the fragmented articular surfaces (dotted arcs). Postoperative AP (**B**) and axial (**C**) radiographs of the proximal humerus 3 months after hemiarthroplasty. Note the healed and properly positioned fragment of the tuberosity (arrow). (Courtesy of Columbia University, Center for Shoulder, Elbow and Sports Medicine, New York, NY.)

ralis major tendon is used as a guide, it is important to tag the superior border of the tendon humeral insertion with an identifiable suture that can be referenced.

Humeral Head Version

Achieving optimal humeral version is another technical challenge associated with hemiarthroplasty; the most common error is placing the component in excessive retroversion. Excessive retroversion can force malpositioning of the greater tuberosity in the horizontal plane, thereby creating excessive tension on the tuberosity repair with the arm in internal rotation. Normal humeral retroversion can range from 15° to 30°.[8,9]

We recommend placing the humeral component between 20° and 30° of retroversion. Improper version may result in anterior or posterior instability.[36] The transepicondylar axis and bicipital groove can serve as consistent anatomic landmarks when determining humeral head retroversion.[9,37] Kummer et al[37] demonstrated that 30° of retroversion can be consistently reproduced by placing the lateral fin of the humeral prosthesis 30° posterior to the posterior margin of the bicipital groove.

Stem Design and Material

Recently, humeral stems have been designed for more accurate tuberosity placement and optimal bone grafting. One design has a window within a low-profile stem for placement of bone graft to enhance tuberosity healing.[38] A coating has also been added to some stems to promote bone healing to the stem. One design has a rough hydroxyapatite-coated surface at the metaphyseal portion of the prosthesis to enhance early bonding with bone. Another design has a microsurface of porous tantalum, which helps to stimulate bone healing and may be conducive to direct bone apposition.[39,40] Studies are needed to determine whether these modifications improve outcomes. Regardless of stem design, surgical technique is the most important factor in a successful outcome.

The so-called unhappy shoulder triad, in which the prosthesis is too proud and too retroverted with a greater tuberosity positioned too low, is the worst outcome associated with hemiarthroplasty.[31] The triad inevitably leads to posterior migration of the greater tuberosity, with a poor functional result. Careful surgical technique and adherence to the aforementioned principles can result in successful outcomes (Figure 8).

Postoperative Rehabilitation

Immediately postoperatively, the affected extremity is placed in a sling in slight external or neutral rotation to relieve stress on the greater tuberosity. In general, rehabilitation begins on the first postoperative day. Pendulum and passive ROM exercises to 90° of forward elevation in the scapular plane and gentle external rotation to neutral are performed with the patient supine. The decision to initiate passive ROM exercise should be individualized to the patient and is dependent on the surgeon's confidence in the strength of tuberosity fixation. With tenuous tuberosity fixation, ROM exercises can be delayed for 2 to 3 weeks to minimize stress on the repair. Gentle active motion of the wrist and elbow is encouraged immediately postoperatively. Active forward elevation and external rotation exercises are delayed until radiographic evidence of

Figure 9

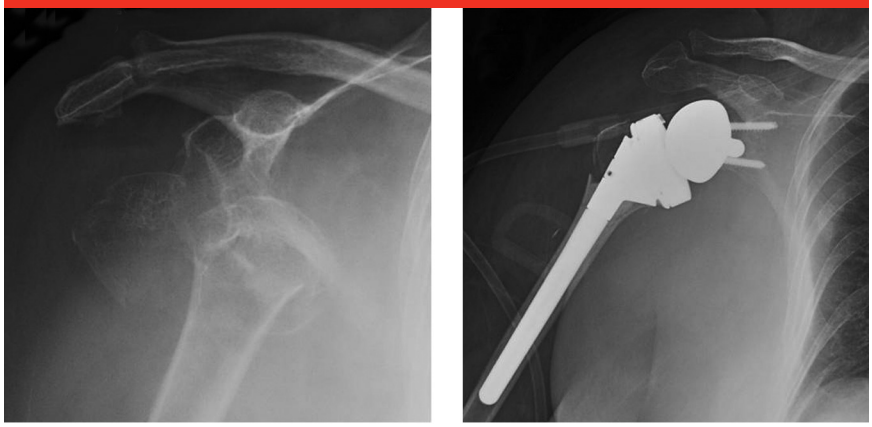

A B

Preoperative (**A**) and postoperative (**B**) AP radiographs of a displaced four-part proximal humerus fracture in an 82-year-old woman who underwent reverse total shoulder arthroplasty. (Courtesy of Columbia University, Center for Shoulder, Elbow and Sports Medicine, New York, NY.)

tuberosity healing is present. Once tuberosity healing is confirmed radiographically, gentle isometric rotator cuff and scapular strengthening can begin, typically at 6 to 8 weeks following surgery. The estimated maximum level of improvement can be achieved 9 to 12 months postoperatively. In addition, medical management of osteopenia should be instituted.

Complications

Tuberosity nonunion is the most common and devastating cause of poor outcomes following hemiarthroplasty for displaced four-part proximal humerus fracture. Bigliani et al[41] identified tuberosity nonunion as the most common cause of failure in a series of 29 failed shoulder hemiarthroplasties performed to manage acutely displaced proximal humerus fractures. In a meta-analysis of 810 hemiarthroplasties, complications included superficial and deep infection (estimated incidence 1.6% and 0.6%, respectively), heterotopic ossification (8.8%), and proximal migration of the humeral head (6.8%).[42]

Outcomes

Hemiarthroplasty serves as a viable option for pain relief in persons with displaced four-part proximal humerus fracture; however, the affected shoulder rarely returns to its baseline level of function, specifically baseline ROM. Kontakis et al[42] reported the outcomes of early management of proximal humerus fractures with hemiarthroplasty in a total of 808 patients (810 hemiarthroplasties). At a mean follow-up of 3.7 years, mean active forward elevation was 105.7°, mean abduction was 92.4°, and external rotation was 30.4°. These results are similar to those of other reports.[42-44] Kontakis et al[42] identified the Constant score for a total of 560 patients in eight studies; the mean Constant score in patients who underwent replacement of a proximal humerus prosthesis was 56.6 out of 100 (range, 11 to 98).

Reverse Total Shoulder Arthroplasty

The potential risk of tuberosity nonunion has given rise to the increasing use of RTSA for management of displaced comminuted four-part fractures (Figure 9). RTSA was introduced to manage rotator cuff arthropathy.[45] In contrast to the benefits of prosthetic humeral head replacement, the main benefits associated with RTSA are nonessential tuberosity union to achieve active forward elevation and the addition of glenoid resurfacing. Resurfacing the glenoid with the glenosphere component can potentially prevent the painful sequelae of glenoid erosion and medialization that can occur with resurfacing the humeral head in isolation.

Bufquin et al[46] prospectively studied a cohort of 43 patients with three- or four-part proximal humerus fractures treated with RTSA. At an average 22-month follow-up, mean active forward elevation and external rotation with the arm in abduction were 97° and 30°, respectively. The mean Constant score was 44. Complications included neurapraxias (5 patients), most of which resolved; reflex sympathetic dystrophy (3 patients); anterior dislocation of the implant (1 patient); displacement of the tuberosities (19 patients); and scapular notching (10 patients). The authors concluded that adequate clinical results could be achieved with RTSA in patients with three- or four part fractures, despite loss of reduction of the tuberosities.

Gallinet et al[47] retrospectively studied a series of 40 patients with complex three- or four-part proximal humerus fractures who underwent either hemiarthroplasty or RTSA. Twenty-one patients underwent hemiarthroplasty with a standard cemented stem, and 19 underwent RTSA using a reverse prosthesis with a cemented stem. Mean follow-up for the hemiarthroplasty and RTSA groups was 16.5 and 12.4 months, respectively. Constant scores, active abduction, and forward elevation were higher in the RTSA group com-

pared with the hemiarthroplasty group (53, 91°, 97.5° and 39, 60°, 53.5°, respectively). However, external rotation was greater in the hemiarthroplasty group (13.5° versus 9°). Thirty-three patients were available for follow-up. In the hemiarthroplasty group, radiographs showed failed tuberosity healing in 3 of 17 patients (18%). In the RTSA group, 15 of 16 patients (94%) demonstrated radiographic evidence of scapular notching; however, no cases of glenosphere loosening were reported.

Summary

Although it is challenging, surgical management is the preferred treatment method of displaced three- and four-part proximal humerus fractures due to concerns regarding the development of symptomatic malunion, nonunion, and osteonecrosis of the humeral head in fracture patterns with significant varus malalignment and displacement. Locking plate technology is a viable option if anatomic reduction or proper medial column support can be achieved. Locked plating has proved to be particularly successful for management of three-and four-part fractures with valgus impacted fracture patterns.

Prosthetic humeral head replacement has been shown to be effective in providing good pain relief; however, the affected extremity will not reach preinjury levels of function. Tuberosity union and positioning as well as the establishment of proper humeral height and retroversion are some of the challenges that must be conquered to achieve successful outcomes following hemiarthroplasty.

RTSA is a viable option in elderly patients who are physically unable to sustain the rigors of prolonged physical therapy and in patients with severe comminution of the tuberosities, preexisting glenohumeral arthritis, or a history of failed osteosynthesis or hemiarthroplasty.

References

References printed in **bold type** are those published within the past 5 years.

1. Stimson BB: *A Manual of Fractures and Dislocations*, ed 2. Philadelphia, PA, Lea & Febiger, 1947.
2. Green A, Norris T: Part II: Proximal humeral fractures and fracture dislocations, in Browner BD, Jupiter JB, Levine AM, Trafton PG, eds: *Skeletal Trauma: Basic Science, Management, and Reconstruction*, ed 2. Philadelphia, PA, Saunders, 2002.
3. Bhandari M, Matthys G, McKee MD, Evidence-Based Orthopaedic Trauma Working Group: Four part fractures of the proximal humerus. *J Orthop Trauma* 2004;18(2):126-127.
4. **Solberg BD, Moon CN, Franco DP, Paiement GD: Locked plating of 3- and 4-part proximal humerus fractures in older patients: The effect of initial fracture pattern on outcome. *J Orthop Trauma* 2009;23(2):113-119.**
5. Neer CS II: Displaced proximal humeral fractures: I. Classification and evaluation. *J Bone Joint Surg Am* 1970; 52(6):1077-1089.
6. Codman E: *The Shoulder: Rupture of the Supraspinatus Tendon and Other Lesions In or About the Subacromial Bursa*. Boston, MA, privately printed, 1934.
7. Takase K, Yamamoto K, Imakiire A, Burkhead WZ Jr: The radiographic study in the relationship of the glenohumeral joint. *J Orthop Res* 2004;22(2):298-305.
8. **Boileau P, Bicknell RT, Mazzoleni N, Walch G, Urien JP: CT scan method accurately assesses humeral head retroversion. *Clin Orthop Relat Res* 2008;466(3):661-669.**
9. Hernigou P, Duparc F, Hernigou A: Determining humeral retroversion with computed tomography. *J Bone Joint Surg Am* 2002;84(10):1753-1762.
10. **Nho SJ, Strauss EJ, Lenart BA, et al: Long head of the biceps tendinopathy: Diagnosis and management. *J Am Acad Orthop Surg* 2010;18(11):645-656.**
11. Murachovsky J, Ikemoto RY, Nascimento LG, Fujiki EN, Milani C, Warner JJ: Pectoralis major tendon reference (PMT): A new method for accurate restoration of humeral length with hemiarthroplasty for fracture. *J Shoulder Elbow Surg* 2006;15(6):675-678.
12. **Carey P, Owens BD: Insertional footprint anatomy of the pectoralis major tendon. *Orthopedics* 2010;33(1): 23.**
13. Gerber C, Schneeberger AG, Vinh TS: The arterial vascularization of the humeral head: An anatomical study. *J Bone Joint Surg Am* 1990;72(10):1486-1494.
14. Brooks CH, Revell WJ, Heatley FW: Vascularity of the humeral head after proximal humeral fractures: An anatomical cadaver study. *J Bone Joint Surg Br* 1993;75(1):132-136.
15. Duparc F, Muller JM, Fréger P: Arterial blood supply of the proximal humeral epiphysis. *Surg Radiol Anat* 2001;23(3): 185-190.
16. **Hettrich CM, Boraiah S, Dyke JP, Neviaser A, Helfet DL, Lorich DG: Quantitative assessment of the vascularity of the proximal part of the humerus. *J Bone Joint Surg Am* 2010; 92(4):943-948.**
17. Jakob RP, Miniaci A, Anson PS, Jaberg H, Osterwalder A, Ganz R: Four-part valgus impacted fractures of the proximal humerus. *J Bone Joint Surg Br* 1991;73(2):295-298.
18. **Solberg BD, Moon CN, Franco DP, Paiement GD: Surgical treatment of three and four-part proximal humeral fractures. *J Bone Joint Surg Am* 2009; 91(7):1689-1697.**
19. Jaberg H, Warner JJ, Jakob RP: Percutaneous stabilization of unstable fractures of the humerus. *J Bone Joint Surg Am* 1992;74(4):508-515.
20. **Südkamp N, Bayer J, Hepp P, et al: Open reduction and internal fixation of proximal humeral fractures with use of the locking proximal humerus plate: Results of a prospective, multicenter, observational study. *J Bone Joint Surg Am* 2009;91(6):1320-1328.**
21. **Brunner F, Sommer C, Bahrs C, et al: Open reduction and internal fixation of proximal humerus fractures using a proximal humeral locked plate: A prospective multicenter analysis. *J Orthop Trauma* 2009;23(3):163-172.**
22. Bernstein J, Adler LM, Blank JE, Dalsey RM, Williams GR, Iannotti JP: Evaluation of the Neer system of classification of proximal humeral fractures with computerized tomographic scans and plain radiographs. *J Bone Joint Surg Am* 1996; 78(9):1371-1375.
23. **Brunner A, Honigmann P, Treumann T, Babst R: The impact of stereo-visualisation of three-dimensional CT**

datasets on the inter- and intraobserver reliability of the AO/OTA and Neer classifications in the assessment of fractures of the proximal humerus. *J Bone Joint Surg Br* 2009;91(6):766-771.

24. Sidor ML, Zuckerman JD, Lyon T, Koval K, Cuomo F, Schoenberg N: The Neer classification system for proximal humeral fractures: An assessment of interobserver reliability and intraobserver reproducibility. *J Bone Joint Surg Am* 1993;75(12):1745-1750.

25. Sjödén GO, Movin T, Güntner P, et al: Poor reproducibility of classification of proximal humeral fractures: Additional CT of minor value. *Acta Orthop Scand* 1997;68(3):239-242.

26. Sjödén GO, Movin T, Aspelin P, Güntner P, Shalabi A: 3D-radiographic analysis does not improve the Neer and AO classifications of proximal humeral fractures. *Acta Orthop Scand* 1999; 70(4):325-328.

27. Neer CS II: Displaced proximal humeral fractures: II. Treatment of three-part and four-part displacement. *J Bone Joint Surg Am* 1970;52(6):1090-1103.

28. Gardner MJ, Boraiah S, Helfet DL, Lorich DG: Indirect medial reduction and strut support of proximal humerus fractures using an endosteal implant. *J Orthop Trauma* 2008;22(3):195-200.

29. Gardner MJ, Weil Y, Barker JU, Kelly BT, Helfet DL, Lorich DG: The importance of medial support in locked plating of proximal humerus fractures. *J Orthop Trauma* 2007;21(3):185-191.

30. Besch L, Daniels-Wredenhagen M, Mueller M, Varoga D, Hilgert RE, Seekamp A: Hemiarthroplasty of the shoulder after four-part fracture of the humeral head: A long-term analysis of 34 cases. *J Trauma* 2009;66(1):211-214.

31. Boileau P, Krishnan SG, Tinsi L, Walch G, Coste JS, Molé D: Tuberosity malposition and migration: Reasons for poor outcomes after hemiarthroplasty for displaced fractures of the proximal humerus. *J Shoulder Elbow Surg* 2002; 11(5):401-412.

32. Loebenberg MI, Jones DA, Zuckerman JD: The effect of greater tuberosity placement on active range of motion after hemiarthroplasty for acute fractures of the proximal humerus. *Bull Hosp Jt Dis* 2005;62(3-4):90-93.

33. Greiner SH, Diederichs G, Kröning I, Scheibel M, Perka C: Tuberosity position correlates with fatty infiltration of the rotator cuff after hemiarthroplasty for proximal humeral fractures. *J Shoulder Elbow Surg* 2009;18(3):431-436.

34. Frankle MA, Ondrovic LE, Markee BA, Harris ML, Lee WE III: Stability of tuberosity reattachment in proximal humeral hemiarthroplasty. *J Shoulder Elbow Surg* 2002;11(5):413-420.

35. Neer CS II, Kirby RM: Revision of humeral head and total shoulder arthroplasties. *Clin Orthop Relat Res* 1982;(170):189-195.

36. Murthi A, Bigliani L: Four-part proximal humerus fractures, in Levine WN, Marra G, Bigliani L: *Fractures of the Shoulder Girdle*. New York, NY, Marcel Dekker, 2003, pp 113-130.

37. Kummer FJ, Perkins R, Zuckerman JD: The use of the bicipital groove for alignment of the humeral stem in shoulder arthroplasty. *J Shoulder Elbow Surg* 1998;7(2):144-146.

38. Kontakis GM, Tosounidis TI, Christoforakis Z, Hadjipavlou AG: Early management of complex proximal humeral fractures using the Aequalis fracture prosthesis: A two- to five-year follow-up report. *J Bone Joint Surg Br* 2009;91(10):1335-1340.

39. Cohen R: A porous tantalum trabecular metal: Basic science. *Am J Orthop (Belle Mead NJ)* 2002;31(4):216-217.

40. Levine B, Della Valle CJ, Jacobs JJ: Applications of porous tantalum in total hip arthroplasty. *J Am Acad Orthop Surg* 2006;14(12):646-655.

41. Bigliani LU, Flatow EL, McCluskey, Fischer RA: Failed prosthetic replacement for displaced proximal humerus fractures. *Orthop Trans* 1991; 15:747-748.

42. Kontakis G, Koutras C, Tosounidis T, Giannoudis P: Early management of proximal humeral fractures with hemiarthroplasty: A systematic review. *J Bone Joint Surg Br* 2008;90(11):1407-1413.

43. Naranja RJ Jr, Iannotti JP: Displaced three- and four-part proximal humerus fractures: Evaluation and management. *J Am Acad Orthop Surg* 2000;8(6):373-382.

44. Goldman RT, Koval KJ, Cuomo F, Gallagher MA, Zuckerman JD: Functional outcome after humeral head replacement for acute three- and four-part proximal humeral fractures. *J Shoulder Elbow Surg* 1995;4(2):81-86.

45. Neer CS II, Craig EV, Fukuda H: Cuff-tear arthropathy. *J Bone Joint Surg Am* 1983;65(9):1232-1244.

46. Bufquin T, Hersan A, Hubert L, Massin P: Reverse shoulder arthroplasty for the treatment of three- and four-part fractures of the proximal humerus in the elderly: A prospective review of 43 cases with a short-term follow-up. *J Bone Joint Surg Br* 2007;89(4):516-520.

47. Gallinet D, Clappaz P, Garbuio P, Tropet Y, Obert L: Three or four parts complex proximal humerus fractures: Hemiarthroplasty versus reverse prosthesis. A comparative study of 40 cases. *Orthop Traumatol Surg Res* 2009; 95(1):48-55.