Penetration of the Distal Femoral Anterior Cortex During Intramedullary Nailing for Subtrochanteric Fractures: A Report of Three Cases

Robert F. Ostrum, MD and Michael S. Levy, DO†*

Summary: Three cases of anterior distal femoral cortex penetration during intramedullary nailing for subtrochanteric fractures are documented. Case 1 involved a Zimmer (Warsaw, IN) M/DN antegrade femoral nail, case 2 a Howmedica (Allendale, NJ) long-stem Gamma nail, and case 3 a Synthes (Paoli, PA) titanium femoral nail with spiral blade locking. The anterior Zimmer nail penetration resulted in a displaced supracondylar fracture, which subsequently required revision. The Gamma nail as well as the Synthes nail were left impaled through the distal femoral cortex, and the subtrochanteric fractures went on to union. The anteroposterior radius of curvature for the Zimmer, the long Gamma, and the Synthes nail are 257 cm, 300 cm, and 150 cm, respectively. It has been estimated that the radius of curvature of the femoral diaphyseal canal is 114 to 120 cm. It appears that the difference in femoral anteroposterior bow between the bone and the implant is a contributing factor to distal femoral anterior cortex penetration in intramedullary nailing of subtrochanteric fractures.

Key Words: penetration, intramedullary nails, radius of curvature, subtrochanteric fracture

(*J Orthop Trauma* 2005;19:656–660)

Iatrogenic femoral neck fractures during intramedullary implant insertion for diaphyseal fractures have previously been reported.[1–3] Contributing factors included oblique nail insertion, improper technique, and instrumentation impingement.[1–3] Bursting of the femoral neck was seen while inserting slotted stainless steel nails and when the femoral neck-shaft angle was greater than 140°.[1–3] To our knowledge, there have been no reports of distal femoral anterior cortical penetration during nailings for subtrochanteric fractures.

The femoral intramedullary canal possesses an anterior bow, with a mid diaphyseal apex.[4] Further cross-sectional studies show that the medullary canal does not lay centrally within the femur but is positioned slightly anterior.[5,6] Anatomic femoral diaphyseal geometry and density differs with gender and age.[7–9] Cortical thinning naturally occurs during aging, and the greatest amount of thinning is in the anterior femoral cortex.[5,10] The shape of the femoral diaphyseal canal has been estimated in anatomic studies and remains constant.[11,12]

Early locking femoral nails lacked torsional stability secondary to a slot and by twisting conformed to the canal during insertion. The flexibility of the nonslotted cross-sectional nails that are currently used is maintained by material and cross-sectional design modifications.[13,14] Comparisons between the femoral intramedullary canal and current commercially available intramedullary nails have shown that the nails are straighter (more radius of curvature) than the femoral bow.[4,15] The design concept of a straighter radius of curvature of the nail is to assist in 3-point fracture fixation.[16] The anteroposterior bow helps to facilitate fracture reduction,[13] as well as externally guided distal cross locking.[17] However, the straighter radius of curvature in these nails may be a disadvantage, as illustrated by the following 3 case studies.

CASE HISTORIES

Case 1 is a 65-year-old female who sustained a left subtrochanteric femoral fracture. A Zimmer (Warsaw, IN) M/DN antegrade femoral nail was inserted through a piriformis fossa entry site for fracture fixation (Fig. 1A). Following nail insertion, it was noted that the distal end of the nail had penetrated the anterior cortex (Fig. 1B). The nail was statically cross-locked. A displaced supracondylar femoral fracture developed 10 days postoperatively during mobilization in a hinged knee brace (Fig. 1C). Fracture treatment included a revision nailing with a Synthes (Paoli, PA) statically locked titanium femoral nail and allograft (Fig. 1D). The Synthes nail has a radius of curvature closer to that of the femur and the end of the nail was therefore located in a more posterior position. The fracture healed uneventfully after the revision nailing.

The second case is a 67-year-old male who sustained a closed right subtrochanteric femoral fracture. The patient was treated with a Howmedica (Allendale, NJ) long-stem Gamma nail with a greater trochanter starting point (Fig. 2A). During insertion, it was also noted that the nail had penetrated the anterior cortex (Fig. 2B). The nail was left in place through the anterior cortex, statically cross-locked, and the patient's fracture went onto uneventful healing. The patient had no complaints referable to the distal implant but does complain of arthritic knee pain.

Accepted for publication November 24, 2004.
From the *Department of Orthopaedic Surgery, Cooper Hospital/University Medical Center, Camden, NJ, and the †Department of Orthopaedic Surgery, Peninsula Hospital Center Consortium, Far Rockaway, NY.
The authors have received nothing of value.
No financial support of this project has occurred. The devices that are the subject of this manuscript have been approved by the FDA.
Reprints: Robert F. Ostrum, MD, Director of Orthopaedic Surgery, Cooper Hospital/University Medical Center, 3 Cooper Plaza, Suite 411, Camden, NJ 08103 (e-mail: Ostrum-robert@cooperhealth.edu).

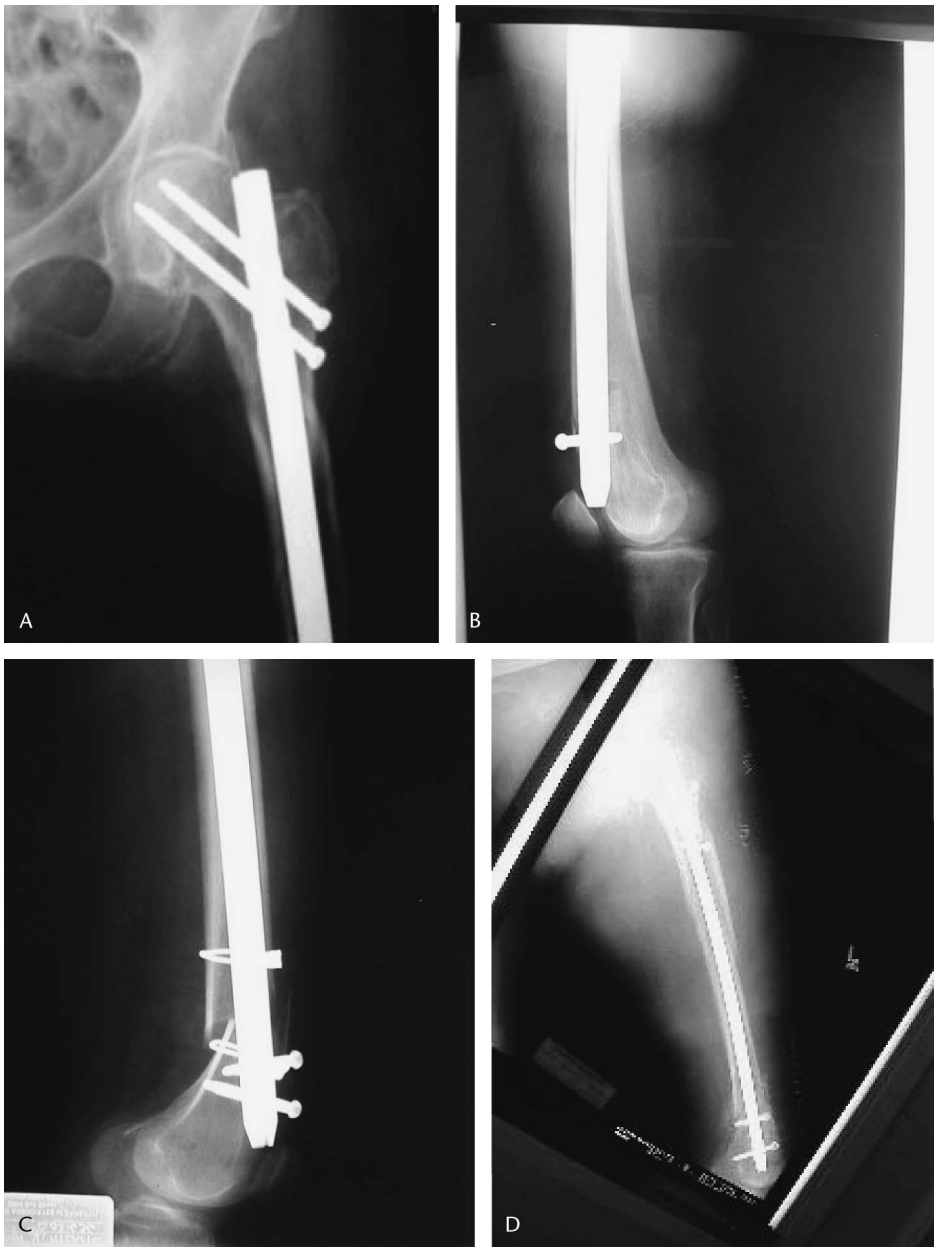

FIGURE 1. A, Case 1. Zimmer M/DN antegrade nail, with a 257-cm radius of curvature showing proximal fixation. B, Case 1. Distal anterior cortex penetration. C, Case 1. Supracondylar femur fracture following mobilization of the patient at postoperative day 10. D, Case 1. Postoperative revision of subtrochanteric and supracondylar femur fracture with a more curved Synthes nail (lesser radius of curvature).

The third case is a 71-year-old female who sustained a closed subtrochanteric left femoral fracture. The patient was treated with a Synthes (Paoli, PA) titanium femoral nail and spiral locking blade inserted through a slightly anterior piriformis fossa entry site (Fig. 3A). As in the other cases, the nail penetrated the anterior cortex distally (Fig. 3B). The nail was left in place through the anterior cortex and was not statically cross-locked. At 6 months, the patient had some distal anterior thigh pain, the spiral locking blade had slid laterally within the nail as the fracture compressed, and an osteotomy of the proximal femur and plating were being contemplated.

DISCUSSION

Christie and Court-Brown[2] reported on 4 iatrogenic femoral neck fractures that occurred during nailing of 143 patients with femoral shaft fractures. Oblique nail insertion and lateral starting holes were implicated as causal factors. Treatment included femoral head compression screw fixation with static locking in those cases with comminution. Simonian et al[3] reported 4 femoral neck fractures in 315 consecutive nailings using the AO/ASIF universal femoral nail (Paoli). The instrumentation impinged on valgus femoral necks during insertion of the nail below the tip of the greater trochanter. Treatment included femoral head compression screw fixation. Simonian et al,[3] in a cadaver study, reproduced this fracture when the femoral neck-shaft angle was greater than 140°. Apivatthakakul and Arpornchayanon[1] also reported an iatrogenic femoral neck fracture in a 34-year-old male that was a result of an improperly inserted nail with a reverse curvature.

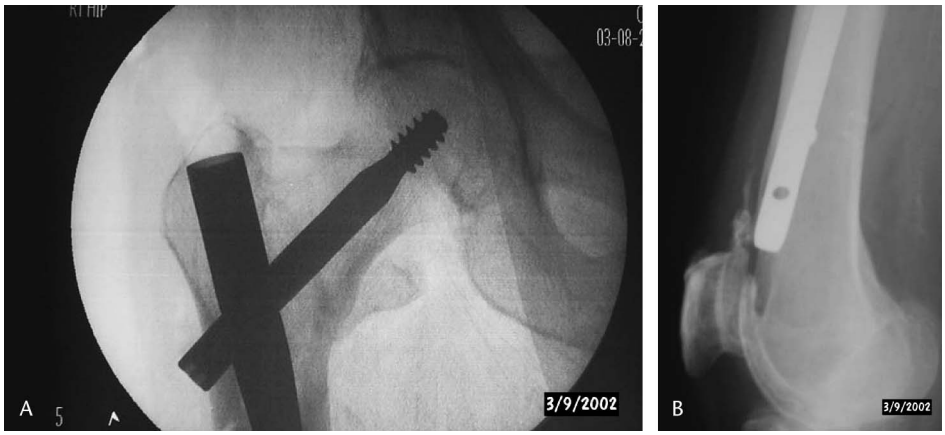

FIGURE 2. A, Case 2. Howmedica long stem Gamma nail with a 300-cm radius of curvature showing proximal fixation. B, Case 2. Distal anterior cortex penetration.

All of these reported femoral neck fractures healed uneventfully without evidence of avascular necrosis. These studies involved bursting of the femoral neck while inserting older slotted stainless steel nails.[1–3] However, to our knowledge, distal anterior cortex penetration during intramedullary nailing for subtrochanteric fractures has not been previously reported in the literature.

Harper and Carson analyzed 14 cadaveric femurs and found the average radius of curvature to be 114.4 cm, smaller than the nails commercially available at the time in 1987.[4] Harper and Carson concluded that the appropriate nail entry site is located at the junction between the neck and the greater trochanter anterior to the piriformis fossa. Johnson et al determined the correct entry site in the proximal femur by using a retrograde technique.[13] In addition, they demonstrated bursting of the proximal femur with an insertion site anterior to the piriformis fossa.

Egol et al measured 892 femurs, 56 embalmed and the rest from skeletal collections at 2 museums, and found the average radius to be 120 cm.[15] Changes in the anteroposterior radius of curvature secondary to age were not found to be statistically significant. A substantial radius of curvature mismatch was observed between the canals and the nails whose curvature ranged from 186 cm to 300 cm.[15] Ehmke et al measured the radius of curvature of reamed femoral canals and found substantial differences when comparing the piriformis fossa and the greater trochanter entry points.[11] The radius of curvature for the reamed canal is also less than the radii of the nails.

In our first case, a Zimmer (Warsaw) M/DN antegrade nail was used, with a 257-cm radius of curvature. A Howmedica long-stem Gamma nail with a 300-cm radius of curvature was used in the second case. The design of the long-stem Gamma nail has recently been modified to a 200-cm radius of curvature to closer approximate the curvature of the femur. A Synthes

FIGURE 3. A, Synthes titanium femoral nail with a 150-cm radius of curvature and spiral locking blade showing proximal fixation. B, Distal anterior cortex penetration.

titanium femoral nail with a 150-cm radius of curvature was used in the third case.

Modern reamed intramedullary nailing techniques have been credited to Küntscher, who designed straight nails with no anterior bend.[16] The fit between the canal and the nail was obtained by using large diameter implants that attempted to provide 3 points of fixation. Nails with a slotted cloverleaf cross-section also possessed a larger radius of curvature (straighter). However, these early locking slotted nails were flexible in both bending and torsion; thus, stress during insertion was minimal and they could conform to the femoral bow. Slotted intramedullary nails have about 3% of the torsional rigidity of the intact femur, whereas nonslotted nails have 50% of the rigidity of the femur.[14] Nonslotted cannulated cross-sectional nails were designed with a radius of curvature that more closely approximated the anterior bow of the reamed canal. Prior to free hand distal interlocking, this more anatomic radius assisted distal cross locking utilizing external drill targeting devices.[17] The nonslotted cannulated nails were developed to increase the strength of the implant, especially those with a smaller diameter. This increased rigidity seen with closed section nails may lead to more difficulties in passing the nail, as it may not twist and bend to conform to the femoral confines distally.[14]

The reasons why these 3 different nail designs all led to anterior cortical penetration may lie in the fracture pattern. A subtrochanteric fracture by definition leaves the isthmus of the femur intact. With a mid-diaphyseal fracture the fragments can conform to the nail. With distal one-third fractures, the distal canal is large and the nail can find ample room, often with little deformity, to seat itself in the supracondylar region. However, with subtrochanteric fractures, the nail must follow the isthmus and is then fixed in its position in the distal femur. In effect, this is nailing a femur with a smaller radius of curvature with a nail with a larger radius of curvature, ie, the nail is straighter than the curvature of the femur. This could possibly lead to the stiffer, closed section nail exiting through or close to the distal femoral anterior cortex. Also, anatomically it has been shown that the medullary canal lies slightly anterior to the distal femur and that with age, the anterior femoral cortex undergoes the greatest amount of thinning.[5,6,10]

Another factor that may also be of some significance is that when using a piriformis fossa entry site for subtrochanteric nailing, the surgeon attempts to insert the nail slightly more anterior to allow for anteversion of the femoral neck and cephalomedullary device placement. An anterior starting point may translate to the nail ending up more anterior in the distal femur, perhaps even out the anterior cortex. Further, external rotation of the nail, to allow for anteversion and placement of the cephalomedullary device into the femoral head, may rotate the nail enough that the radius of curvature of the implant is no longer in line with the bow of the femur. This could cause further impingement of the distal nail tip on the anterior cortex.

Although the Synthes nail has a radius of curvature that more closely approximates that of the femur than the other nails employed, rotation of the nail plus a slightly more anterior starting point for cephalomedullary nail placement may have led to the distal femoral cortical penetration. These same 2 factors most likely contributed to the Zimmer nail penetration because it was also a cephalomedullary device started in the piriformis fossa. The older Gamma nail with its 300-mm radius of curvature and nonslotted design made it a very straight and stiff nail. These parameters alone could make a fit in the distal femur difficult, with the distal tip of the nail sitting close to or on the endosteal surface of the distal anterior cortex. It was subsequently modified to a 200-mm radius of curvature to allow for better distal femoral fit.

CONCLUSIONS

There is a mismatch between the radius of the femoral nails currently available and the femoral canal, ie, nails with a larger radius of curvature (straighter) are being inserted in a femur with a smaller radius of curvature (less straight than the nail). Additionally, subtrochanteric fractures with an intact diaphysis may not allow the femur to "conform" to these less flexible nails. As a result, the distal tip of the nail is forced into a nonanatomic anterior position during final seating of the nail in the distal femur. Furthermore, if the nail is inserted with an anterior entry point, then the likelihood of distal anterior penetration increases. Nails manufactured with a radius of curvature more closely resembling the femoral canal may lead to a better fit in the distal femur; however, insertion site and nail rotation may still lead to distal femoral impingement, as was seen with the Synthes nail. Orthopaedic surgeons should be aware of the potential for anterior cortical penetration of the distal femoral cortex with nailing of subtrochanteric fractures. If final nail seating in the distal femur is not effortless, then a lateral fluoroscopic view should be obtained to examine the distal nail placement in the femoral canal. These reported cases with different nails and different insertion sites stress that this complication can occur with any technique or implant.

ACKNOWLEDGMENTS

The authors thank Terry Philbin, DO, and Sanjay Mehta, MD, for allowing the use of their cases for this publication.

REFERENCES

1. Apivatthakakul T, Arpornchayanon O. Iatrogenic femoral neck fracture caused by malinsertion of a curved intramedullary nail. *Injury.* 2001; 32:727–729.
2. Christie J, Court-Brown C. Femoral neck fracture during closed medullary nailing: brief report. *J Bone Joint Surg Br.* 1988;70:670.
3. Simonian PT, Chapman JR, Selznick HS, et al. Iatrogenic fractures of the femoral neck during closed nailing of the femoral shaft. *J Bone Joint Surg Br.* 1994;76:293–296.
4. Harper MC, Carson WL. Curvature of the femur and the proximal entry point for an intramedullary rod. *Clin Orthop*. 1987;220:155–161.
5. Stephenson P, Seedhom BB. Cross-sectional geometry of the human femur in the mid-thigh region. *Proc Inst Mech Eng [H]*. 1999;213: 159–166.
6. Walensky MA. A study of anterior curvature in man. *Proc Inst Mech Eng [H]*. 2001;215:221–228.
7. Beck TJ, Mourtada FA, Ruff CB, et al. Experimental testing of a DEXA-derived curved beam model of the proximal femur. *J Orthop Res*. 1998; 16:394–398.
8. Ruff C, Hayes WC. Cross-sectional geometry of Pecos Pueblo femora and tibiae—a biomechanical investigation: II. Sex, age, and side differences. *Am J Phys Anthropol*. 1983;60:383–400.

9. Taaffe DR, Lang TF, Fuerst T, et al. Sex- and race-related differences in cross-sectional geometry and bone density of the femoral mid-shaft in older adults. *Ann Hum Biol*. 2003;30:329–346.
10. Feik SA, Thomas CD, Bruns R, et al. Regional variations in cortical modeling in the femoral mid-shaft: sex and age differences. *Am J Phys Anthropol*. 2000;112:191–205.
11. Ehmke L, Polzin B, Roth C, et al. Femoral intramedullary nailing: geometry of the reamed canal. Proceedings of American Society of Biomechanics; 2003; Poster #110.
12. Steriopoulos K, Psarakis SA, Savakis C, et al. Architecture of the femoral medullary canal and working length for intramedullary nailing. *Acta Orthop Scand Suppl*. 1997;275:123–126.
13. Johnson KD, Tencer AF, Sherman MC. Biomechanical factors affecting fracture stability. *J Orthop Trauma*. 1987;1:1–11.
14. Johnson KD, Tencer AF. Mechanics of intramedullary nails for femoral fractures. *Unfallchirurgie*. 1990;93:506–511.
15. Egol KA, Chang EY, Koval KJ, et al. Anterior curvature of the femur. Consequences of its mismatch with currently used intramedullary nails. *J Orthop Trauma*. 2004;18:410–415.
16. Küntscher G. The Küntscher method of intramedullary fixation. *J Bone Joint Surg Am*. 1958;40A:17–26.
17. Levy MS. Deformation analysis of the Alta intramedullary rod during insertion. Presented at: First World Congress of Biomechanics; August 30–September 4, 1990; San Diego, California.