ELSEVIER

Injury, Int. J. Care Injured 34 (2003) 349–356

INJURY
INTERNATIONAL JOURNAL OF THE CARE OF THE INJURED

www.elsevier.com/locate/injury

Femoral exchange nailing for aseptic non-union: not the end to all problems

Paul A. Banaszkiewicz [a,b], Adel Sabboubeh [a,b], Ian McLeod [a,b], Nicola Maffulli [a,b,*]

[a] *Department of Orthopaedics, University of Aberdeen Medical School, Foresterhill, Aberdeen AB25 2ZD, UK*
[b] *Department of Trauma and Orthopaedic Surgery, Keele University School of Medicine, Hartshill, Stoke on Trent ST4 7QB, UK*

Accepted 28 May 2002

Abstract

We report the results of a single centre prospective study of exchange nailing for aseptic non-union of a femoral fracture. Eighteen patients with 19 aseptic femoral non-unions had exchange nailing performed in our institution. We collected data on mechanism of injury, original fracture type, and indication for exchange nailing, further surgery and major complications. In 11 non-unions (58%), the exchange nail procedure alone resulted in fracture union with a mean time to radiographic union of 9 months (range 3–24 months). The non-union did not heal in five patients, two patients developed an infected non-union, and one patient required dynamisation of the exchange nail. Fracture healing was eventually achieved in 18 non-unions (95%). Complications following exchange nailing occurred in 11 fractures (58%), in which further surgery was required (four repeat exchange nailings, two Ilizarov frame applications and five nail removals). The role of reamed exchange nailing in the treatment of femoral non-union needs to be re-evaluated. Although fracture healing is eventually achieved in most patients, a significant number of them required additional surgery to achieve union or to deal with complications arising from the exchange nailing.

1. Introduction

The local complications of femoral intramedullary nailing include fracture mal-alignment, delayed or non-union, osteomyelitis and nail or screw deformation or breakage [1,2]. Reamed secondary femoral exchange nailing is regarded as the procedure of choice in treating femoral diaphyseal non-unions [3]. It is considered as a relatively simple procedure in which the fracture site is not exposed, blood loss minimal and hospital stay short. Historically, success rates in the region of 96–100% for aseptic diaphyseal non-unions have been reported [4]. Recently, however, conflicting reports on its success have been published. One study reported a high rate of failure (47%), with one or more additional procedures required to achieve fracture union [5]. Another study achieved a 96% union rate without the need for additional procedures [6]. In response to these differing views on the efficacy of exchange nailing, we report our own experience of femoral exchange nailing for aseptic non-union of a femoral fracture.

* Corresponding author. Present address: Department of Trauma and Orthopaedic Surgery, Keele University School of Medicine, North Staffordshire Hospital, Thornburrow Drive, Hartshill, Stoke on Trent, Staffordshire ST4 7QB, UK. Tel.: +44-1782-554-608; fax: +44-1782-412-236.
E-mail address: n.maffulli@keele.ac.uk (N. Maffulli).

2. Patients and methods

A total of 18 patients with 19 femoral fractures required exchange nailing for aseptic non-union during the period July 1989–February 1998 at our institution. During this period, 412 primary femoral intramedullary nails were performed. In all patients the original fracture resulted from high-energy trauma.

Initial treatment consisted of 13 reamed nails, three unreamed nails, and three Kuntscher nails. The original nail diameter ranged from 10 to 14 mm, with the canal being over-reamed by 1–1.5 mm. The Kuntscher nails had been used in patients who had their original fracture nailed many years previously (1969, 1970, and 1982).

Factors considered in the present study included mechanism of injury, AO [7] and Winquist and Hansen [8] classification, indication for exchange nailing, time interval between the original and the exchange nailing, duration of surgery, the necessity for further surgery and major complications. In addition, we reviewed smoking history, the use of non-steroidal anti-inflammatory medications (NSAIDs), whether the exchange nail had been statically or dynamically locked, and the diameter of the nail in the exchange nailing procedure.

0020-1383/03/$ – see front matter © 2003 Elsevier Science Ltd. All rights reserved.
PII: S0020-1383(02)00191-2

Table 1
Characteristics of patients studied

Patient	Age	Sex	Injury	Multiply injured	Open/ closed	AO	Winquist	First nail	Reason for EN	Interval between nails (months)	Complications	Further surgery	First nail static/ dynamic	EN static/ dynamic	Smoking	NSAID use	Time union after EN (months)
1	40	M	MVA		Closed	32-C1.1	3	R	Non-union with nail breakage	7	None	Removal EN	Static	Static	No	No	3
2	32	M	BvsMV		Closed	32-C1.3	4	R	Non-union with nail breakage	12	Infected non-union, broken screws	Ilizarov frame, Removal broken screws	Dynamic	Dynamic	No	No	48
3	26	M	MVA	Yes	2	32-C1.3	4	UR	Delayed union	4	Broken EN with non-union	REN	Static	Static	Yes	No	6
3	26	M	MVA	Yes	2	32-C1.1	4	UR	Non-union	7	Non-union	REN, Removal REN	Dynamic	Dynamic	Yes	No	12
4	32	M	SA		Closed	32-B1.2	3	UR	Non-union	7	None	No	Static	Static	Yes	No	12
5	23	F	MVA	Yes	Closed	32-B2.2	2	R	Non-union	24	None	No	Static	No locking	Yes	Yes	6
6	16	F	MCA	Yes	2	32-B2.2	2	R	Non-union	29	None	No	Dynamic	No locking	Yes	Yes	7
7	26	M	IA	Yes	Closed	32-C1.3	3	R	Delayed union with nail breakage	5	Broken screws	No	Static	Dynamic	Yes	No	6
8	36	M	IA	Yes	Closed	32-B2.2	2	R	Non-union with nail breakage	6	Broken screws	Removal EN	Static	Dynamic	No	No	7
9	17	M	MCA	Yes	Closed	32-B3.2	3	R	Non-union	6	None	No	Static	Static	Yes	Yes	8
10	20	M	MCA	Yes	3B	32-A2.1	2	R	Non-union with nail breakage	26	Delayed union	Removal EN	Static	No locking	No	No	24
11	29	M	MVA	Yes	Closed	32-C1.3	4	R	Non-union	7	None	Removal EN	Dynamic	No locking	No	No	14
12	24	M	MVA	Yes	Closed	32-B1.1	2	R	Non-union with nail breakage	10	Delayed union	Dynamisation EN	Static	Dynamic	No	No	22
13	61	M	IA		Closed	32-A1.2	2	R	Non-union with nail breakage	14	Infected non-union	Ilizarov frame	Static	Dynamic	No	Yes	36
14	26	M	MCA		Closed	32-B2.3	3	R	Non-union	6	None	No	Static	Static	Yes	Yes	6
15	32	M	MVA	Yes	Closed	32-B1.2	3	R	Non-union with nail breakage	6	Non-union,broken screws	REN	Static	Static	No	Yes	24
16	91	M	MVA		Closed	32-B1.2	3	K-nail	Non-union with nail breakage	228	None	No	Static	Static	Yes	No	6
17	72	M	PvsMV	Yes	Closed	32-A2.2	2	K-nail	Non-union with nail breakage	252	Broken EN with non-union	REN,Dynamisation REN	Static	Static	Yes	Yes	14
18	60	M	MVA		Closed	32-B1.2	2	K-nail	Non-union	96	Non-union	Dynamisation EN	Static	Static	Yes	Yes	Non-union

M, male; F, female; MVA, motor vehicle accident; BvsMV, bicycle vs. motor vehicle; SA, sporting accident; MCA, motorcycle accident; IA, industrial accident; PvsMV, pedestrian vs. motor vehicle; R, reamed; UR, unreamed; EN, exchange nail; REN, repeat exchange nail.

Fig. 1. A 61-year-old male who sustained a left femoral shaft fracture. Anteroposterior and lateral radiographs of a fractured left femur (a and b). Anteroposterior and lateral radiographs of infected non-union left femur following exchange nailing (c and d). Anteroposterior and lateral radiographs after application Ilizarov frame (e and f). Anteroposterior and lateral radiographs of united left femoral fracture 4 years following original fracture (g and h).

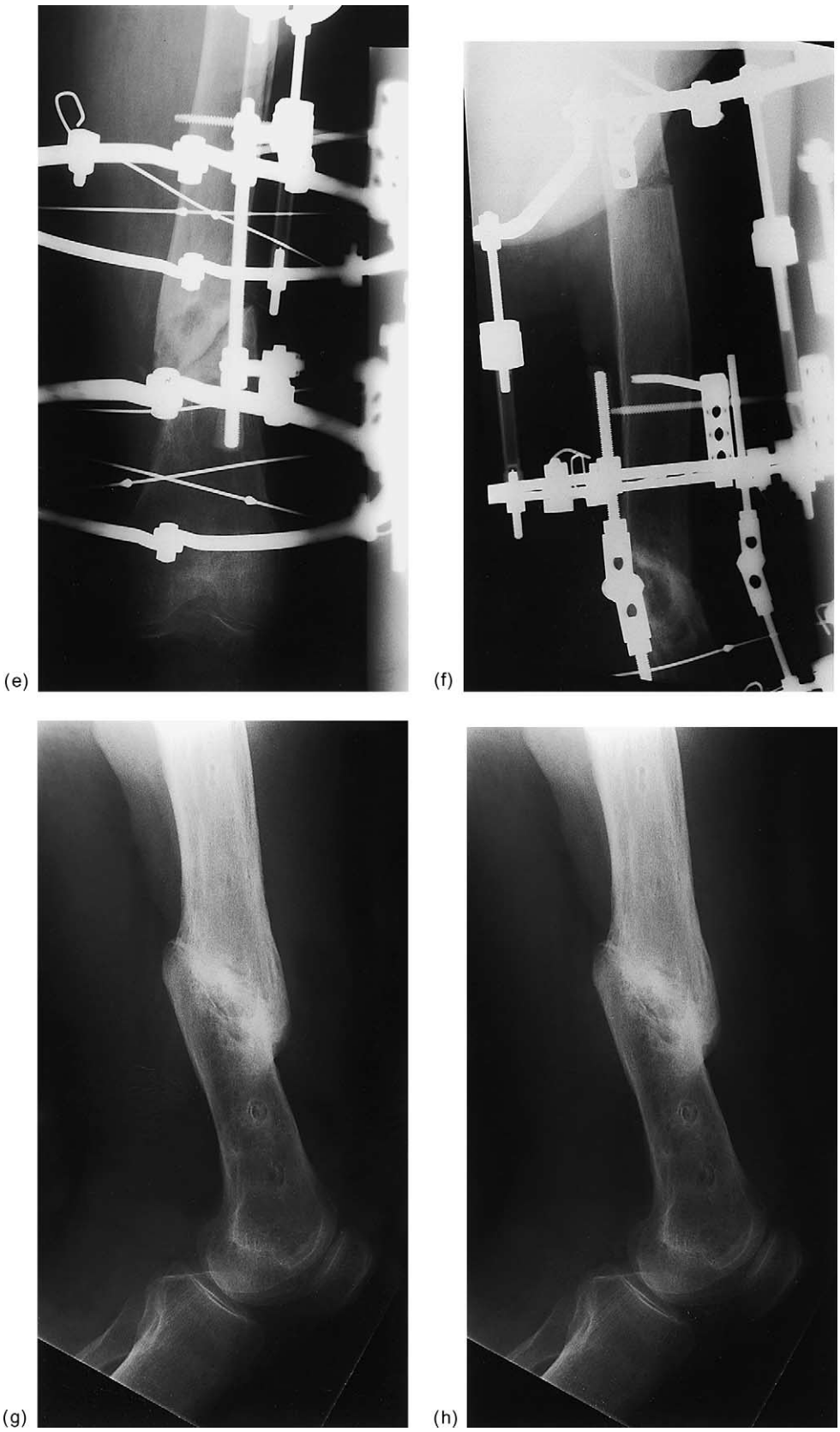

Fig. 1. (*Continued*).

Fig. 2. A 24-year-old male motor vehicle driver who sustained a right femoral shaft fracture, fracture/dislocation left hip, fractured right talus and fractured right patella. Anteroposterior radiograph of fractured right femur (a). Lateral radiograph of non-union right femur with nail breakage 10 months later (b). Anteroposterior radiograph following exchange nailing (c). Anteroposterior and lateral radiographs of united right femoral fracture 3 years following original fracture (d and e).

(e)

Fig. 2. (*Continued*).

Outcome measures included duration of hospital stay, time to full weight bearing, time taken to achieve bony union, return to prior employment and attainment of pre-fracture activity. Clinically, full weight bearing was defined as minimal or no pain at the fracture site with the ability to walk unaided. Radiographic fracture union was considered to be present if radiographs demonstrated bridging callus on at least three cortices in standard anteroposterior and lateral radiographs.

A non-union was diagnosed if clinical or radiographic signs of union were not firmly established after 6 months.

All data were entered into a commercially available statistical database package (Microsoft SPSS). Descriptive statistics are given.

3. Surgical technique

The reamed exchange nailings were performed on a radiolucent fracture table. In most cases, the intramedullary canal was over-reamed 3 mm above the original nail diameter, the endosteal fibrous tissue was removed and a nail of at least 2 mm greater diameter inserted. In two cases, nails of the same diameter were used because of difficulties over-reaming the canal to accept a larger nail: the additional reaming required to insert a larger nail might have caused the reamer to jam and potentially break. The increase in nail diameter thus ranged from 0 to 4 mm.

We used static locking in nine patients, dynamic locking in six, and no locking in four. Static locking was used if the non-union was very proximal or distal [9]. In the early part of the study period, we did not regularly perform intra-operative cultures in patients in whom clinical examination did not led us to suspect an infection. Samples of bone reamings and endosteal fibrous tissue were routinely sent for culture in the last eight patients: none was positive.

The mean duration of exchange nail surgery was 2 h 30 min (range 1.25–5 h). In seven patients (37%), we experienced technical difficulties during the exchange nailing. In three patients, it was difficult to remove the distal part of a broken femoral nail. In each case the nail was retrieved using a long hook. In three patients, it was difficult to remove a broken screw, which had to be cored out under image intensification. In another, heterotopic bony overgrowth over the greater trochanter required the use of an osteotomy to expose the entry point of the nail.

Patients were mobilised full weight bearing as soon as possible post-operatively, and quadriceps and knee range of motion exercises were encouraged.

4. Results

A total of 18 patients with 19 femoral fractures required exchange nailing for aseptic non-union.

There were 16 male and 2 females, with a mean age of 36 years (range 16–81 years). The majority of fractures (14; 74%) were caused by road traffic accidents, and all fractures were high velocity injuries with 12 patients multiply injured with two or more long bone fractures (Table 1). The fractures were open in four cases. Ten of the 18 patients (55%) were smokers, and eight were taking regular NSAIDs at the orthopaedic outpatient clinic when exchange nailing was planned. No patients had either diabetes or known peripheral vascular disease. One patient was referred to our hospital for further care following an unreamed femoral nailing. All other patients were initially treated at our institution. The mean time interval between original and exchange femoral nail was 40 months (range 4 months to 21 years). Removing from the calculation of the mean time between original and exchange nailing the three patients who received an exchange nailing 96, 228 and 252 months after the primary nailing, the mean decreased to 6.2 months.

Complications following exchange nailing included two non-unions, two infected non-unions requiring Ilizarov frame application (Fig. 1), two broken exchange nails with non-union, and two delayed unions with fracture healing at 22 and 24 months following exchange nailing (Fig. 2). Twelve fractures (63%) required further surgery, including four repeat exchange nailing procedures to promote further healing. Four exchange nails and one repeat exchange nail required removal after fracture healing due to pain and irritation at the point of nail insertion. The mean duration of hospital stay was 3.5 days (range 1–9 days), excluding

two patients who remained in hospital for 1 and 4 months, respectively, because of social circumstances. The mean time to full weight bearing and radiographic union following exchange nailing was 3.6 months (range 2 weeks to 9 months) and 9 months (range 3–24 months), respectively.

Mean duration of follow-up following exchange nailing was 1.5 years (range 9 months to 4 years), with no patient lost to follow-up.

All femoral fractures eventually healed except one 81-year-old patient with an asymptomatic non-union. This occurred despite dynamisation of the exchange nail: in view of the patient's advanced age and poor operative risk, it was managed conservatively.

Eight patients were able to return to their old employment whilst two patients returned to a more sedentary job. Three patients were retired prior to the injury and five patients were unable to return to work, although in two, the cause was related to the overall severity of their injuries. Ten patients achieved a full level of pre-fracture activity, six did not achieve it, and in two patients, although pre-fracture activity was not reached, this was due to a combination of the injuries sustained.

5. Discussion

Excellent results have been reported in the management of femoral fractures using interlocking nails [1,10]. However, intramedullary nailing does cause problems. Delayed union, non-union with or without infection, screw breakage, nail breakage or deformation can all occur [2,21].

Reamed exchange nailing is regarded as the procedure of choice for the treatment of delayed or non-union, with excellent union rates reported [11]. However, conflicting reports on its success have been recently reported. Weresh et al. reported a high rate of failure (47%), with one or more additional procedures required to achieve fracture union [5]. Furlong et al., on the other hand, achieved a 96% union without the need for additional procedures [6]. Our own results show that in 11 non-unions (58%), the exchange nail procedure alone resulted in fracture union.

Despite being a trauma centre with a consultant led service, significant complications occurred in more than half of all patients (58%), and further surgery was required in just under two-thirds of the patients (63%). This high incidence of further surgery and complications may be due to several factors. Indications for intramedullary nailing of femoral fractures have expanded in recent years with the introduction of interlocking and reconstruction-type implants [12]. Studies suggest a higher non-union rate in more complex femoral fractures [13]. These non-unions may be more difficult to treat, accounting for a lower success rate in our patients. In the present study, all fractures were caused by high-energy trauma, with extensive disruption of the soft tissue envelope and blood supply around the fracture site.

We believe the nature of the non-union to be important. Some studies include non-unions arising from elective procedures such as leg lengthening operations [6]. The biological nature of these non-unions is different, with a lower risk of healing complications after exchange nailing.

Another potential variable that may affect outcome is initial fracture management. All fractures in our study were primarily treated with intramedullary nails, the non-union representing a failure of the nailing procedure. Fractures initially managed with other modalities of treatment, such as plate devices, may respond more favourably to exchange nailing because of the advantages of the nailing procedure over them [5,6].

Five patients who required exchange femoral nailing had distraction at the fracture site at the time of the original nailing. Distraction is known to be deleterious to fracture union, and this may have potentially contributed to the non-union. During the period of study, eight nails were also exchanged early for technical errors at the time of original nailing. As this study concerns exchange femoral nailing for non-unions, these patients would not have been eligible. Five of these nailings had been performed elsewhere. All fractures healed uneventfully after exchange nailing without further surgery, implying a technical failure of the original nailing rather than biological failure of fracture healing.

Smoking has been implicated in impeding bone metabolism and fracture repair, and increasing the incidence of non-union [14]. Hak et al. found a detrimental effect of smoking on the success of exchange nailing, but this was not apparent in our patients [15]. The inhibitory effect of NSAIDs on the osteoblastic activity of bone has been extensively studied, and a marked association between non-union and the use of NSAIDs after intramedullary nailing has been reported [16].

Reamed exchange nailing has been used successfully to treat infected femoral non-unions. Klemm reported fracture union rates of 89.5% in infected femoral non-unions following exchange reamed nailing [17]. An infected femoral non-union is, however, extremely difficult to treat. We do not routinely perform exchange nailing for infected femoral non-unions, and prefer to use Ilizarov techniques. No patient in our series presented with obvious signs or symptoms of a grossly infected non-union, and the intra-operative cultures of bone reamings and endosteal fibrous tissue obtained in eight patients did not grow any pathogens. Unfortunately in the early part of our study, we did not routinely measure CRP/ESR values or send bone reaming for culture. We now routinely measure CRP/ESR values and send bone reaming for culture. There were only two cases of infected non-union following exchange nailing although we can not exclude a sub-clinical infection in a number of cases.

Exchange nailing is thought to promote healing of a non-union by three different mechanisms. Increasing the nail diameter improves mechanical stability, allowing weight bearing and loading of the fracture, and this should stimulate

healing [4]. Also, reaming causes a marked increase in periosteal blood flow, which should stimulate the formation of periosteal new bone [18]. Finally, the reaming products are osteoinductive. After primary nailing, these products are extruded through the fracture site, but at exchange nailing the fibrous tissue will tend to confine the reamings to the medullary canal [4]. Probably, the increase in periosteal blood supply following reaming is the most important stimulus to healing of the non-union [10].

In the present study, nail breakage with non-union occurred in seven patients. An unstable fracture pattern (segmental or comminuted) or the use of a small diameter nail increases the risk of nail breakage [12,19]. Distal femoral fractures have a high incidence of intramedullary nail breakage, especially if the fracture has been produced by high-energy trauma and the patient was encouraged to weight bear early [19]. Early weight bearing with delayed fracture healing increases the time over which cyclic stress may act to cause nail breakage [20]. Technical errors in nail insertion, such as scoring the nail during locking, may weaken the nail or create stress risers. Excessive impaction during nail insertion due to under-reaming of the medullary canal may also weaken the nail. Intramedullary nails rarely break when no locking screws are used [19]. Statically locked nails can produce high concentrations of stress at the proximal or distal end of the nail, thus predisposing it to breakage.

A broken nail, while relatively uncommon, can be difficult to manage. Multiple techniques have been described for removal of broken nails, including the use of clamps, forceps, hooks, pliers or osteotomes [21].

Four patients required exchange nail removal and one patient a repeat exchange removal because of pain and irritation at the proximal insertion site. Where possible, we adopt a conservative policy and do not routinely remove nails unless clinically indicated.

In the years encompassed by this study, there have been major advances in trauma care in our institution. We are now more aware of the potential complications associated with the use of both primary and exchange nailings, and adopt a more cautious approach in our preoperative planning, surgical technique and follow-up of patients undergoing this procedure.

6. Conclusions

Although reamed exchange nailing probably remains the treatment of choice for femoral non-union, its role needs to be re-evaluated.

While fracture healing was eventually achieved in 95% of our patients, a significant number required additional surgery to achieve union or deal with complications arising from the exchange nailing. It can be a technically difficult procedure especially if a broken screw or nail needs to be removed.

Careful patient selection and preoperative planning are necessary to minimise these difficulties. Patients should be forewarned that further surgery might be likely.

References

[1] Winquist RA, Hansen Jr ST, Clawson DK. Closed intramedullary nailing of femoral fractures: a report of five hundred and twenty cases. J Bone Joint Surg Am 1984;66:529–39.
[2] Zych GA, Hutson Jr JJ. Diagnosis and management of infection after tibial intramedullary nailing. Clin Orthop 1995;315:153–62.
[3] Kempt I, Grosse A, Rigaut P. The treatment of non-infected pseudoarthrosis of the femur and tibia with locked intramedullary nailing. Clin Orthop 1986;212:142–54.
[4] Court-Brown CM, Keating JF, Christie J, McQueen MM. Exchange intramedullary nailing. Its use in aseptic tibial non-union. J Bone Joint Surg Br 1995;77B:407–11.
[5] Weresh MJ, Hankanson R, Stover M, Sims SH, Kellam JF, Bosse MJ. The failure of reamed intramedullary exchange nailing for aseptic un-united femoral shaft fractures. Orthop Trauma Assoc 1997;133–4 [abstract].
[6] Furlong AJ, Giannoudis PV, DeBoer P, Matthews SJ, MacDonald DA, Smith RM. Exchange nailing for femoral shafts aseptic non-union. Injury 1999;30:245–9.
[7] Muller ME, Nazarian S, Koch P, Schatzker J. The comprehensive classification of fractures of long bones. Berlin: Springer, 1990.
[8] Winquist RA, Hansen Jr ST. Comminuted fractures of the femoral shaft treated by intramedullary nailing. Orthop Clin North Am 1980;11(3):633–48.
[9] Brumback RJ, Toal Jr TR, Murphy-Zane MS, Novak VP, Belkoff SM. Immediate weight-bearing after treatment of a comminuted fracture of the femoral shaft with a statically locked intramedullary nail. J Bone Joint Surg Am 1999;81A:1538–44.
[10] Wu CC, Chen WJ. Treatment of femoral shaft aseptic non-unions: comparison between closed and open bone-grafting techniques. J Trauma 1997;43:112–26.
[11] Webb LX, Winquist RA, Hansen ST. Intramedullary nailing and reaming for delayed union or non-union of the femoral shaft: a report of 105 consecutive cases. Clin Orthop 1986;212:133–41.
[12] Gibbons CL, Gregg-Smith SJ, Carrell TW, Murray DW, Simpson AH. Use of the Russell–Taylor reconstruction nail in femoral shaft fractures. Injury 1995;26:389–92.
[13] Kempf I, Grosse A, Beck G. Closed locked intramedullary nailing: its application to comminuted fractures of the femur. J Bone Joint Surg Am 1985;67(5):709–20.
[14] Raikin SM, Landsman JC, Alexander VA, Froimson MI, Plaxton NA. Effect of nicotine on the rate and strength of long bone fracture healing. Clin Orthop 1998;353:231–7.
[15] Hak DJ, Lee SS, Goulet JA. Success of exchange reamed intramedullary nailing for femoral shaft non-union or delayed union. J Orthop Trauma 2000;14(3):178–82.
[16] Giannoudis PV, MacDonald DA, Matthews SJ, Smith RM, Furlong AJ, De Boer P. Non-union of the femoral diaphysis: the influence of reaming and non-steroidal anti-inflammatory drugs. J Bone Joint Surg Br 2000;82:655–8.
[17] Klemm KW. Treatment of infected pseudarthrosis of the femur and tibia with an interlocking nail. Clin Orthop 1986;212:174–81.
[18] Reichert IL, McCarthy ID, Hughes SP. The acute vascular response to intramedullary reaming: microsphere estimation of blood flow in the intact ovine tibia. J Bone Joint Surg Br 1995;77:490–3.
[19] Franklin JL, Winquist RA, Benirschke SK, Hansen Jr ST. Broken intramedullary nails. J Bone Joint Surg Am 1988;70:1463–71.
[20] Whittle AP, Wester W, Russell TA. Fatigue failure in small diameter tibial nails. Clin Orthop 1995;315:119–28.
[21] Brewster NT, Ashcroft GP, Scotland TR. Extraction of broken intramedullary nails—an improvement in technique. Injury 1995;26:286.