

## Safety of Total Contact Casting in High-Risk Patients with Neuropathic Foot Ulcers

Dane K. Wukich, M.D.\* John Motko, R.N., C.W.C.N.  
Quakertown, Pennsylvania

### ABSTRACT

**Background:** Total contact casting (TCC) is effective in offloading the plantar aspect of the foot in patients with diabetes and neuropathic ulcers. These patients are considered at high risk for skin-related complications during TCC because of sensory neuropathy. The purpose of this prospective study was to determine the frequency of complications during treatment of neuropathic ulcers with TCC. **Methods:** Thirteen patients with 18 neuropathic ulcers were treated with TCC. The same orthopaedic surgeon applied a consecutive series of 82 total contact casts. The initial cast was changed in 3 to 4 days, while subsequent casts were changed weekly. **Results:** Fourteen complications occurred during the 82 castings (17%). None of the complications required alteration in the treatment protocol. Thirteen of the 14 complications involved skin irritation and the other complication was from a cast that became too tight. Fifteen of the 18 neuropathic ulcers healed with TCC. **Conclusions:** TCC can be used safely in high-risk patients with neuropathic problems, but minor complications should be anticipated. Major complications that interfere with the treatment of the plantar ulcer can be minimized with careful technique, close follow-up, and thorough patient education.

**Key Words:** Complications; Neuropathy; Total Contact Casting; Ulcer

### INTRODUCTION

Foot and ankle complications are the most common reasons for diabetes-related hospital admissions.<sup>4,12,13</sup>

Chief, Division of Foot and Ankle Surgery, Department of Orthopaedic Surgery, University of Pittsburgh Medical Center, Pittsburgh, Pennsylvania

Corresponding Author:  
John Motko, M.D.  
St. Luke's Quakertown Hospital  
Advanced Wound Therapies  
1021 Park Avenue  
Quakertown, PA 18951  
E-mail: motkoj@slhn.org

For information on prices and availability of reprints call 410-494-4994 X226.

A study of patients with diabetes in a general medical clinic demonstrated that 23% of the total hospital days were secondary to diabetic foot problems.<sup>16</sup> An estimated 15% of all patients with diabetes will develop a foot ulcer during their lifetime,<sup>16</sup> and once an ulcer develops, the risk of an amputation increases by a factor of eight.<sup>6,12</sup>

At our wound care center, closed-toe total contact casting (TCC) has been used extensively in the management of neuropathic foot ulcers. Healing rates and the biomechanical considerations that cause offloading of the plantar surface of the foot have been well described, as has the technique of application of the casts.<sup>3,5,10,14,15,18</sup> Pollo et al.,<sup>11</sup> however, noted that TCC is not entirely free of risks and complications. Levine and Myerson<sup>8</sup> noted that most complications were minor and included new ulcerations, pre-tibial ulcerations, fungal infections, and abscess formation.

The purpose of this study was to prospectively evaluate the frequency of complications resulting from TCC in high-risk patients with neuropathic plantar ulcers.

### MATERIALS AND METHODS

Thirteen patients (eight men and five women) with neuropathic foot ulcerations, ranging in age from 39 to 76 years, were included in this study (Table 1). Informed consent for treatment was obtained from all patients during the initial visit.

Eleven of the 13 patients had neuropathy secondary to diabetes mellitus, and two patients had undiagnosed sensory neuropathies. All 13 patients had lost protective sensation in the foot, evidenced by their inability to perceive the 5.07 Semmes-Weinstein monofilament.<sup>2</sup> Seven of the 13 patients had previous ipsilateral partial foot amputations. The Wagner<sup>17</sup> classification was used to stage the ulcerations<sup>5,10</sup> (Table 2). The two non diabetic ulcerations also were graded using this classification, although Wagner's original description applied

**Table 1:** Patient demographics

Patient	Age/Gender	Wagner Classification at Presentation	Location of Ulcer	Number of Casts	Previous Amputation
1	63/Female	Grade 3	Midfoot	9	Left hallux, 2 <sup>nd</sup> toe
2	57/Female	Grade 3	Hindfoot	7	None
3	60/Female	Grade 2	Forefoot, 3 <sup>rd</sup> toe	6	None
4	57/Male	Grade 2	Forefoot, 1 <sup>st</sup> MTJ	7	Left hallux
5	57/Male	Grade 2	Midfoot	2	Right 3 <sup>rd</sup> and 5 <sup>th</sup> toes
6A	76/Female	Grade 2	Forefoot	4	None
6B		Grade 3	Hindfoot	5	None
7	39/Male	Grade 2	Forefoot	2	Left hallux
8A	47/Male	Grade 2	Forefoot (L)	3	Left hallux, 2 <sup>nd</sup> and 3 <sup>rd</sup> toes
8B		Grade 2	Forefoot (R)	5	TMA
8C		Grade 2	Forefoot (R) <sup>a</sup>	6	TMA
9A	58/Female	Grade 1	Forefoot	2	None
9B		Postoperative		7	Left hallux
10A	53/Male	Grade 2	Forefoot	7	None
10B		Grade 1	Forefoot	3	None
11	39/Male	Grade 3	Forefoot	3	None
12	55/Male	Grade 2	Plantar	2	Left hallux, 2 <sup>nd</sup> and 3 <sup>rd</sup> toes
13	62/Male	Grade 1	Forefoot	2	None

<sup>a</sup>Recurrence

**Table 2:** Classification By Wagner<sup>17</sup> Scale

<b>Grade 0</b> –At-risk area on the foot
<b>Grade 1</b> –Open, but superficial ulceration
<b>Grade 2</b> –Full-thickness ulceration without an abscess or osteomyelitis
<b>Grade 3</b> –Deep abscess or osteomyelitis
<b>Grade 4</b> –Gangrene involving a portion of the forefoot
<b>Grade 5</b> –Extensive gangrene of the entire foot


to diabetic ulcers only. At the time of presentation, four (patients 1, 2, 6, 11) of the 13 patients had ulcers that were classified as Wagner grade 3 (osteomyelitis or a deep abscess). All four of these patients had definitive surgical debridement of grossly infected bone and soft tissue in the operating room. Postoperatively, all four received parenteral antibiotics for 2 to 6 weeks depending on whether or not osteomyelitis was present. With surgery and antibiotics, these four ulcers were converted from Wagner grade 3 to Wagner grade 2 (Table 2). At the initiation of TCC, 14 of the 18 wounds were classified as Wagner grade 2 and three were Wagner grade 1; the other one was the

patient who had protective TCC after metatarsophalangeal joint (MTPJ) disarticulation. Fourteen ulcers involved the forefoot, two the midfoot, and two the hindfoot.

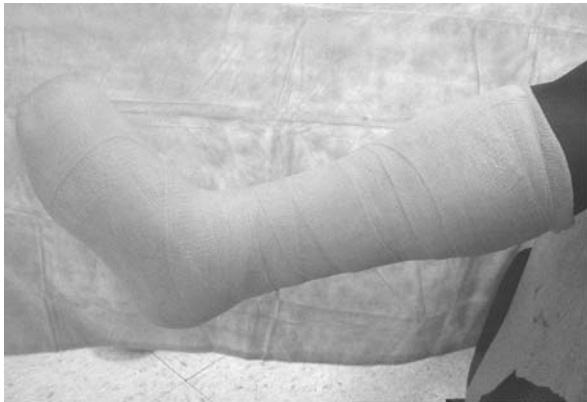#### Cast Application

Debridement and local wound care were used as necessary during the treatment phase. Eighty-two consecutive closed-toe total contact casts were applied between January 2002 and June, 2003. All 82 casts were applied by one orthopaedic surgeon (DKW), following the recommendations of Conti<sup>5</sup> and Levine and Myerson.<sup>8</sup>

A piece of 2 × 2-inch gauze was placed between the toes to decrease maceration. Cotton stockinette was applied from the toes to the knee and folded over at the toes. One half inch foam padding was placed over the forefoot, completely enclosing the toes. A single layer of cast padding was applied from the toes to the tibial tubercle, overlapping by 50%. Adhesive backed felt was applied in 1.5-inch-wide strips over the tibial crest from the tubercle to just above the ankle joint. Separate 2 × 2-inch felt pieces were applied over the medial and lateral malleoli (Fig. 1). Three- and four-inch fiberglass casting tape was applied to create the closed-toe total contact cast (Fig. 2). The longitudinal arch was carefully



**Fig. 1:** Medial view immediately before application of the fibreglass casting tape. The lateral malleolus is protected by a similar piece of felt.



**Fig. 2:** Completed closed-toe total contact cast.

molded, while the ankle was maintained in a neutral position, defined as the foot at 90 degrees to the long axis of the tibia. Before application of the cast shoe, the bottom of the cast was flattened by resting the plantar aspect of the cast on a step stool. Casting was done with the patient sitting, and after 10 to 15 minutes, full weightbearing was allowed in a cast boot. Patients were given instructions in cast care and told to call at any time if they had pain, irritation, or a sense that the cast was too tight or too loose. Patients were seen for a cast change 3 to 4 days after initial casting, and then they were followed weekly.

#### Treatment Periods and Complications

A treatment period was defined as the time from the application of the first cast until the ulcer healed or the casting was stopped for other reasons. Nine of the 13 patients had only one treatment period. One patient (patient 6A and 6B) had a forefoot ulcer that healed successfully, but a hindfoot ulcer developed 5 months later (two treatment periods).

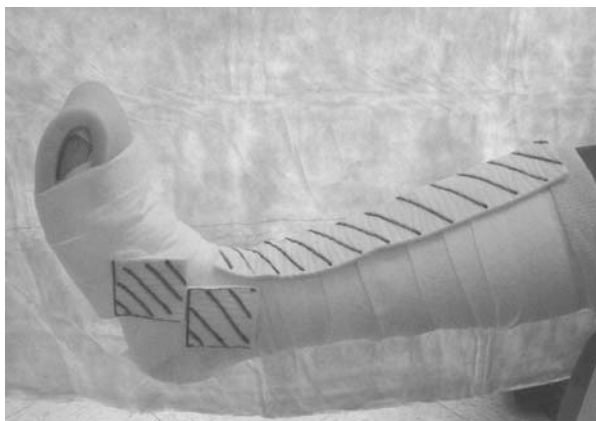
Another patient (patient 8A, 8B, and 8C) had bilateral ulcers that were treated separately. The ulcer on his right foot recurred, and he required a total of three treatment periods for healing of both feet. TCC was unsuccessful in one patient (patient 9A and 9B) who required disarticulation of the first MTPJ. Postoperatively, her surgical wound was protected with a total contact cast until it healed, resulting in a total of two treatment periods. Another patient (patient 10A and 10B) had successful treatment of a forefoot ulcer, but it recurred 1 month later and required repeat TCC (two treatment periods). Therefore, 82 closed-toe total contact casts were used in 18 treatment periods in 13 patients.

For the purposes of this study, a minor complication was defined as one that did not interfere with or require an alteration in TCC. A major complication was defined as one that caused an alteration in treatment (cessation of casting). Skin-related complications were graded according to pressure ulcer staging<sup>1</sup> since these iatrogenic lesions were a direct result of abnormal pressure created by TCC.

#### RESULTS

Fourteen minor complications occurred in 82 consecutively applied closed-toe total contact casts. No major complications occurred. Thirteen of the 14 complications were skin-related pressure ulcers. The other complication involved a cast that was perceived to be too tight by the patient, resulting in an earlier return visit and a cast change. No iatrogenic skin problem was caused by the cast being too tight.

The 13 skin-related complications included four stage I (nonblanching erythema of intact skin) and nine stage II (partial thickness skin loss) ulcers. No stage III (full thickness, damage to subcutaneous tissue) or stage IV (full thickness, damage to muscle, bone, tendon, joint capsule) ulcers occurred. Four pressure ulcers occurred in the hindfoot, four in the midfoot (over the medial aspect of the navicular), three over the tibial crest, and two at the second toe. It became apparent during the course of this study that the skin overlying the medial aspect of the navicular was a high-risk area for pressure-related complications. As a result of this, we modified our technique for the last 30 casts by applying a 2 × 2-inch piece of adhesive-backed felt to this region (Fig. 3). All four iatrogenic stage I ulcers occurred in areas that were protected by adhesive-backed felt (three over the tibial crest and one over the navicular after felt was added to this area). Seven stage II ulcers occurred in areas covered only with a single layer of stockinette and Webriil®. Half-inch foam padding was used to protect the two stage II toe ulcers. All 13 pressure ulcers



**Fig. 3:** Self-adhesive felt padding added over the navicular area to prevent pressure ulcers.

were covered with a biological dressing and healed uneventfully in the closed-toe total contact cast.

Fifteen of the 18 ulcers treated with TCC healed at a mean of 5.2 weeks (range, 2 to 10 weeks). Two patients (patients 7 and 11), each with one wound, were transferred to the care of another physician because of the relocation of the primary author (DKW). TCC was continued in these patients; however, the primary author did not apply the subsequent casts and these additional castings were not included in the series of 82 casts. One patient (patient 9A and 9B) required disarticulation at the great toe MTPJ after failure of TCC. In two of the 13 patients, the neuropathic ulcers healed but recurred 1 month and 2 months later. Both of these recurrent ulcerations healed with additional treatment periods of TCC. The mean number of casts applied during a treatment period was 4.6 (range, 2 to 9).

## DISCUSSION

Several studies have demonstrated the effectiveness of TCC in the treatment of neuropathic foot ulcerations.<sup>10,15,18</sup> The mechanism by which TCC promotes healing is multi-factorial. TCC increases the plantar surface weightbearing area, thus reducing plantar pressure in the forefoot and midfoot.<sup>3,5,7</sup> Shaw et al.<sup>14</sup> demonstrated that three other mechanisms play a role in decreasing plantar pressure: (1) increased load is transferred to the hindfoot, (2) one third of the total load is carried by the wall of the cast, and (3) the metatarsal heads are unloaded by the foam padding of the forefoot.

This consecutive series of 82 total contact cast applications in 13 high-risk neuropathic patients demonstrates that this technique can be used safely, with a minor complication rate of 17%. None of these 14 complications interfered with the treatment of the

primary ulcer, and all skin-related complications healed without difficulty. Our patients were considered high-risk because all had lost protective sensation and more than half (7 of 13 patients) had undergone ipsilateral partial foot amputations. Proper foot positioning is critical in providing appropriate load-bearing in the cast and preventing iatrogenic skin irritation.

The skin over the medial aspect of the navicular was a high-risk area: four of 14 complications occurred in this region. We minimized navicular irritation in our last 30 castings by applying a 2 × 2-inch piece of felt directly over the Webriil<sup>®</sup> in this area. In our first 52 cast applications, three stage II navicular wounds occurred, while in our last 30 only one stage I wound occurred. None of the four wounds (in four different patients) was associated with neuropathic arthropathy and collapse of the midfoot.

The hindfoot skin irritation (four of 14 complications) in this series was most likely due to alterations in hindfoot loading caused by TCC. Compared to shoe wear, TCC increases loading on the heel by 20% to 40%.<sup>7,14</sup> This increased load is transferred to an area (hindfoot) with relatively minimal padding. When the cast loosens, motion in the cast increases and shear pressure increases on the hindfoot. At our institution, total contact casts are changed weekly. Once drainage from the ulcer decreases and the fluctuation in edema stabilizes, the length of time between cast changes can be safely increased beyond 1 week at the discretion of the treating physician. The three stage I pressure ulcers over the tibial crest occurred in areas protected by adhesive felt. As the cast becomes loose, it loses its total contact effect and shear force increases in this area. Careful placement of the felt padding and frequent cast changes can minimize skin-related complications in this area.

The two forefoot complications occurred in the same patient and involved the tip of the second toe. This patient had multiple medical problems, including morbid obesity, insulin dependent diabetes mellitus, Charcot arthropathy, cardiac dysrhythmia, and chronic renal failure that required dialysis. He was prone to significant fluid shifts resulting in peripheral edema. His neuropathy caused him to have a classic fixed clawtoe deformity with hyperextended MTPJ and flexed distal interphalangeal joints (DIPJ). As a result of his flexed DIPJ, he developed a pressure ulcer on the tip of the toe despite the foam padding.<sup>8</sup> This ulcer healed but re-opened 2 months later during a second treatment period for a recurrent plantar ulcer. Careful padding of the forefoot is necessary in all neuropathic patients, especially in patients with clawtoe deformities.

The other complication involved a cast that became too tight. This patient (patient 3) was an otherwise healthy 60-year-old female with an undiagnosed

sensory neuropathy. She was not prone to developing edema. Her initial cast application was uneventful and the cast was changed 3 days after application. She was scheduled to return in 1 week, but 4 days after the second cast was applied, she returned complaining that the cast was too tight. Removal of the cast provided immediate relief of her symptoms. A new cast was applied that day and she had no problems with her final four casts. Although we included this as a minor complication, it actually portrays an educated patient who returned promptly rather than waiting an additional 3 days for her regularly scheduled appointment. No skin complication occurred. This illustrates the importance of thorough patient education.

This study and others have demonstrated that TCC is effective in healing neuropathic ulcers of the foot approximately 80% of the time.<sup>10,15,18</sup> This technique also can be used safely after surgery in patients with sensory neuropathy. We used TCC to protect a postoperative wound after disarticulation of the great toe MTPJ. In another patient who had percutaneous lengthening of the Achilles tendon while being treated for a plantar ulcer, the total contact cast served dual purposes by offloading the forefoot ulcer while maintaining the correction obtained by the Achilles tendon lengthening. Lin et al.<sup>9</sup> also reported success with this technique.

The use of fiberglass casting tape was well tolerated and allowed our patients to bear weight immediately. Maintaining balance in these neuropathic patients is critical because their proprioception may be altered. Our experience is similar to others in that plaster of Paris does not offer an advantage over fiberglass casting tape.<sup>5,7</sup>

## CONCLUSIONS

This study demonstrates that with careful cast application, close follow up, and thorough patient education, TCC can be used safely in high-risk patients with neuropathic foot ulcerations. Minor complications can be anticipated in approximately 17% of patients, and patients should be advised of this at the start of care. We did not encounter any complications involving the removal of the cast as noted by Conti<sup>5</sup> and Levine and Myerson.<sup>8</sup> We recognized this as a potential problem, and great care was taken during cast removal to prevent iatrogenic lacerations or burns. We also did not encounter any fungal infections or deep abscess, as has been noted by others.<sup>10,15</sup> During the course of this study, our technique of cast application was

modified as a result of the skin irritation that developed overlying the navicular. Applying additional felt padding in this region minimized soft tissue irritation at this site.

## REFERENCES

1. **Bergstrom, N; Bennett, MA; Carlson, CE:** Treatment of pressure ulcers. Agency of Healthcare Policy and Research Publication Number 95-0652: 1994.
2. **Birke, JA; Sims, DS:** Plantar sensory threshold in the ulcerated foot. *Lepr. Rev.* **57**:261, 1986.
3. **Birke, JA; Sims, DS; Buford, WL:** Walking cast: effects on plantar foot pressures. *J. Rehabil. Res. Dev.* **22**:18-22, 1985.
4. **Brodsky, JW:** The diabetic foot. In RA Mann, MJ Coughlin, eds, *Surgery of the Foot and Ankle*, St. Louis, MO, Mosby, 1993, p. 877.
5. **Conti, SF:** Total contact casting. *Instr. Course Lect.* **48**:305-315, 1998
6. **Ferris, LR; Pinzur, MS; Weinfeld, SB:** Ankle and foot reconstruction. In KR Koval, ed, *Orthopaedic Knowledge Update 7*, Rosemont, IL, American Academy of Orthopaedic Surgeons, 2002, pp. 572-575.
7. **Hartzell, HD; Fellner, C; Saltman, CL:** Pneumatic bracing and total contact casting have equivocal effects on plantar pressure relief. *Foot Ankle Int.* **22**:502-506, 2001.
8. **Levine, SE; Myerson, MS:** Management of ulceration and infection in the diabetic foot. In MS Myerson, ed, *Foot and Ankle Disorders*, Philadelphia, WB Saunders, 2000, pp. 411-438.
9. **Lin, SS; Lee, TH; Wapner, KL:** Plantar forefoot ulcerations with equinus deformity of the ankle in diabetic patients: the effect of tendo-Achilles lengthening and total contact casting. *Orthopaedics* **19**:465-475, 1996.
10. **Myerson, MS; Papa, J; Eaton, K:** The total contact cast for management of neuropathic plantar ulceration of the foot. *J. Bone Joint Surg.* **74-A**: 261-269. 1992.
11. **Pollo, FE; Brodsky, JW; Crenshaw, SJ; Kirksey, C:** Plantar pressures in fiberglass total contact cast vs. a new diabetic walking boot. *Foot Ankle Int.* **24**: 45-49, 2003.
12. **Priekorn, DB:** The insensate foot. In MS Mizel, RA Miller, MW Scioli, eds, *OKU Foot and Ankle 2*, Rosemont, IL, American Academy of Orthopaedic Surgeons, 1998, pp. 113-121.
13. **Reiber, GE:** Diabetic foot care. Financial implications and practice guidelines. *Diabetic Care* **15 (Suppl. 1)**:29, 1992.
14. **Shaw, JE; His, WL; Ulbrecht, JS; Norkitis, A; Becker, MB; Cavanagh, PR:** The mechanism of plantar unloading in total contact casts: Implication for design and clinical use. *Foot Ankle Int.* **18**:809-817, 1997.
15. **Sinacore, DR:** Total contact casting for diabetic foot ulcers. *Phys. Ther.* **76**:296-301, 1996.
16. **Smith, DM; Weinberger, M; Katz, BP:** A controlled trial to increase office visits and reduce hospitalizations of diabetic patients. *J. Gen. Intern. Med.* **2**:232, 1987.
17. **Wagner, FW:** Management of the diabetic neuropathic foot: A classification and treatment program for diabetic neuropathic, and dysvascular foot problems. *Instr. Course Lect.* **28**:143-165, 1979.
18. **Walker, SC; Helm, DA; Pullman, G:** Total contact casting and chronic diabetic neuropathic foot ulcerations: Healing rates by wound location. *Arch. Phys. Med. Rehabil.* **68**:217-221, 1987.