CLINICAL ORTHOPAEDICS AND RELATED RESEARCH
Number 440, pp. 96–100

Flexion Instability Without Dislocation after Posterior Stabilized Total Knees

Joseph H. Schwab, MD; George J. Haidukewych, MD; Arlen D. Hanssen, MD; David J. Jacofsky, MD; and Mark W. Pagnano, MD

Flexion instability after cruciate-retaining total knee arthroplasty has been well documented. We identified an analogous patient group with symptomatic flexion instability without dislocation after primary posterior stabilized total knee arthroplasty. We sought to determine the typical symptoms and exam findings that lead to the diagnosis, to assess the reliability of revision total knee arthroplasty as a treatment, and to assess the technical difficulties encountered during revision total knee arthroplasty. Between 1995 and 2001, 10 patients had revision of a well-fixed posterior stabilized total knee arthroplasty for isolated symptomatic flexion instability. The typical constellation of symptoms and physical findings included a sense of instability without giving way, recurrent knee effusions, multiple areas of soft tissue tenderness about the knee, and substantial anterior tibial translation at 90° of flexion. The revision operation focused on balancing the flexion and extension gaps while taking care to fill the enlarged flexion gap. Revision total knee arthroplasty was reliable in alleviating pain (mean Knee Society Pain scores improved from 68 points preoperatively to 89 points postoperatively), improving stability (nine of 10 patients had < 5 mm anterior tibial translation postoperatively) and improving patient satisfaction (nine of 10 patients were satisfied). We had no particular technical difficulties with the revision total knee arthroplasty procedures and had reliably achieved well-balanced flexion and extension gaps.

Level of Evidence: Therapeutic study, Level IV-1 (case series). See the Guidelines for Authors for a complete description of levels of evidence.

From the Mayo Clinic, Rochester, MN.
Each of the authors certifies that he has or may receive payments or benefits from a commercial entity related to this work.
Each author certifies that his or her institution has approved the human protocol for this investigation and that all investigations were conducted in conformity with ethical principles of research and that informed consent was obtained.
Correspondence to: Mark W. Pagnano, MD, Mayo Clinic, 200 First Street SW, Rochester, MN 55905. Phone: 507-284-5276; Fax: 507-284-5539; E-mail: pagnano.mark@mayo.edu.
DOI: 10.1097/01.blo.0000185449.51246.d6

Flexion instability has been documented as a cause of pain and poor results after cruciate-retaining total knee arthroplasty (TKA).[11,13] In those patients, the TKA is well-aligned and well-fixed but patients are plagued by recurrent knee joint effusions, a vague sense of instability, and multiple areas of anterior soft tissue tenderness. On physical examination, the patient with flexion instability after a cruciate-retaining TKA will have marked anteroposterior (AP) translation of the tibia, particularly at 90° of flexion, and may have frank posterior sag of the tibia. For patients who are sufficiently symptomatic, revision to a posterior-stabilized TKA with careful balancing of the flexion and extension gaps has proved a reliable and reproducible treatment for flexion instability after cruciate-retaining TKA.[11,13]

In the primary posterior-stabilized TKA, authors of previous reports of flexion instability have focused on the occasional problem of frank dislocation.[3,5,6,8,9,10,12] Although dramatic and disconcerting to patient and surgeon alike, the prevalence of frank dislocation with contemporary posterior-stabilized knee designs is low. Most current posterior-stabilized designs have increased the so-called jump distance that is needed for the cam to ride over the post before dislocating.[9] With contemporary posterior-stabilized implants, it is possible a flexion gap could be loose enough to allow substantial anterior tibial translation and instability, much like an anterior-cruciate-ligament–deficient knee, but that same knee does not translate posteriorly or dislocate because of the posterior-stabilized cam-post design.

Our purpose in doing this report was to (1) delineate the typical constellation of symptoms and physical findings in these patients; (2) assess the reliability of revision TKA for these patients as measured by patient satisfaction, by changes in the Knee Society pain and function scores, and by the elimination of objective and subjective instability; and (3) assess the technical difficulties associated with revision TKA in these patients as measured by the prevalence of complications.

MATERIALS AND METHODS

Through our total joint registry database we identified 10 patients who had revision surgery for symptomatic flexion instability after a primary posterior-stabilized TKA between 1995 and 2002. Each patient's medical record subsequently was reviewed. The diagnosis of flexion instability was made on the basis of a combination of each patient's symptoms and physical findings. Among the frequently reported symptoms was a vague sense of instability without frank giving way, recurrent knee joint swelling, recurrent anterior knee pain, and difficulty ascending and descending stairs attributed to weakness or instability and not to pain. None of the patients had experienced a dislocation. Among the frequently elicited physical findings were substantial anterior translation of the tibia at 90° of flexion (graded as mild < 5 mm, moderate 5–10 mm, or marked > 10 mm), knee joint effusion, and multiple areas of soft tissue tenderness including the pes anserine region, the peripatellar soft tissues, and the hamstring tendons. Only those patients who were revised for isolated symptomatic flexion instability in the AP plane were included in this study. Patients revised for varus and/or valgus instability, multiplanar instability, infection, polyethylene (PE) wear, or aseptic component loosening were excluded. Each component of these cemented, posterior-stabilized TKAs was well-fixed, based on preoperative radiographs and intraoperative confirmation. A preoperative infection workup, including complete blood count, sedimentation rate, and C-reactive protein was negative in all patients. Intraoperatively, there was no acute inflammation on frozen section pathology and no growth from multiple intraoperative culture specimens. Institutional Review Board approval and informed consent were obtained for this retrospective review.

There were eight men and two women with a mean age of 67 years (range, 51–79 years). All of the patients had an index diagnosis of osteoarthritis. The average time from primary TKA to revision TKA was 27 months (range, 8–59 months). In eight of 10 patients, the tibial and femoral components were revised. Although the tibial components in each of those eight patients were well fixed, revising the femur and tibia allowed each surgeon to use the revision total knee prosthesis system with which they were most comfortable. In seven of those eight revisions, a larger femoral component with posterior augments was implanted in an effort to fill the large flexion space. Short cemented stems were used in each of those seven cases on the femoral and tibial sides In each of those seven patients a nonhinged but more constrained tibial PE insert was used. In four patients, the surgeon chose a so-called posterior-stabilized plus tibial PE insert to implant (DePuy/Johnson and Johnson, Warsaw, IN). The posterior-stabilized plus tibial insert is wider in the medial-lateral plane, providing more varus-valgus constraint, but is not taller than the standard posterior-stabilized insert so no improvement in AP stability would be expected with that insert. In the other three patients, a constrained condylar tibial PE insert was used. For the one patient having a revision procedure not having a larger femoral component used, 6 mm of additional distal femoral bone was resected to enlarge the extension space. That femoral component was inserted with a short cemented stem. A thicker standard posterior-stabilized PE insert then was implanted and that effectively balanced the flexion and extension gaps (Fig 1). In two patients, an isolated tibial PE exchange was done. In both of those patients, an extensive release of the posterior capsule was combined with a thicker tibial insert in the effort to balance the flexion and extension spaces. One patient lacked 8° of extension intraoperatively after the isolated exchange of the tibial PE. Given the significant medical comorbidities and low functional demands of that patient, this was deemed acceptable in lieu of complete revision of well-fixed components.

Patients were followed up to revision, death, or for a minimum of 24 months with a mean followup of 40 months (range, 24–85 months). The clinical results were evaluated using the criteria of the Knee Society and with a patient satisfaction question that asked whether patients were markedly better, better, the same, or worse after their revision TKA.[4,7] Patients also were asked whether their specific symptoms of instability were markedly better, better, the same, or worse after their revision TKA procedures.

RESULTS

The typical constellation of symptoms in these patients with flexion instability without frank dislocation after primary posterior-stabilized TKA included a sense of instability without giving way (eight of 10 patients), substantial difficulty ascending or descending stairs (seven of 10 patients), recurrent knee joint swelling (seven of 10 patients), and diffuse anterior knee pain or tenderness (seven of 10 patients). The typical constellation of physical findings included substantial anterior translation of the tibia as measured at 90° flexion in all 10 patients, eight with marked translation and two with moderate translation; multiple areas of soft tissue tenderness, including the

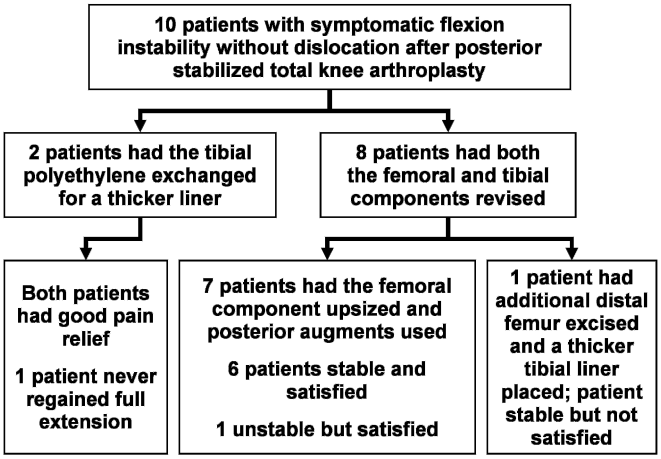

Fig 1. A flowchart summarizing the outcomes of 10 patients treated with revision surgery for symptomatic flexion instability after posterior stabilized TKA is shown.

pes anserine region (seven of 10 patients), the peripatellar region (six of 10 patients), and the posterior hamstring tendons medially and laterally (five of 10 patients); and palpable knee joint effusion (six of 10 patients). On the lateral radiograph the posterior slope of the tibial component measured a mean of 7° (range 3°–11°).

Revision TKA typically was reliable in alleviating pain and eliminating flexion instability in these patients without frank dislocation after posterior-stabilized TKA. Nine of the 10 patients had a marked improvement in their Knee Society pain score after revision. The mean Knee Society score improved ($p = 0.009$) from 68 points (range, 55–86 points) preoperatively to 89 points (range, 75–97 points) postoperatively. The one patient without an improvement in pain subsequently was diagnosed with reflex sympathetic dystrophy. The Knee Society function scores did not change after the revision. The average Knee Society function score was 62 points preoperatively (range, 45–80 points) and 61 points postoperatively (range, 25–90 points). Nine of 10 patients were satisfied with the results of their revision TKA, with eight patients stating that they were markedly better, one patient stating he was better, and one patient stating he was worse. Nine of 10 patients stated that the revision TKA markedly improved their knee stability, and one patient felt the stability was unchanged. Clinical measurement of stability showed that nine of 10 patients had postoperative anterior translation of less than 5 mm and one patient with 5 to 10 mm of anterior translation.

There were no particular technical difficulties with any of these 10 revision TKA procedures. In all but one patient, excellent intraoperative balance of the flexion and extension gaps was obtained. In one patient where an isolated tibial PE exchange was used, the extension space was overstuffed relative to the flexion space. That patient lacked 8° of extension intraoperatively and that extension loss persisted postoperatively. The one patient in this series with a poor result developed reflex sympathetic dystrophy that has subsequently responded moderately to a comprehensive pain management protocol. No other complications were encountered. There have been no subsequent revisions or reoperations in this group. The typical patient lost a slight amount of flexion after their revision TKA for flexion instability. Before their revision procedures, patients had an average knee flexion of 115° (range, 95°–125°) whereas postrevision flexion declined slightly to an average of 110° (range, 105°–120°).

DISCUSSION

The diagnosis and treatment of symptomatic flexion instability after cruciate-retaining TKA has been well described. Revision TKA with a focus on careful balancing of the flexion and extension gaps has proved to be reliable and reproducible in alleviating pain and improving stability in the patient with flexion instability after cruciate-retaining TKA.[11,13] We found an analogous set of patients in our practice with flexion instability without dislocation after primary posterior-stabilized TKA who had symptoms sufficient enough to warrant revision TKA. In this report we sought to (1) delineate the typical constellation of symptoms and physical findings; (2) assess the reliability of revision TKA as measured by patient satisfaction, by changes in the Knee Society pain and function scores, and by the elimination of objective and subjective instability; and (3) assess the technical difficulties associated with revision TKA as measured by the prevalence of complications.

The limitations of the current study include its retrospective nature and the multiple surgeons and implants studied. Additionally, we were unable to determine the prevalence of flexion instability symptomatic enough to warrant revision because of the referral nature of our practice. Although we report on 10 patients symptomatic enough to require revision, we are unable to determine the number of patients from which this series was distilled. For perspective, during the time period of the current study, 1370 revision TKAs were done at our institution, of which only 10 (0.7%) were for isolated symptomatic flexion instability of a posterior-stabilized TKA. The limitations of the current study do not undermine its more important findings; namely, that flexion instability is a potential cause of pain in a well-fixed, well-aligned, and noninfected posterior-stabilized TKA. Examining the knee in 90° of flexion should become part of the routine physical examination of any painful TKA whether it is of a cruciate-retaining, cruciate-sacrificing, or cruciate-substituting design. Revision TKA with careful attention to filling the flexion space usually with a larger femoral component and posterior modular metal augmentation predictably improved pain and stability in this group of patients with symptomatic flexion instability without dislocation after posterior-stabilized TKA.

The typical patient with flexion instability after posterior-stabilized TKA presented with a constellation of symptoms and physical findings similar to those reported with flexion instability after cruciate-retaining TKA.[2,11,13] Many patients complained of a sense of instability without frank giving way and reported difficulty ascending and descending stairs. They had recurrent knee effusions, which in many cases had been aspirated on one or more occasions before the diagnosis of flexion instability. The patients had diffuse tenderness, especially at the site of tendinous attachments. Examination of the knee in 90° of flexion, particularly with the patient seated and their foot planted on the ground, was the most effective way to show

the instability. Excessive anterior translation, especially if it reproduced symptoms, was indicative of flexion instability.

The findings of this study—that well-aligned and well-fixed posterior-stabilized TKAs can be symptomatically unstable in flexion without exhibiting frank dislocation—reaffirms the need to carefully balance the flexion and extension spaces of the knee at the time of primary arthroplasty. Although some patients may tolerate a large flexion space, provided the total knee replacement prosthesis does not dislocate, this study identified a subgroup of patients who do not tolerate that extra laxity in flexion. In this setting, it is appropriate to make an analogy to the shoulder, in which the physical finding of laxity is differentiated from the clinical diagnosis of instability, which includes the combination of symptoms with the physical finding of laxity. Clearly, the isolated physical finding of excessive anterior laxity in a well-functioning, asymptomatic posterior-stabilized TKA is not an indication for revision surgery. Likewise, many patients we have seen have had pain and symptoms because of flexion instability that was not severe enough to warrant surgery. In the posterior-stabilized knee, care should be taken not to introduce excessive posterior tibial slope or to overresect the posterior femoral condyles because each of those actions would increase the flexion space. A large or loose flexion space can allow the tibia to sublux and produce instability with or without dislocation. Most, but not all, posterior-stabilized total knee prostheses are designed to be implanted with little posterior tibial slope and surgeons should pay close attention to the design and technique parameters of the total knee system that they use and avoid adding additional posterior tibial slope at the time of surgery.

In the current study, improvements in the Knee Society Pain Scores and patient satisfaction with the revision operation were reliably and reproducibly obtained in patients with flexion instability. Our results are similar to those of other authors who have studied patients after revision TKA surgery for flexion instability after cruciate-retaining TKA.[11,13] Revision to a posterior stabilized TKA with careful balancing of the flexion and extension gaps markedly improved six of six patients with flexion instability after cruciate-retaining TKA in one of those studies and 19 of 22 patients in the other study.[11,13] The improvement in the knee scores in the current study largely was because of pain relief. We think knee pain in patients with flexion instability is a direct result of the AP instability. The instability causes excessive strain on the soft tissues surrounding the knee (eg, retinacula and tendinous insertion sites) that work to dynamically stabilize the knee. All patients our series showed improved stability, and concomitantly, the majority of patients had pain relief. However, Knee Society Function Scores did not improve after the revision. The lack of improvement in knee function scores likely is caused by many things. Three of the patients with poor functional scores had significant comorbidities unrelated to their knees that contributed to their poor functional score. One patient had poor function because of pain in the opposite knee. Because of the small number of patients in the current study, drawing definitive conclusions is difficult. Most importantly, however, the majority of patients was satisfied with the results of the revision TKA, despite the lack of improvement in the average Knee Society Function Scores.

During revision TKA for flexion instability it is critical to reconstitute the flexion space. This commonly necessitates the use of posterior femoral augmentation combined with a larger femoral component to fill the flexion gap. With the modular wedges and augments available in contemporary TKA revision prosthesis systems, obtaining good balance of the flexion and extension spaces by upsizing the femoral component was possible consistently. Alternatively, when remaining distal femoral bone stock allows, additional bone can be resected and a larger tibial PE insert can be used to achieve flexion and extension gap balance, as was done in one of the cases in this series. When perfect matching of the flexion and extension spaces is not possible it is our preference to fill the flexion space in these patients with flexion instability. It is our goal in these patients to have fewer than 5 mm of anterior translation of the tibia when the knee is tested at 90° of flexion with the patella reduced in the femoral trochlea. Two of our patients with flexion instability were treated with isolated tibial PE exchange, but we do not recommend it as a routine treatment option. That technique effectively fills the flexion space at the expense of overstuffing the extension space. One of our patients could not regain full extension intraoperatively or postoperatively as a result of overstuffing in extension in order to fill the flexion space. In addition, isolated tibial PE insert exchange has not proved reliable in addressing flexion instability in cruciate-retaining TKA.[1,11] And in another study, isolated tibial insert exchange was a less predictable procedure than was complete revision for those patients with an unstable TKA, and the authors have little enthusiasm for this technique.[2]

References

1. Babis GC, Trousdale RT, Morrey BF: The effectiveness of isolated tibial insert exchange in revision total knee arthroplasty. J Bone Joint Surg 82A:64–68, 2002.
2. Brooks DH, Fehring TK, Griffin WL, Mason JB, McCoy TH: Polyethylene exchange only for prosthetic knee instability. Clin Orthop Relat Res 405:182–188, 2002.
3. Colizza WA, Insall JN, Scuderi GR: The posterior stabilized total knee prosthesis: Assessment of polyethylene damage and osteolysis after a ten-year-minimum follow-up. J Bone Joint Surg 77A:1713–1720, 1995.

4. Ewald FC: The Knee Society total knee arthroplasty roentgenographic evaluation and scoring system. Clin Orthop Relat Res 248:9–12, 1989.
5. Galinat BJ, Vernace JV, Booth Jr RE, Rothman RH: Dislocation of the posterior stabilized total knee arthroplasty: A report of two cases. J Arthroplasty 3:363–367, 1988.
6. Gebhard JS, Kilgus DJ: Dislocation of a posterior stabilized total knee prosthesis: A report of two cases. Clin Orthop Relat Res 254: 225–229, 1990.
7. Insall JN, Dorr LD, Scott RD, Scott WN: Rationale of the Knee Society clinical rating system. Clin Orthop Rel Res 248:13–14, 1989.
8. Insall JN, Lachiewicz PF, Burstein AH: The posterior stabilized condylar prosthesis: A modification of the total condylar design. Two to four-year clinical experience. J Bone Joint Surg 64A:1317–1323, 1982.
9. Kocmond JH, Delp SL, Stern SH: Stability and range of motion of Insall-Burstein condylar prostheses: A computer simulation study. J Arthroplasty 10:383–388, 1995.
10. Lombardi Jr AV, Mallory TH, Vaughn BK, et al: Dislocation following primary posterior-stabilized total knee arthroplasty. J Arthroplasty 8:633–639, 1993.
11. Pagnano MW, Hanssen AD, Lewallen DG, Stuart MJ: Flexion Instability after primary posterior cruciate retaining total knee arthroplasty. Clin Orthop Relat Res 356:39–46, 1998.
12. Sharkey PF, Hozack WJ, Booth Jr RE, Balderston RA, Rothman RH: Posterior dislocation of total knee arthroplasty. Clin Orthop Relat Res 278:128–133, 1992.
13. Waslewski GL, Marson BM, Benjamin JB: Early, incapacitating instability of posterior-cruciate ligament retaining total knee arthroplasty. J Arthroplasty 7:763–767, 1998.