

See discussions, stats, and author profiles for this publication at: <https://www.researchgate.net/publication/264829030>

# The human meniscus: A review of anatomy, function, injury, and advances in treatment: The Meniscus: Anatomy, Function, Injury and Treatment

Article in *Clinical Anatomy* · August 2014

DOI: 10.1002/ca.22456

CITATIONS

40

READS

6,228

5 authors, including:



Alice JS Fox

22 PUBLICATIONS 1,164 CITATIONS

SEE PROFILE



Florian Wanivenhaus

Uniklinik Balgrist

21 PUBLICATIONS 235 CITATIONS

SEE PROFILE



Russell F Warren

Hospital for Special Surgery

655 PUBLICATIONS 34,247 CITATIONS

SEE PROFILE



Scott A Rodeo

Hospital for Special Surgery

201 PUBLICATIONS 7,248 CITATIONS

SEE PROFILE

Some of the authors of this publication are also working on these related projects:



impingement [View project](#)



meniscus repair [View project](#)

## REVIEW

# The Human Meniscus: A Review of Anatomy, Function, Injury, and Advances in Treatment

ALICE J.S. FOX,<sup>1\*</sup> FLORIAN WANIVENHAUS,<sup>2</sup> ALISSA J. BURGE,<sup>3</sup>  
RUSSELL F. WARREN,<sup>1</sup> AND SCOTT A. RODEO<sup>1</sup>

<sup>1</sup>Laboratory for Soft Tissue Research, Hospital for Special Surgery, 535 East 70th Street, New York, New York

<sup>2</sup>Department of Orthopaedics, Balgrist University Hospital, Forchstrasse 340, Zurich, Switzerland

<sup>3</sup>Department of Radiology, Hospital for Special Surgery, 535 East 70th Street, New York, New York

Meniscal injuries are recognized as a cause of significant musculoskeletal morbidity. The menisci are vital for the normal function and long-term health of the knee joint. The purpose of this review is to provide current knowledge regarding the anatomy and biomechanical functions of the menisci, incidence, injury patterns and the advancements in treatment options of meniscal injury. A literature search was performed by a review of PubMed, Google Scholar, MEDLINE, and OVID for all relevant articles published between 1897 and 2014. This study highlights the anatomical and biomechanical characteristics of the menisci, which may be relevant to injury patterns and treatment options. An understanding of the normal anatomy and biomechanical functions of the knee menisci is a necessary prerequisite to understanding pathologies associated with the knee. Clin. Anat. 00:000–000, 2014. © 2014 Wiley Periodicals, Inc.

**Key words:** meniscus; menisci; knee; anatomy; biomechanics; injury; treatment

## INTRODUCTION

Originally described as a vestigial structure (Sutton, 1897), the menisci are now known to be vital for the normal functioning and longevity of the knee joint (Fairbank, 1948; Burr and Radin, 1982; Arnoczky et al., 1988; Arnoczky, 1992; Spilker et al., 1992; Roos et al., 1998, 2001; Rodkey, 2000; McDermott and Amis, 2006). The primary function of the meniscus is to transmit load across the tibiofemoral joint by increasing congruency, thereby decreasing the resultant stress placed on the articular cartilage. The menisci also play a secondary role in shock absorption, stability, lubrication, nutrition, and proprioception to the knee joint (Kettelkamp and Jacobs, 1972; Seedhom, 1976; Seedhom and Hargreaves, 1979; Ahmed and Burke, 1983; Mow et al., 2005; McDermott et al., 2008; Chevrier et al., 2009; Englund et al., 2009).

Injuries to the menisci are recognized as a cause of significant musculoskeletal morbidity (Fox et al., 2012; Rath and Richmond, 2000). As a consequence of its complex anatomical, biomechanical, and functional characteristics, the menisci are prone to damage and injury, particularly in contact-sport activities

but also in sedentary young or elderly patients. The challenge remains to develop therapies and techniques that will preserve the menisci's distinct composition and function.

## ANATOMY

### Meniscal Etymology

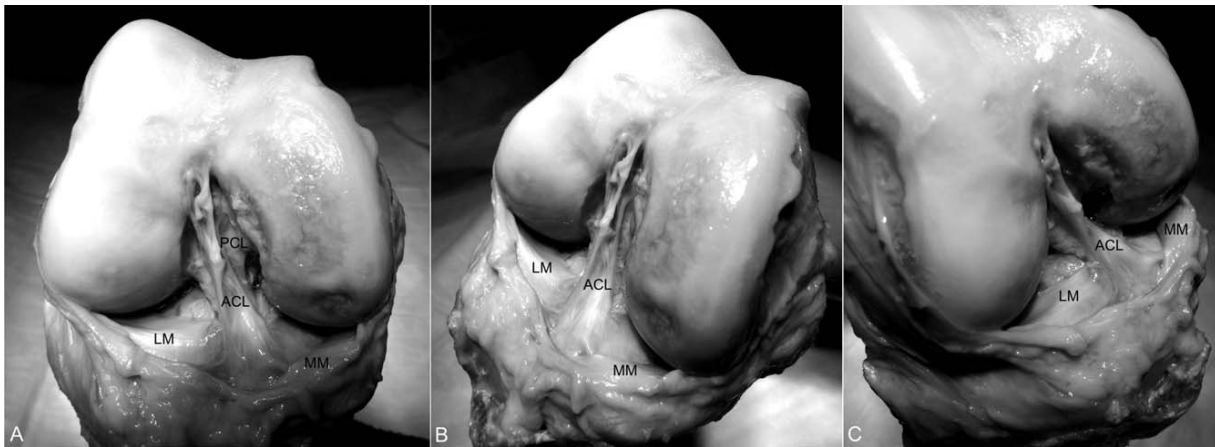
The Latin word *meniscus* comes from the Greek word *mēniskos*, meaning "crescent," diminutive of *mēnē*, meaning "moon" (Fox et al., 2012).

\*Correspondence to: A.J.S. Fox, MSc, Laboratory of Soft Tissue Research, 535 East 70th Street, New York, NY 10021. Email: foxa@hss.edu or ajsfox27@hotmail.com

Conflict of interest: Russell F. Warren, MD: Biomet (royalty) and Ivy Sports (stock). Scott A. Rodeo, MD: Smith and Nephew (consultant).

Received 22 May 2014; Accepted 23 July 2014

Published online in Wiley Online Library (wileyonlinelibrary.com). DOI: 10.1002/ca.22456



**Fig. 1.** Photographs of a right knee joint from a 64-year-old woman. **(A)** Anterior view. **(B)** View toward lateral aspect. **(C)** View toward the medial aspect. LM, lateral meniscus; ACL, anterior cruciate ligament; PCL, posterior cruciate ligament; MM, medial meniscus.

### Meniscal Phylogeny and Comparative Anatomy

Many species, including all tetrapods, share a genetic lineage reflected by the similar anatomic and functional characteristics and asymmetries of the knee which can be traced back more than 300 million years (Haines, 1942; Mossman and Sargeant, 1983; Dye, 2003). Approximately 1.3 million years ago, the modern patellofemoral joint was established as hominids evolved to a bipedal stance (Tardieu and Dupont, 2001). Tardieu analyzed the ontogenetic transition from occasional bipedalism to habitual bipedalism. The author observed that primates contain a medial and lateral fibrocartilaginous meniscus, with the medial meniscus being morphologically similar in all primates (crescent shaped with two tibial insertions) and the lateral meniscus being more variable in shape (Tardieu, 1999). Unique to *Homo sapiens* is the presence of two tibial insertions—one anterior and one posterior—indicating the permanent practice of full extension movements of the knee joint during the stance and swing phases of bipedal walking (Retterer, 1907; Vallois, 1914; Ricklin et al., 1983; Preuschoft and Tardieu, 1996; Tardieu, 1999; Beaufils and Verdonk, 2010).

### Embryology and Development

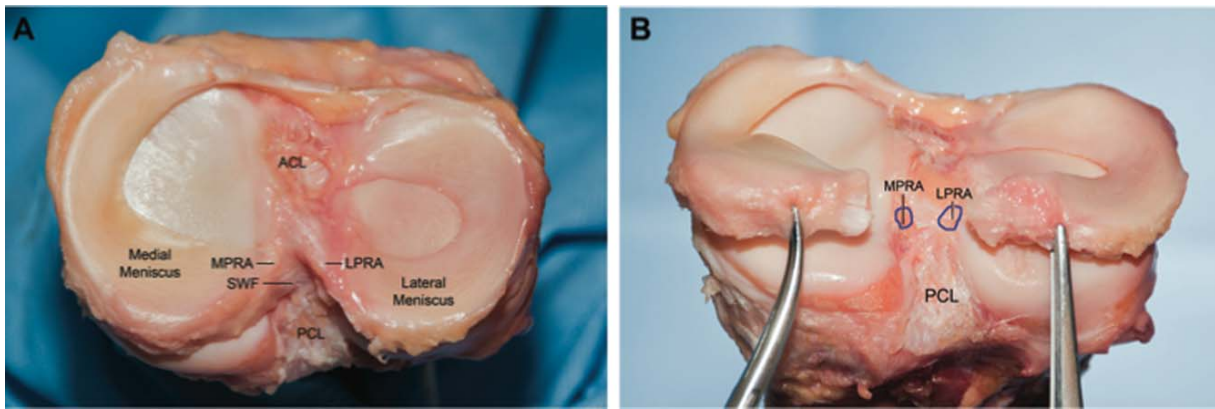
The menisci arise from a condensation of the intermediate layer of mesenchymal tissue surrounding the joint capsule. The characteristic shape of the lateral and medial menisci is achieved between the 8th and 10th week of gestation (Gardner and O’Rahilly, 1968; Gray, 1999). The developing menisci are highly cellular and vascular, with a blood supply extending the entire width and length of the menisci (Clark and Ogden, 1983). As the fetus continues to develop, there is an increase in collagen content in a circumferential

arrangement with a concomitant decrease in cellularity (Clark and Ogden, 1983; Carney and Muir, 1988). Weight-bearing and joint motion during development are important factors in determining the orientation of the collagen fibers. By adulthood, only the peripheral 10 to 30% are vascular (Clark and Ogden, 1983).

Despite these histological changes, the proportion of tibial plateau covered by the corresponding fetal development, with the medial and lateral menisci covering approximately 51–74% and 75–93% of the surface areas, respectively (Seedhom, 1976; Clark and Ogden, 1983; Fukazawa et al., 2009).

### Gross Anatomy

The menisci are crescent shaped wedges of fibrocartilage located on the medial and lateral aspects of the knee (Figs. 1–3). The menisci enable effective articulation between the concave femoral condyles and the relatively flat tibial plateau. The menisci are roughly triangular in cross section, covering one-half to two-thirds of the articular surface of the corresponding tibial plateau. Meniscal horns anchor the menisci to the underlying subchondral bone of the tibial plateau (Messner and Gao, 1998; Villegas et al., 2008) (Fig. 3). These ligamentous structures transmit shear and tensile load from soft tissue into the bone and decreasing contact area (Messner and Gao, 1998). In the medial meniscus, the anterior horn can have a variable site of attachment, into either soft tissue of bone, but a firm bony attachment to the flat intercondylar region of the tibial plateau is most common (Berlet and Fowler, 1998). The posterior horn attaches to the tibia just anterior to the insertion site of the posterior cruciate ligament (PCL) (McKeon et al., 2009; Palastanga and Soames, 2011). In the lateral meniscus, the anterior horn inserts on the tibia in front of the intercondylar eminence, just posterior



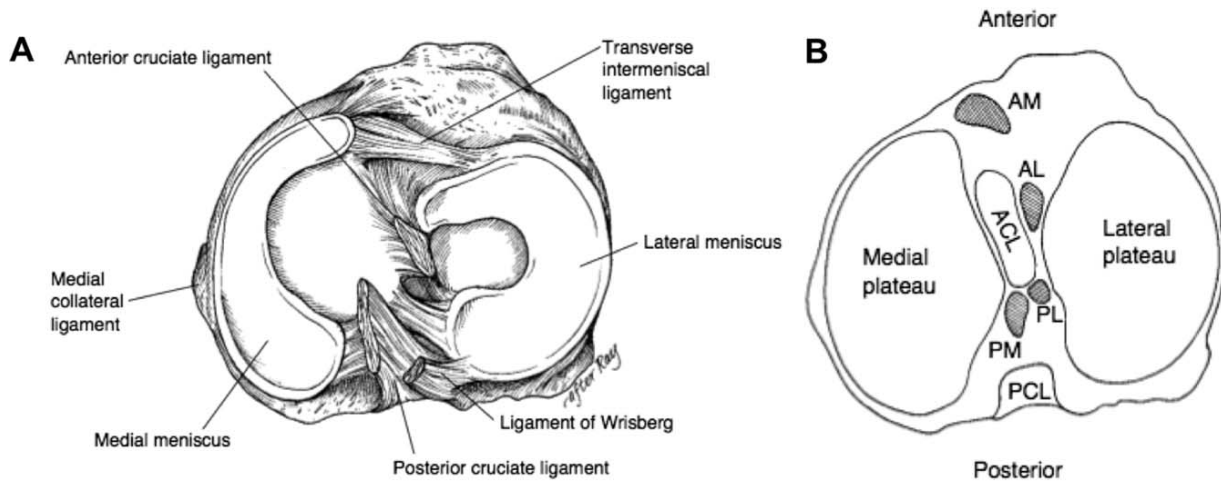
**Fig. 2.** Anatomical photographs of tibial plateau demonstrating the relative size and attachments of the medial and lateral menisci. **(A)** Superior view. **(B)** Posterior view. ACL, anterior cruciate ligament; LPRA, lateral meniscus posterior horn attachment; MPRA, medial meniscus posterior horn attachment; PCL, posterior cru-

ciate ligament; SWF, shiny white fibers of posterior horn of medial meniscus. (Reproduced with permission from Johannsen AM, Civitaresse DM, Padalecki JR, Goldsmith MT, Wijdicks CA, LaPrade RF. *Am J Sports Med*, 2012, 40, 2342–2347). [Color figure can be viewed in the online issue, which is available at [wileyonlinelibrary.com](http://wileyonlinelibrary.com).]

and lateral to the anterior cruciate ligament (ACL) insertion. The posterior horn attaches to the tibia in between the insertion sites of the PCL and the posterior horn of the medial meniscus (Fig. 3) (McKeon et al., 2009). The outer rim of the menisci (also called the red zone) is thick and convex and attached to the knee joint capsule while the inner edge (also called the white zone) is concave, thin and unattached (Fig. 4) (Rath and Richmond, 2000).

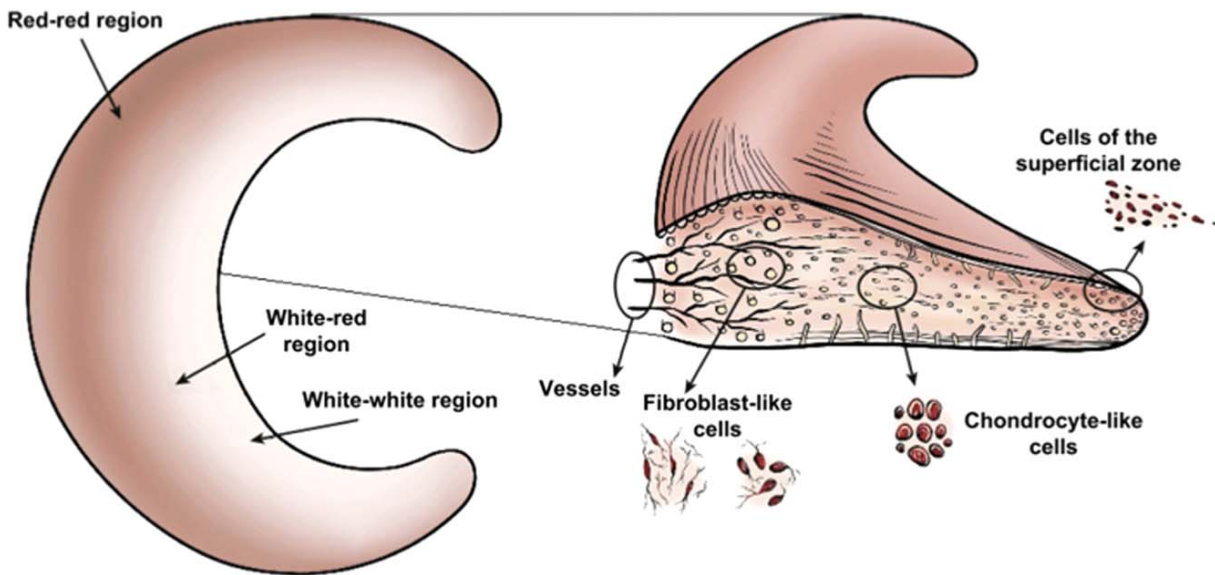
### Medial Meniscus

The medial meniscus is C-shaped and occupies ~60% of the articular contact area of the medial compartment (Figs. 1, 2, and 3A) (Clark and Ogden, 1983; Arnoczky et al., 1987; Thompson et al., 1991). Its posterior horn is significantly wider than the anterior horn, and the anteroposterior dimension is larger than the mediolateral dimension. The anterior horn is



**Fig. 3.** **(A)** Anatomy of the meniscus viewed from above (adapted image reprinted with permission from Greis PE, Bardana DD, Holmstrom MC, Burks RT. *J Am Acad Orthop Surg*. 2002, 10, 168–176; original from Pagnani MJ, Warren RF, Arnoczky SP, Wickiewicz T. *The Lower Extremity and Spine in Sports Medicine*. 1995, p 581–614, © Mosby. **(B)** Axial view of a right tibial plateau

showing sections of the meniscus and their relationship to the cruciate ligaments. AL, anterior horn lateral meniscus; AM, anterior horn medial meniscus; PCL, posterior cruciate ligament; PL, posterior horn lateral meniscus; PM, posterior horn medial meniscus. (Reproduced with permission from Johnson RJ, Kettelkamp DB, Clark W, Leaverton P. *J Bone Joint Surg Am*, 1974, 56, 719–729).



**Fig. 4.** Anatomical variation in vascularization and cell population of the meniscus. (Reproduced with permission from Makris EA, Hadidi P, Athanasiou KA. *Biomaterials*, 2011, 32,7411–7431). [Color figure can be viewed in the online issue, which is available at [wileyonlinelibrary.com](http://wileyonlinelibrary.com).]

firmly attached to the tibia anterior to the ACL, near the intercondylar fossa. The posterior horn is attached immediately anterior to the attachment of the medial meniscus (Figs. 2 and 3). The peripheral border of the medial meniscus merges with the knee joint capsule. The coronary ligament attaches to the meniscus to the upper tibia (Rath and Richmond, 2000).

### Lateral Meniscus

The lateral meniscus is almost uniformly circular and in contrast to the medial meniscus, it is smaller and considerably more mobile (Figs. 2 and 3A). It also occupies a greater portion of the articular surface (~80% vs. ~60%) (Clark and Ogden, 1983; Arnoczky et al., 1987; Thompson et al., 1991). The anterior horn of the lateral meniscus is attached to the intercondylar fossa adjacent to the broad attachment site of the ACL. The posterior horn is attached to the PCL and medial femoral condyle through the menisocofemoral ligaments of Wrisberg (the posterior menisocofemoral ligament) and Humphrey (the anterior menisocofemoral ligament) (Fig. 3A). It is also attached to the popliteus tendon (Last, 1950).

### Biochemistry of the Meniscus

The meniscus is composed of a dense extracellular matrix (ECM) composed of primarily of water (72%) and collagen (22%), interposed with cells (Ghadially et al., 1983). Other constituents include glucosaminoglycans (17%), DNA (2%), adhesion glycoproteins (<1%), and elastin (<1%) (Herwig et al., 1984;

Makris et al., 2011). These proportions vary according to age, injury, or pathological condition (Sweigart and Athanasiou, 2001).

Collagen is the main fibrillar component of the meniscus and varies in amount depending on region within the meniscus. Collagens are primarily responsible for the tensile strength of the meniscus, contributing up to 75% of the dry weight of the ECM (Herwig et al., 1984). In the red zone, type I collagen is predominant (80% composition by dry weight), with other collagen variants (e.g., type II, III, IV, VI, and XVIII) present in less than 1%. Type I collagen fibers are oriented circumferentially, in the deeper layers of the meniscus, parallel to the peripheral border (Fig. 4). In the most superficial region of the menisci, type I fibers are oriented in a more radial orientation. Radially positioned "tie" fibers are also present in the deep zone and woven between the circumferential fibers to provide structural integrity (Bullough et al., 1970; Yasui, 1978; Aspden et al., 1985; Beaupre et al., 1986; Arnoczky et al., 1988; Fithian et al., 1990; Skaags and Mow, 1990; Fox et al., 2012). In the white zone, collagen (70% by dry weight) is composed of only two types of collagen - types II (60%) and I (40%) (Cheung, 1987). The collagen fibers are heavily cross-linked and are ideal for transferring vertical compressive load into "hoop stresses" (Voloshin and Wosk, 1983).

Classification of meniscal cells is controversial, with no uniform characterization accepted in the literature (Nakata et al., 2001). Histological examination of the inner white zone of the menisci reveals rounded cells, that behave similarly to fibrochondrocytes or chondrocyte-like cells (Fig. 4) (Verdonk et al., 2005).



**Fig. 5.** Frontal section of medial compartment. Branching radial vessels from the perimeniscal capillary plexus (PCP) can be observed penetrating the peripheral border of the medial meniscus. Three zones are seen: (1) RR, red-red area is fully vascularized; (2) RW, is at the border of the vascular area; and (3) WW, white—white is within the avascular area of the meniscus. F, femur; T, tibia; PCP, perimeniscal capillary plexus. R, red. Original image reprinted with permission from (Arnoczky SP, Warren RF. *Am J Sports Med*, 1982, 10, 90–95); adapted image reprinted with permission from (Canale ST, Beatty JH. *Campbell's Operative Orthopaedics*, 2013, Elsevier). [Color figure can be viewed in the online issue, which is available at [wileyonlinelibrary.com](http://wileyonlinelibrary.com).]

In contrast, the cells of the outer red zone have an oval or fusiform appearance and are classified as fibroblasts (Fig. 4) (Verdonk et al., 2005). A third cell population has been identified in the superficial zone of the meniscus. These cells are flattened and fusiform and lack cell extensions (Van der Bracht et al., 2007). Although the exact purpose of these cells is unknown, it has been suggested that they might be specific progenitor cells with a regenerative capacity (Van der Bracht et al., 2007).

### Vascular Anatomy

The meniscus is a relatively avascular structure with a limited peripheral blood supply. Branches of the popliteal artery (medial and lateral inferior and middle geniculate arteries) are the major blood vessels that nourish each meniscus. Radial branches from a perimeniscal plexus enter the meniscus at intervals, with a richer supply to the anterior and posterior horns (Fig. 5) (Day et al., 1985). Vascularization is limited to the peripheral 10–25% for the lateral meniscus and 10–30% for the medial meniscus, which has important implications for healing (Arnoczky and Warren, 1982; Danzig et al., 1983; Harner et al., 2000). Endoligamentous vessels from the anterior and posterior horns travel a short distance into the substance of the menisci to form terminal loops, providing a direct route for nourishment (Danzig et al., 1983). The remainder of the meniscus receives nourishment via synovial diffusion or mechanical motion (Meyers et al., 1988).

### Neuroanatomy

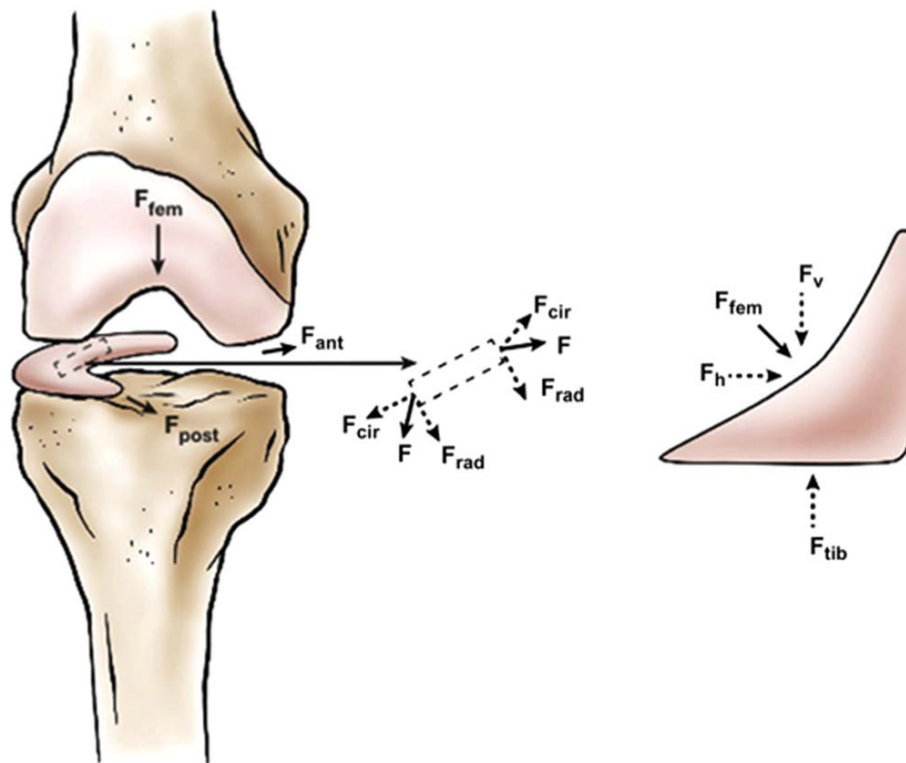
The meniscus receives innervation via the recurrent peroneal branch of the common peroneal nerve. These fibers follow the blood supply and are found primarily in the peripheral vascular zone covering the outer third of the meniscus (Gardner, 1948; Kennedy et al., 1982). Three distinct mechanoreceptors—Ruffini endings (type 1), Pacinian (type II) and Golgi tendon organs (type III)—have been identified within the meniscus. These neural elements are found in greater concentration in the meniscal horns (particularly the posterior horn), and are important in joint deformation and pressure, tension changes, and neuromuscular inhibition, respectively (Zimny, 1988). Free nerve endings (nociceptors) can be found in the horns and the outer two-thirds of the body of the menisci (Wilson et al., 1969; Day et al., 1985; Gronblad et al., 1985; Zimny, 1988; Zimny et al., 1988; Assimakopoulos et al., 1992; Mine et al., 2000).

### BIOMECHANICS AND FUNCTION

The complex functions of the meniscus are intricately related to their composition, structure, and morphology. The menisci perform many important biomechanical functions. These functions include load transmission (Fairbank, 1948; Walker and Erkman, 1975; Seedhom, 1976; Seedhom and Hargreaves, 1979; Fukubayashi and Kurosawa, 1980; Aspden et al., 1985; Arnoczky et al., 1987), shock absorption (Krause et al., 1976; Kurosawa et al., 1980; Voloshin and Wosk, 1983; Arnoczky et al., 1987; Fithian et al., 1990), stability (Markolf et al., 1976; Fukubayashi et al., 1982; Levy et al., 1982, 1989; Shoemaker and Markolf, 1986;), nutrition (Bird and Sweet, 1987, 1988; Renstrom and Johnson, 1990), joint lubrication (Macconail, 1932; Mac, 1946, 1950; Renstrom and Johnson, 1990), and proprioception (Wilson et al., 1969; Zimny et al., 1988; Assimakopoulos et al., 1992; Jerosch et al., 1996; Messner and Gao, 1998; Saygi et al., 2005; Akgun et al., 2008; Karahan et al., 2010). They also serve to decrease contact stresses and increase contact area and congruency of the knee (Kettelkamp and Jacobs, 1972; Walker and Erkman, 1975).

### Load Transmission

Studies with long-term follow-up of meniscectomized knees have shown the importance of the meniscus in the functioning of the knee. Fairbank was first to describe the direct load-bearing function of the meniscus by describing the degenerative changes in meniscectomized knees (Fairbank, 1948). Fairbank described narrowing of the joint space, flattening of the femoral condyle, and the formation of osteophytes. Fairbank attributed these changes to the loss of the meniscus (Fairbank, 1948). Since then, several animal and clinical studies have confirmed Fairbank's thesis that the meniscus is an important protective, load-bearing structure (Walker and Erkman, 1975; Levy et al., 1989; Newman et al., 1989; Fukuda et al.,



**Fig. 6.** Free body diagram of forces acting on the knee meniscus during loading. During normal loading, the meniscus is compressed by the downward force of the femur. The meniscus deforms radially but is anchored by its anterior and posterior horns ( $F_{ant}$  and  $F_{post}$ ). During loading, tensile, compressive, and shear forces are generated. A tensile hoop stress ( $F_{cir}$ ) results from radial deformation,

while vertical and horizontal forces ( $F_v$  and  $F_h$ ) result from the femur compressing the curved superior surface of the tissue. A radial reaction force ( $F_{rad}$ ) balances the femoral horizontal force ( $F_h$ ). (Reproduced with permission from Makris EA, Hadidi P, Athanasiou KA. *Biomaterials*, 2011, 32,7411–7431). [Color figure can be viewed in the online issue, which is available at [wileyonlinelibrary.com](http://wileyonlinelibrary.com).]

2000; Lee et al., 2006; Bedi et al., 2010, 2012, 2013; Beveridge et al., 2011; Ode et al., 2012; Mononen et al., 2013; Dong et al., 2014).

Biomechanical studies have demonstrated that approximately 40–60% of load acting on the extended knee joint is transmitted to the meniscus (65–70% lateral and 40–50% medial) (Shrive et al., 1978; Dudhia et al., 2004). In flexion, this increases up to 90% (Walker and Erkman, 1975). During weight bearing, axial forces compress the menisci, resulting in “hoop” (circumferential) stresses (Voloshin and Wosk, 1983). Hoop stresses rely on the conversion of axial force into tensile strain through the circumferential collagen fibers of the meniscus (Fig. 6). The lateral meniscus is displaced more than the medial meniscus during compression, but because of the semilunar anatomy, load is transmitted away from the center of the femoral condyles resulting in tensile stress toward the tibial plateau (Sweigart and Athanasiou, 2001). When standing, the meniscus absorbs most of the load; however, when the knee is in gait or stair climbing, variations in contact stresses occur (Walker and Erkman, 1975; Gilbert et al., 2013). A recent cadaveric study by Gilbert et al. found that during gait, peak

contact stresses of the medial plateau occurred in areas of cartilage–cartilage contact, while on the lateral meniscus peak contact stresses occurred under the meniscus (Gilbert et al., 2013). During stair climb, peak contact stresses of the medial meniscus were located in the posterior aspect of the plateau, under the meniscus. While in the lateral meniscus, during the late phase of stair climb, peak contact stresses were reported in the zone of cartilage–cartilage contact (Gilbert et al., 2013).

Several studies have demonstrated that load is well distributed when the meniscus is intact, however, its removal results in a significant reduction in femoral condyle contact area and a significant increase in contact stress (Kettelkamp and Jacobs, 1972; Fukubayashi and Kurosawa, 1980; Ahmed and Burke, 1983; Radin et al., 1984; Radin and Rose, 1986; Bedi et al., 2012). Several studies have reported that total lateral meniscectomy results in a 40–50% decrease in contact area and an increase in contact stress in the lateral component (200–300% of what is considered normal), which significantly increases the load per unit area and may contribute to accelerated articular cartilage damage and degeneration (Fairbank, 1948;

Kettelkamp and Jacobs, 1972; Walker and Erkman, 1975; Jones et al., 1978; Fukubayashi and Kurosawa, 1980; Baratz et al., 1986; Henning et al., 1987).

### Shock Absorption

The shock absorbing capacity of the menisci has been demonstrated by studies measuring the vibrations in the proximal tibia resulting from gait. From this, it has been shown that shock absorption is approximately 20% less in knees without menisci (Voloshin and Wosk, 1983). This function of the menisci is associated with their viscoelastic properties, the main component of which is the water content of the tissue. Therefore, on impact, shock is absorbed by frictional drag forces, which occur as the fluid escapes the tissue.

### Stability

The incongruous articulation between the convex femoral condyles and flat tibial plateau is ameliorated by the concave-shaped superior surface of each meniscus (Brantigan and Voshell, 1941; Markolf et al., 1976, 1981; Oretorp et al., 1979; Fukubayashi et al., 1982; Levy et al., 1982; Shoemaker and Markolf, 1986; Allen et al., 2000). The firm attachment of the medial meniscus to the tibia contributes to anterior stability of the knee, and is more frequently torn (particularly in ACL-deficient knees) because it is less mobile.

The intact meniscus limits excess motion in all directions, contributing to the stability of the knee joint (Arnoczky, 1992). Although the exact function of the menisiofemoral ligaments (Wrisberg and Humphrey) remains unknown, it is believed that in flexion and internal rotation, the popliteal tendon retracts the posterior horn, thus reducing entrapment of the lateral meniscus between the femur and tibia. Joint stability is further facilitated by the soft tissue structures of the knee joint capsule.

The role that the menisci play in joint stability can best be demonstrated in studies investigating laxity in ACL-deficient, meniscectomized or meniscus-torn knees (Levy et al., 1982; Shoemaker and Markolf, 1986). Findings include greater anterior tibial translation in knees with a sectioned ACL and medial meniscectomy as compared with knees with only ACL sectioning (Bargar et al., 1980). However, ACL sectioning and lateral meniscectomy did not cause an increase in anterior translation in contrast to medial meniscectomy (Levy et al., 1982). Shoemaker and Markolf stated that the posterior horn of the medial meniscus is the most important structure resisting anterior tibial force in the ACL-deficient knee (Shoemaker and Markolf, 1986). Allen et al. showed that the resultant force in the medial meniscus of the ACL-deficient knee increased by 52% in full extension and by 197% at 60 degrees of flexion under a 134-N anterior tibial load (Allen et al., 2000). More recently, Musahl et al. reported that the lateral meniscus plays a major role in the pivot-shift maneuver as lateral meniscectomy increases translation and rotation and

increases the pivot shift (Musahl et al., 2010; Pearle, 2011). These significant changes in kinematics in the ACL-deficient knee confirm the important role of the menisci in knee stability.

### Joint Lubrication and Nutrition

The menisci may also play a role in the lubrication and nutrition of the knee joint. In a series of studies, MacConaill, reported that the coefficient of friction of the knee joint is increased by 20% following meniscectomy (Macconail, 1932; Mac, 1946, 1950). The precise mechanism(s) by which lubrication occurs remains unknown; however some authors believe that when the knee is loaded, the menisci compress and circulate synovial fluid into the articular cartilage, reducing the frictional forces during weight-bearing and providing joint nutrition (Mac, 1950; Arnoczky et al., 1988). The system of microcanals within the meniscus that is located close to the blood vessels communicates with the synovial cavity. It is believed that these may provide fluid transport for lubrication and nutrition (Bird and Sweet, 1987, 1988).

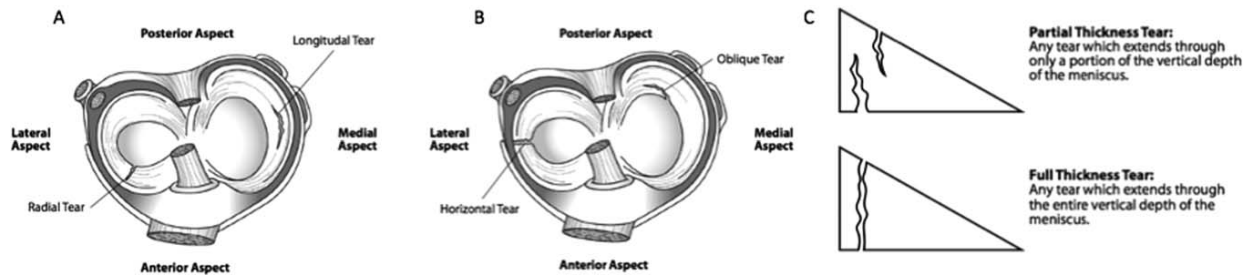
### Proprioception

The menisci may serve a proprioceptive role as suggested by the presence of mechanoreceptors in the anterior and posterior horns of the menisci (Wilson et al., 1969; Zimny et al., 1988; Assimakopoulos et al., 1992; Jerosch et al., 1996; Messner and Gao, 1998; Saygi et al., 2005; Akgun et al., 2008; Karahan et al., 2010). Quick-adapting mechanoreceptors (e.g., Pacinian corpuscles) are thought to mediate the sensation of joint motion, while slow-adapting receptors (e.g., Ruffini endings and Golgi tendon organs) are believed to mediate the sensation of joint position (Reider et al., 2003). The identification of these neural elements (located mostly in the middle and outer third of the meniscus) indicates that the meniscus is capable of detecting proprioceptive information, thus playing an important afferent role in the sensory feedback mechanism of the knee (Kennedy et al., 1982; Skinner et al., 1984; Aagaard and Verdonk, 1999; Gray, 1999; Karahan et al., 2010).

## INJURY

### Epidemiology

Meniscal injury is a common source of pain and disability of the knee that is frequently encountered by orthopaedic surgeons, with a mean annual incidence of 60–70 per 100,000 (Hede et al., 1990; Nielsen and Yde, 1991; Majewski et al., 2006; Clayton and Court-Brown, 2008). The overall male to female ratio for meniscal tears ranges from 2.5:1 to 4:1, with a peak incidence occurring in males between 21 and 30 years of age and in girls and women between 11- and 20-years old (Baker et al., 1985; Poehling et al., 1990; Greis et al., 2002; Drosos and Pozo, 2004). Medial meniscal tears (particularly in the stable knee or in the chronic ACL-deficient knee) are more common



**Fig. 7.** Common types of meniscal tears (**A** and **B**) and; (**C**) depth of meniscal tears. Image adapted and reprinted with permission from (Hauser RA, Philips HJ, Mad-dela HS. *J Prolother*, 2010, 2, 416–437).

than lateral tears (81 and 19%, respectively). Lateral meniscus tears are more common in association with an acute ACL tear (range, 51–72%) (Poehling et al., 1990).

Meniscal tears are generally caused by a combination of axial loading and rotational forces that result in shear load on the meniscus (Browner et al., 2003). Traumatic tears are usually associated with a known insult to the knee and may be isolated or associated with ligament or articular surface injury (Browner et al., 2003). Traumatic tears generally occur in younger, active individuals (Browner et al., 2003). Degenerative tears may reflect cumulative stress and correlate with the presence of associated chondromalacia (Browner et al., 2003).

Meniscal tears in children are commonly due to trauma or congenital meniscal variants such as a discoid meniscus or meniscal cysts. In adults, meniscal tears are a result of trauma, degenerative disease or a combination of both (Hirschmann and Friederich, 2009; Pujol and Boisrenoult, 2009; Verdonk and Vererfve, 2009). Adult meniscal injuries predominantly involve the medial meniscus, and are often associated with concomitant ligament or cartilage lesions (Pujol and Boisrenoult, 2009; Verdonk and Vererfve, 2009). In addition, tears are more complex in adults as the meniscus undergoes significant degeneration in the course of a lifetime (Pujol and Boisrenoult, 2009). Not surprisingly, there is an increase in the incidence of meniscal tears with increasing age (Pujol and Boisrenoult, 2009).

Symptoms produced by a meniscal tear are typically pain and sometimes mild swelling. Less commonly, “mechanical” symptoms such as locking, catching, grinding, and giving away occur. The frequency and severity of the symptoms varies according to the size and mobility of the meniscal tear (Browner et al., 2003).

## CLASSIFICATION OF MENISCAL TEARS

Despite the International Society of Arthroscopy, Knee Surgery and Orthopaedic Sports Medicine Committee publishing a standardized and validated system to classify meniscal tears, no classification has been

universally accepted by the orthopaedic community (Irrgang et al., 1998, 2006; Crawford et al., 2007; Anderson et al., 2011). Tears are generally classified according to observed tear patterns (seen at arthroscopy) or etiology of the injury and can be described as either full-thickness or partial thickness, depending on vertical depth of the tear (Figs. 7 and 8).

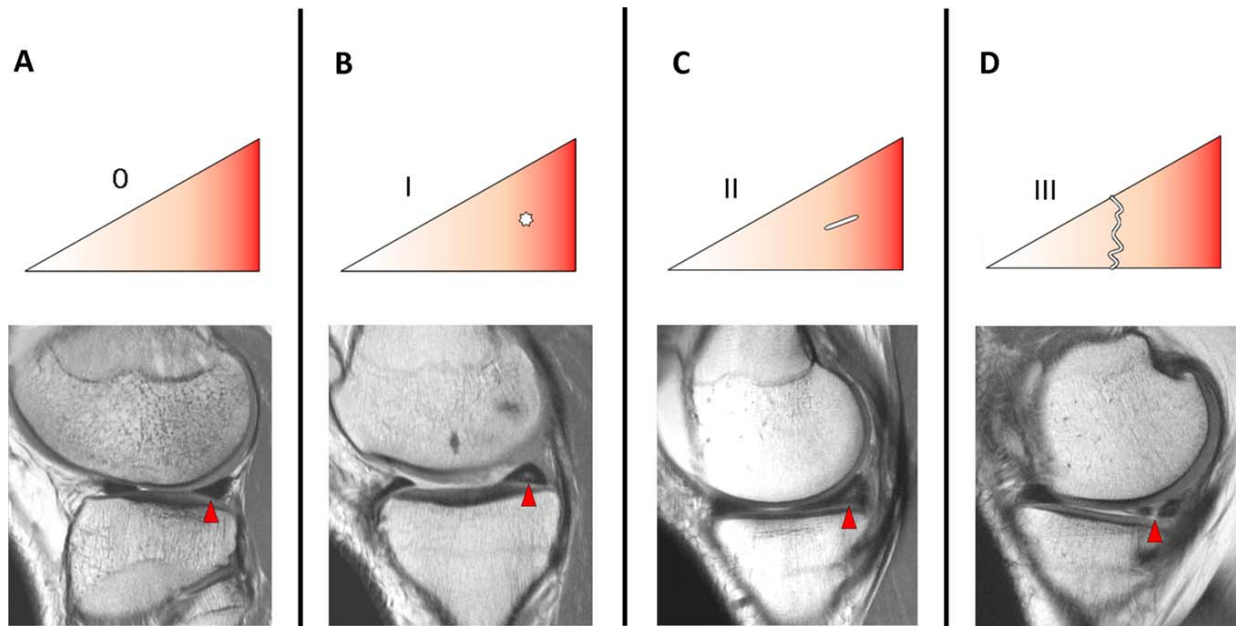
The authors follow the zone classification system devised by Cooper, who provides consistent clinical documentation of meniscal tear patterns and tear locations (Cooper et al., 1990). In this system, the menisci are divided into three radial zones anterior to posterior and four circumferential zones extending from the periphery to the inner aspect of the meniscus (Fig. 9). Tears are further classified according to their morphology and tear pattern relative to the tibial plateau.

The main categories of meniscal tears include vertical longitudinal, radial (transverse), horizontal (cleavage), complex (degenerative), and bucket-handle tears (Greis et al., 2002).

### Vertical Longitudinal Tears

A vertical longitudinal tear occurs between the circumferential collagen fibers, parallel to the long axis of the meniscus, perpendicular to the tibial plateau, with the tear equidistant from the peripheral edge of the meniscus (Jee et al., 2003). These tears transverse the circumferential collagen fibers, resulting in either two separate pieces of meniscus, or a single portion of meniscus attached to the tibia in only one location (Figs. 7A) (Tuckman et al., 1994; Magee et al., 2002; Fox, 2007).

Vertical longitudinal tears are most commonly traumatic in origin and occur more often in younger individuals, with a peak incidence of 21–30 years of age in men and 11–20 years of age in women (Schepesis and Busconi, 2006). They are noted more frequently medially in isolated cases and laterally in association with ACL tears (Schepesis and Busconi, 2006). The incidence of vertical longitudinal tears ranges from 40 to 84% (Metcalf, 1981; Poehling et al., 1990; Dandy, 1990; Metcalf and Barrett, 2004). As these tears occur between collagen fibers, the biomechanics of the knee is therefore not always disrupted and these



**Fig. 8.** Meniscal tear grading. The schematic diagrams on the top depict meniscal tear grades with corresponding sagittal MR images on the bottom. Grade 0, normal intact meniscus; Grade I, intrasubstance globular-appearing signal not extending to the articular surface; Grade II, linear increased signal patterns not

extending to the articular surface; Grade III, abnormal signal intersects the superior and/or inferior articular surface of the meniscus, an arthroscopically confirmable tear. Red arrows indicate tear location. [Color figure can be viewed in the online issue, which is available at [wileyonlinelibrary.com](http://wileyonlinelibrary.com).]

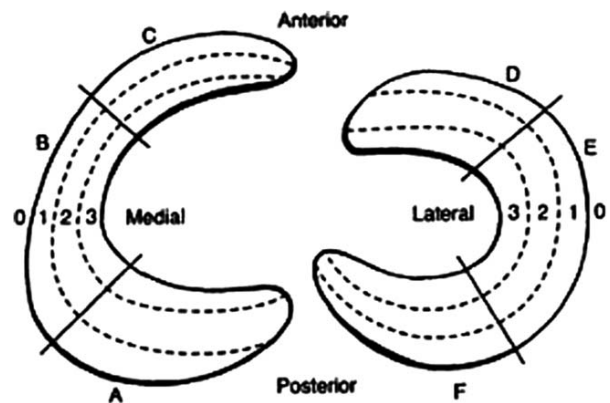
tears may not be symptomatic (Mordecai et al., 2014). Vertical longitudinal tears are commonly repaired because they are amenable to suture fixation.

periphery have the potential to heal because of the peripheral bloody supply (Schepsis and Busconi, 2006). Traditionally, repairs of radial tears were not

### Radial Tears

Radial (transverse) tears are vertical tears, which often occur at the junction of the posterior and middle thirds and extend from the inner free margin toward the periphery, but can occur at other regions (Figs. 7A). They may also occur in the midbody portion of the lateral meniscus in younger patients. The incidence of radial tears is approximately 14–15% (Helms, 2002; Magee et al., 2002; Harper et al., 2005). Radial tears are typically found in younger patients, with a peak incidence of 11–20 years of age in men and 51–70 years of age in women (Schepsis and Busconi, 2006). Although relatively uncommon, they are usually traumatic with the majority (~79%) occurring in the posterior horn of the meniscus (Helms, 2002; Magee et al., 2002; Harper et al., 2005; Fox, 2007). Radial tear patterns may be associated with ACL rupture involving the posterior portion or meniscal attachment (Wickiewicz, 1990; Vanhoenacker et al., 2007).

Radial tears disrupt the ability to distribute the hoop stresses associated with weight bearing, and are usually not reparable (Harper et al., 2005; Fox, 2007). Repairs of radial tears that extend to the



**Fig. 9.** Zone Classification of the Meniscus. Posterior third zone of the medial menisci is lettered A. Moving in a clockwise direction of thirds, the middle third zone is lettered B, and the anterior third zone is letter C, and so on. 0, meniscosynovial junction (the periphery); 1, is the outer third region of the menisci; 2, is the middle third region of the menisci; and 3 is the inner third region of the menisci. (Reproduced with permission from Schepsis AA, Busconi BD. Sports Medicine, 2006, Lippincott Williams & Wilkins).

recommended; however, more recent studies have indicated that, with more advances repair techniques, clinical success may be achieved after full-thickness radial tear repairs (particularly of the posterior horn of the lateral meniscus) (Wickiewicz, 1990; Schepsis and Busconi, 2006).

### Horizontal Tears

Horizontal (cleavage/longitudinal) tears are parallel to the tibial plateau, dividing the meniscus into inferior and superior segments (Figs. 7B) (Jee et al., 2003). Tears can not only extend to the articular surface of the meniscus in the region of the free margin (non-vascularized portion of meniscus), but also on the tibial and femoral side of the meniscus. These tears occur in all groups but are seen most frequently in older patients, with a peak incidence of 31–50 years in men and 51–60 years of age in women (Schepsis and Busconi, 2006). Horizontal tears occur most commonly in the posterior aspect of the medial meniscus. When this tear pattern is noted in the lateral meniscus, it may be associated with lateral meniscal cysts or osteoarthritis (Outerbridge, 1961; Aichroth, 1996; Philips, 2003; Schepsis and Busconi, 2006).

The mechanism of injury is thought to be secondary to shear forces between the superior and inferior surfaces of the meniscus that tend to cause separation of the upper and lower segments of the tear. Initial tears may be confined to the substance of the meniscus without meniscal surface communication (Schepsis and Busconi, 2006). Repeated traumatic episodes may result in an intrasubstance tear, which may extend to the articular surface or may occur in the horizontal plane (Schepsis and Busconi, 2006). Repeated applied load to a meniscal tear can result in tear propagation, fragment displacement, and edge instability. This can lead to mechanical symptoms such as locking and catching with increased pain and effusion. Excision of the unstable portions of the meniscus is performed as these tears are typically not repairable (Schepsis and Busconi, 2006).

### Complex (Degenerative) Tears

Complex tears either have two or more tear configurations or are not easily categorized into a specific type of tear (Jee et al., 2003; Fox, 2007). This is the most common of all meniscal lesions, accounting for nearly 30% of all tears with a peak incidence of 41–50 years of age in men and 61–70 years of age in women (Schepsis and Busconi, 2006). However, atraumatic degenerative flap tears have been identified by magnetic resonance imaging (MRI) and arthroscopy in patients as young as 20 years of age. Complex tears may or may not be associated with any history of trauma and may have an insidious onset. Complex degenerative tears are frequently seen in association with other degenerative changes within the joint. In addition, complex degenerative tears usually have minimal to no healing potential and generally are not amenable to repair (Schepsis and Busconi, 2006).

### Bucket-handle Tears

A bucket-handle tear of the meniscus is a vertical or oblique tear with longitudinal extension toward the anterior horn in which the inner fragment is frequently displaced toward the intercondylar notch (Singson et al., 1991). The term bucket-handle is derived from the appearance of the tear, in which the inner displacement fragment of the meniscus resembles a handle, and the peripheral nondisplaced portion has the appearance of a bucket (Singson et al., 1991). Bucket-handle tears often involve the entire meniscus but can also involve only the posterior horn and body or a single horn of the meniscus and are common in ACL deficient knees (Ruff et al., 1998). It is the most common type of displaced “flap” tear, occurring in approximately 10–26% of patients (Lecas et al., 2000; Watt et al., 2000; Ververidis et al., 2006) and more commonly involves the medial meniscus (Magee and Hinson, 1998; Watt et al., 2000; Dorsay and Helms, 2003; Ververidis et al., 2006). The inner flipped portion of the meniscus can remain intact or it can be disrupted.

### MECHANISM OF INJURY

The mechanism of injury of meniscal tears can be generally categorized as occurring during a sporting activity (e.g., soccer, rugby football), a nonsporting activity (e.g., squatting), or nonactivity. In a recent study of 392 patients from an unselected population, Drosos and Pozo found that only one-third (32.4%) of patients incurred their meniscal injury in a sports-related activity, while over one third (38.8%) occurred due to nonsporting activities and nearly one third (28.8%) of patients could not identify any specific event or incident which resulted in an injury (Drosos and Pozo, 2004).

Injury to the meniscus during sporting activities can be further defined as secondary to contact or noncontact mechanisms, with the latter being the most common. In the young athlete, contact (sports)-related meniscal tears may result from excessive application of force to the meniscus while in older patients, degeneration makes the meniscus particularly susceptible to injury. The mechanism of injury typically involves a twisting or shearing motion, with a varus or valgus force directed to a flexed knee (Hayes et al., 2000). Contact with another player typically does not occur, nor does lunging or landing awkwardly. Patients typically report taking a single “wrong step” (Vanhoenacker et al., 2007). In noncontact (sports)-related injuries, common mechanisms include cutting, decelerating or landing from a jump (Rath and Richmond, 2000).

Age has been suggested as a risk factor of meniscal injury. Drosos and Pozo found that the average age of the sporting, nonsporting and nonactivity groups was 33, 41, and 43 years, respectively (Drosos and Pozo, 2004). The differences may reflect a higher representation of the general population in recreational sports and of age-related degenerative changes within the meniscus, which make it more vulnerable to injury (Drosos and Pozo, 2004). These findings confirm the opinion of other authors, which state that after the

third decade of life, degenerative changes start to diminish the elasticity and increase the susceptibility of the meniscus to injury (Noble and Hamblen, 1975; Smillie, 1978).

Gender has also been suggested to be a risk factor for meniscal injury. Several studies have reported that men are four times more likely to incur a meniscal injury than women (Baker et al., 1985; Casteleyn et al., 1988; Drosos and Pozo, 2004). This may be due to the subtle anatomical and physiological characteristics of the meniscus, differences in normal daily activities, sports participation, prior participation in sports and differences in occupation, which can result in different rates of microtrauma and degeneration of the meniscus (Drosos and Pozo, 2004).

## IMAGING MODALITIES

### Standard Radiography

Although unable to demonstrate pathology of the meniscus, radiographs of the knee are able to exclude bony pathologies and assess the concomitant presence of degenerative changes. Standing weight-bearing radiographs (anteroposterior at 0°, posteroanterior at 45° ("Rosenberg view"), lateral, Merchant views) can show a reduction of the joint space width, loose bodies, chondrocalcinosis, osteophytes, subchondral bone cysts, sclerosis, and other degenerative changes (Rosenberg et al., 1988; Maffulli et al., 2010; Robinson, 2010).

### Magnetic Resonance Imaging

Magnetic Resonance Imaging is a valuable imaging method for diagnosing meniscal tears, with an accuracy range of 82–95% (Mandelbaum et al., 1986; Reicher et al., 1986; Muellner et al., 1997; Yan et al., 2011; Subhas et al., 2012; Sharifah et al., 2013). Accuracy is defined as a measure of closeness in detecting a quantity to that quantity's actual (true) value. Sensitivity and specificity of MRI are 93 and 88%, respectively for medial meniscal tears, and 79 and 95%, respectively for lateral meniscal tears (Oei et al., 2003). Sensitivity and specificity are statistical measures that describe the proportion of actual positives that are correctly identified and the proportion of negatives that are correctly identified, respectively. Spin-echo or fast spin-echo proton density with or without fat saturation, T1, and gradient echo are the most commonly used sequences (Helms, 2002).

The MRI grading system classifies tears based on their appearance on an MRI scan (Fig. 8). Grade 0 represents an intact, normal meniscus. Grade I and Grade II signals do not intersect the superior or inferior articular surface of the meniscus, but may represent meniscal degeneration. A Grade III signal intersects the superior and/or inferior articular surface of the meniscus and represents a tear (Fig. 8).

### Arthroscopy

Diagnostic arthroscopy has become the gold standard for assessing meniscal injuries and determining

the feasibility of a successful repair (Maffulli et al., 2012). A probe is used to characterize the size of the tear, degree of instability, quality of the tissue and zone of the tear (i.e., red-red, red-white, and white-white) and the width and integrity of the meniscal rim is evaluated (Jackson, 2008). Once the diagnostic arthroscopy is complete, the treating surgeon should determine the appropriate treatment.

## ADVANCES IN TREATMENT

The goal of surgical intervention for meniscal tears is to relieve pain, facilitate preinjury level daily living activities, and prevent early degeneration of the knee joint. In the past, total meniscectomy was the gold standard because the meniscus was considered a functionless remnant vestige (Sutton, 1897). In his landmark article, Fairbank radiologically examined postmeniscectomized knees, describing the femoral condylar flattening and narrowing of the joint space that occurred over time (Fairbank, 1948). However, despite this evidence, total meniscectomy remained the widespread treatment of meniscal tears until the 1970s.

Over the past four decades, with the general adoption of arthroscopy, there has been an improvement in surgical techniques to assess and treat meniscal pathology. These improvements along with an enhanced understanding of the anatomic structure and biomechanical function of the menisci has led to a shift toward preservation of the menisci to avoid the degenerative results that follow its removal (Jackson, 1968; Appel, 1970; Johnson et al., 1974; Lutfi, 1975; McGinity et al., 1977; Hoch et al., 1983; Northmore-Ball et al., 1983; Voloshin and Wosk, 1983; Allen et al., 1984; Ghosh et al., 1990; Berjon et al., 1991; Abrams et al., 2013). Partial meniscectomy is still indicated if the tear cannot be satisfactorily sutured (Sommerlath, 1991; Shelbourne and Carr, 2003). Meniscal preservation includes leaving small or partial tears, partial meniscectomy and meniscus repair techniques. Meniscal allograft transplantation and the use of synthetic implants have been described in the literature and have shown promising results in symptomatic patients that have undergone a partial, subtotal or total meniscectomy (Brophy and Matava, 2012).

### Meniscal Repair

Meniscal repair techniques have been developed and refined over the years. A combination of techniques may be used to adequately stabilize a particular meniscal tear. Common to every type of meniscal repair is preparation of the meniscus and the local environment. Any loose or frayed fragments of meniscus should be removed and the opposing edges are rasped to define the meniscal edge and promote the healing response (Ochi et al., 2001; Laible et al., 2013). It is also recommended that abrasion of the local synovium be routinely performed.

Only certain types of tears are feasible for meniscal repair due to the limited vascular supply of the meniscus. Tear morphologies such as flaps, radial tears, and

degenerative tears are generally not repaired (Laible et al., 2013; Taylor and Rodeo, 2013). In a prospective study using second-look arthroscopies, Scott et al. reported the highest rates of healing in menisci that had a narrow peripheral meniscal rim (range 0–2 mm) (Scott et al., 1986). Typically, longitudinal tears that are less than 3 cm in length and within the peripheral zone of the meniscus are amenable to repair (Taylor and Rodeo, 2013). Currently, it is unclear whether the timing of repair affects success (Tengrootenhuysen et al., 2011; Laible et al., 2013). Age of patient has been reported to be a factor in capacity to heal. Laible et al. reported an improved healing response in younger patients following meniscal repair (Laible et al., 2013). In the event that a ligamentous (e.g., ACL) injury has occurred concomitantly with the meniscal tear, it is recommended that reconstruction be performed to improve functional stability of the knee (Neppele et al., 2012). Meniscal repair in conjunction with ACL reconstruction, orthopaedic surgeons can expect an estimated >90% clinical success rate at 2-year follow-up (Warren, 1990; Cannon and Vittori, 1992; Guisasola et al., 2002; Pujol et al., 2008; Pujol and Beaufils, 2009; Toman et al., 2009; Ghodadra et al., 2012; Fu et al., 2013; Yan et al., 2014). Conversely, meniscal reconstruction in the ligamentous stable knee, without concomitant ACL reconstruction resulted in a 50–67% clinical success rate (Cannon and Vittori, 1992; Daniel et al., 1994; Shelbourne and Klotz, 2006). It is believed that simultaneous ACL reconstruction with meniscal repair achieves better meniscal healing because of intra-articular bleeding from the surgically exposed tunnels (Ochi et al., 2001; Guisasola et al., 2002; Scotti et al., 2009) and the improved stability of knee (Shelbourne et al., 1996).

Several repair techniques facilitating suture alone or repair devices has been described in the literature. The inside-out and outside-in techniques use suture that is either first passed on either side of the tear through the meniscus using a cannulated needle and passed out of the joint capsule (inside-out technique) or the other way round (outside-in technique). The main risk of this technique is to cause injury to neurovascular structures and the difficulty in accessing the anterior portion of the medial and lateral menisci (Laible et al., 2013). Newer generation repair devices allow all-arthroscopic meniscal repair by facilitating anchors located outside the joint capsule and sliding knots that can be tensioned by the surgeon for secure tear repair. Meniscal horn tears may be fixed back to the tibial plateau either using suture anchors in the bone or using a transosseous suturing technique with sutures brought through bone tunnels.

Typically, postoperative recovery following meniscal repair is slow (approximately 4 months) due to the need to protect the healing tissue. In an attempt to optimize the healing capacity of the meniscus, a number of augmentation techniques have been investigated. These include trephination (Zhang et al., 1995), fibrin clots (Arnoczky et al., 1988; Henning et al., 1990; van Trommel et al., 1998), and platelet-rich plasma (PRP) (Delos and Rodeo, 2011). Trephination connects a meniscal lesion in the avascular zone

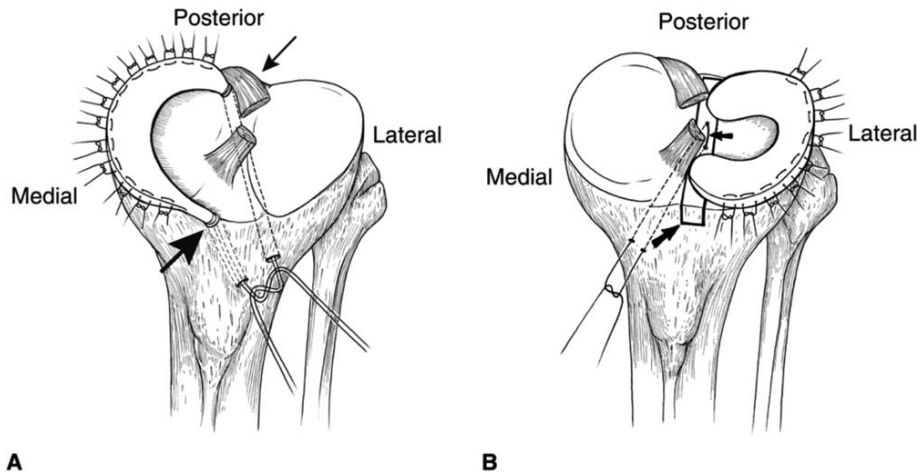
to the peripheral blood supply via a vascular access channel and allows vascular ingrowth and enhances the healing potential when combined with suture repair of the lesion (Zhang et al., 1995). Autogenous fibrin clots, a precipitated clot material produced by agitation of whole blood, may contain platelet-derived growth factor and fibronectin that may act as chemotactic and mitogenic stimuli of reparative cells and provide a scaffolding to support a reparative response of meniscal lesions (Arnoczky et al., 1988). PRP may initiate the healing cascade by releasing growth factors from the alpha and dense granules located in the platelet cytoplasm. These growth factors lead to cellular chemotaxis, angiogenesis, collagen matrix synthesis, and cell proliferation (Delos and Rodeo, 2011). Future studies are required to determine the long-term effects of these augmentation techniques on meniscal healing.

### Meniscal Allograft Transplantation

Milachowski et al. were the first to publish a clinical study using meniscal allograft transplantation in painful postmeniscectomized patients (Milachowski et al., 1989). Since then, meniscal transplantation has become an accepted management option for select young symptomatic patients who have undergone a subtotal or total meniscectomy (Fig. 10) (Verdonk et al., 2013). Patients who develop symptoms of pain and swelling due to early degenerative changes following meniscectomy are the typical candidates for this procedure.

A study by Verdonk et al. reported that 75–90% of patients experienced fair to excellent functional results after meniscal allograft transplantation (Verdonk et al., 2013). The authors also found that second-look arthroscopies reported good healing of the peripheral rim to the joint capsule in the majority of patients, although shrinkage of the transplant was observed in some cases (Verdonk et al., 2013). The clinical survivorship 10 years postoperatively is estimated to be 70% for medial and lateral allografts (Verdonk et al., 2013). In a systematic review of the literature by Hergan et al., the expected outcome following meniscal allograft transplantation should be a painless knee during activities of daily living. The patients should be informed that expectations of returning to sports should not be overestimated (Hergan et al., 2011). Recovery time is approximately 6 months.

The primary indication for a meniscal transplant is pain localized to the involved compartment (Brophy and Matava, 2012). At the time of transplantation, there should be only mild pre-existing arthrosis and no focal chondral lesion higher than Grade III (Brophy and Matava, 2012; Verdonk et al., 2013). A stable knee joint in correct axial alignment should be ensured. If necessary, ligamentous reconstruction and/or corrective osteotomies should be performed. Axial mal-alignment may result in excessive compressive loads on the allograft leading to graft failure (Rijk, 2004). A size-matched meniscus implant with a size tolerance of 5% should be used (Brophy and Matava, 2012). Commonly, the periphery of the



**Fig. 10.** Meniscal Allograft Transplantation. **(A)** Medial meniscal allograft transplantation with anterior (large arrow) and posterior (small arrow) bone plugs through transosseous tunnels. A combination of sutures placed arthroscopically and open fix the meniscal allograft to the peripheral rim. **(B)** Lateral meniscal allograft transplantation using a bone bridge. The bone bridge is

secured in the tibial trough (large arrow) using transosseous sutures (small arrow). A combination of arthroscopically and open placed sutures fix the meniscal allograft to the peripheral rim. Image reprinted with permission from (Sekiya JK, Ellingson CI. *J Am Acad Orthop Surg*, 2006, 14, 164–174).

meniscal allograft is sutured to the remaining peripheral rim or the joint capsule. The meniscal horns are fixed with either small, attached bone plugs (the senior authors' preference) or soft tissue fixation with sutures (Fig.10).

Contraindications for allograft implantation are advanced arthrosis, obesity, synovial disease, inflammatory arthritis, significant osteoarthritis (OARS Grade 3–4), and previous joint infection (Verdonk et al., 2013). Drawbacks include the limited number of available grafts, cost, graft sizing, effects of sterilization and preservation on biomechanical strength of the graft, and the risk of disease transmission (Brophy and Matava, 2012; Verdonk et al., 2013). Currently, no level I evidence exists to support the role of a meniscus transplant in halting the progression of osteoarthritis (Hergan et al., 2011).

### Synthetic Implants

Synthetic scaffolds are emerging as a promising alternative to meniscal allograft transplantation for partial meniscal replacement in symptomatic patients. The Menaflex Collagen Meniscal Implant (Regen Biologics, Hackensack, NJ) and the Actifit polyurethane scaffold (Orteq, London, UK) are currently used in clinical studies outside of the U.S. The goal of these resorbable scaffolds is to allow in-growth of meniscal tissue and thereby create a regenerated meniscus over time formed by host tissue (Verdonk et al., 2013).

The Menaflex is composed of Collagen I isolated from bovine Achilles tendons, treated with hyaluronic acid, chondroitin sulphate, glycosaminoglycans and cross-linked with formaldehyde. The scaffold is

sterilized with gamma irradiation. The result is a sponge like structure with a pore size ranging from 75 to 400 microns (Stone et al., 1997). The surgical technique includes preparation of the implant bed, confirmation of the blood supply, rehydration, and sizing of the implant, followed by the securing of the implant to the remaining meniscus using suture (Stone et al., 1997). The implant requires a meniscal rim and intact anterior and posterior meniscal horns for attachment (Rodkey et al., 1999). Rodkey et al. presented a large randomized trial comparing the collagen meniscal implant with partial medial meniscectomy (Rodkey et al., 2008). The authors of this study were able to demonstrate that patients with prior partial medial meniscectomy regained significantly more of their lost activity and significantly fewer reoperations were necessary (Rodkey et al., 2008). Conversely, patients with an acute trauma to the meniscus without prior surgery did not show a significant difference compared to the control group. Zaffagnini et al. presented a nonrandomized cohort study of 33 patients with medial meniscus injuries and minimum 10 year follow-up (Zaffagnini et al., 2011). Patients themselves decided if they preferred partial medial meniscectomy alone or with implantation of a collagen meniscal implant. At a minimum of 10 years postop, the patients that underwent scaffold implantation showed significantly lower pain scores, higher activity level and significantly less medial joint space narrowing on radiographs than the control group (Zaffagnini et al., 2011).

The Actifit meniscus implant is a slowly degrading polymer-polycaprolactone and urethane porous scaffold with high interconnectivity. The scaffold has been shown to improve contact area and pressure in a cadaveric ovine model (Maher et al., 2011). Verdonk

and colleagues were able to demonstrate on MRI 3 months after implantation tissue ingrowth and vascular perfusion in 35 of 43 patients (Verdonk et al., 2011). A second-look arthroscopy 1 year following surgery showed integration of the implant in 43 out of 44 patients. Patients with irreparable medial and lateral meniscal defects showed a statistically significant improvement in pain and activity scores 6 months after implantation of the Actifit scaffold compared to baseline (Verdonk et al., 2012).

Several other implants have been tested in animal studies including implants derived from porcine small intestinal submucosa (Cook et al., 2006), polycaprolactone and hyaluronan-derived polymer reinforced with polylactic acid fibers or polyethylene terephthalate net (Chiari et al., 2006), Kevlar reinforced polycarbonate-urethane implants (Zur et al., 2011), and ultrahigh-molecular-weight polyethylene fiber reinforced polyvinyl-alcohol hydrogel implants (unpublished data).

The current challenges of implant design are the fixation (particularly of total meniscal implants), the material properties, and surface characteristics. Good fixation of the graft to the tibia and joint capsule is mandatory to minimize extrusion of the implant. The material properties of the implant should be engineered to match the compressive and tensile properties of the native meniscus. The implant surface characteristics are important to minimize chondral damage to the femur and tibia.

## CONCLUSIONS

The menisci are integral to the normal function of the knee joint and play an important role in load distribution, shock absorption, stability, lubrication, and proprioception. Injuries to the menisci are recognized as a common cause of significant musculoskeletal morbidity. The unique and complex structure of the menisci makes treatment and repair challenging for the patient, the surgeon and the physical therapist. Preservation of the menisci's distinctive composition and organization is paramount to knee joint health.

## REFERENCES

- Aagaard H, Verdonk R. 1999. Function of the normal meniscus and consequences of meniscal resection. *Scand J Med Sci Sports* 9: 134–140.
- Abrams GD, Frank RM, Gupta AK, Harris JD, McCormick FM, Cole BJ. 2013. Trends in meniscus repair and meniscectomy in the United States, 2005–2011. *Am J Sports Med* 41:2333–2339.
- Ahmed AM, Burke DL. 1983. In-vitro measurement of static pressure distribution in synovial joints—Part I: Tibial surface of the knee. *J Biomech Eng* 105:216–225.
- Aichroth P. 1996. Degenerative meniscal tears. *Knee* 3:70–71.
- Akgun U, Kocaoglu B, Orhan EK, Baslo MB, Karahan M. 2008. Possible reflex pathway between medial meniscus and semimembranosus muscle: an experimental study in rabbits. *Knee Surg Sports Traumatol Arthrosc* 16:809–814.
- Allen CR, Wong EK, Livesay GA, Sakane M, Fu FH, Woo SL. 2000. Importance of the medial meniscus in the anterior cruciate ligament-deficient knee. *J Orthop Res* 18:109–115.
- Allen PR, Denham RA, Swan AV. 1984. Late degenerative changes after meniscectomy. Factors affecting the knee after operation. *J Bone Joint Surg Br* 66:666–671.
- Anderson AF, Irrgang JJ, Dunn W, Beauflis P, Cohen M, Cole BJ, Coolican M, Ferretti M, Glenn RE, Jr, Johnson R, Neyret P, Ochi M, Panarella L, Siebold R, Spindler KP, Ait Si Selmi T, Verdonk P, Verdonk R, Yasuda K, Kowalchuk DA. 2011. Interobserver reliability of the International Society of Arthroscopy, Knee Surgery and Orthopaedic Sports Medicine (ISAKOS) classification of meniscal tears. *Am J Sports Med* 39:926–932.
- Appel H. 1970. Late results after meniscectomy in the knee joint. A clinical and roentgenologic follow-up investigation. *Acta Orthop Scand Suppl* 133:1–111.
- Arnoczky SP. 1992. Gross and vascular anatomy of the meniscus and its role in meniscal healing, regeneration and remodeling. In: Mow VC, Arnoczky SP, Jackson SW, editors. *Knee Meniscus: Basic and Clinical Foundations*. New York: Raven Press. p 1–14.
- Arnoczky SP, Adams ME, DeHaven KE, Eyre DR, Mow VC. 1987. The meniscus. In: Woo SL, Buckwalter J, editors. *Injury and Repair of Musculoskeletal Soft Tissues*. Park Ridge, IL: American Academy of Orthopaedic Surgeons. p 487–537.
- Arnoczky SP, Warren RF. 1982. Microvasculature of the human meniscus. *Am J Sports Med*. 10:90–95.
- Arnoczky SP, Warren RF, Spivak JM. 1988. Meniscal repair using an exogenous fibrin clot. An experimental study in dogs. *J Bone Joint Surg Am* 70:1209–1217.
- Aspden RM, Yarker YE, Hukins DW. 1985. Collagen orientations in the meniscus of the knee joint. *J Anat* 140:371–380.
- Assimakopoulos AP, Katonis PG, Agapitos MV, Exarchou EI. 1992. The innervation of the human meniscus. *Clin Orthop Relat Res* 275:232–236.
- Baker BE, Peckham AC, Puppato F, Sanborn JC. 1985. Review of meniscal injury and associated sports. *Am J Sports Med* 13:1–4.
- Baratz ME, Fu FH, Mengato R. 1986. Meniscal tears: the effect of meniscectomy and of repair on intraarticular contact areas and stress in the human knee. A preliminary report. *Am J Sports Med* 14:270–275.
- Bargar WL, Moreland JR, Markolf KL, Shoemaker SC, Amstutz HC, Grant TT. 1980. In vivo stability testing of post-meniscectomy knees. *Clin Orthop Relat Res* 150:247–252.
- Beauflis P, Verdonk R. 2010. *The meniscus*. Berlin: Springer.
- Beaupre A, Choukroun R, Guidouin R, Garneau R, Gerardin H, Cardou A. 1986. Knee menisci. Correlation between microstructure and biomechanics. *Clin Orthop Relat Res* 208:72–75.
- Bedi A, Kelly NH, Baad M, Fox AJ, Brophy RH, Warren RF, Maher SA. 2010. Dynamic contact mechanics of the medial meniscus as a function of radial tear, repair, and partial meniscectomy. *J Bone Joint Surg Am* 92:1398–1408.
- Bedi A, Kelly N, Baad M, Fox AJ, Ma Y, Warren RF, Maher SA. 2012. Dynamic contact mechanics of radial tears of the lateral meniscus: Implications for treatment. *Arthroscopy* 28:372–381.
- Bedi A, Chen T, Santner TJ, El-Amin S, Kelly NH, Warren RF, Maher SA. 2013. Changes in dynamic medial tibiofemoral contact mechanics and kinematics after injury of the anterior cruciate ligament: A cadaveric model. *Proc Inst Mech Eng H* 227:1027–1037.
- Berjon JJ, Munuera L, Calvo M. 1991. Degenerative lesions in the articular cartilage after meniscectomy: Preliminary experimental study in dogs. *J Trauma* 31:342–350.
- Berlet GC, Fowler PJ. 1998. The anterior horn of the medial meniscus. An anatomic study of its insertion. *Am J Sports Med* 26: 540–543.
- Beveridge JE, Shrive NG, Frank CB. 2011. Meniscectomy causes significant in vivo kinematic changes and mechanically induced focal chondral lesions in a sheep model. *J Orthop Res* 29:1397–1405.
- Bird MD, Sweet MB. 1987. A system of canals in semilunar menisci. *Ann Rheum Dis* 46:670–673.
- Bird MD, Sweet MB. 1988. Canals in the semilunar meniscus: Brief report. *J Bone Joint Surg Br* 70:839.
- Brantigan OC, Voshell AFJ. 1941. The mechanics of the ligaments and menisci of the knee joint. *J Bone Joint Surg Am* 23:44–66.

- Brophy RH, Matava MJ. 2012. Surgical options for meniscal replacement. *J Am Acad Orthop Surg* 20:265–272.
- Browner BD, Jupiter JB, Levine AM, Trafton PG. 2003. *Skeletal Trauma. Basic Science, Management and Reconstruction.*, 3rd Ed. Philadelphia, PA: Saunders.
- Bullough PG, Munuera L, Murphy J, Weinstein AM. 1970. The strength of the menisci of the knee as it relates to their fine structure. *J Bone Joint Surg Br* 52:564–567.
- Burr DB, Radin EL. 1982. Meniscal function and the importance of meniscal regeneration in preventing late medical compartment osteoarthritis. *Clin Orthop Relat Res* 171:121–126.
- Canale ST, Beatty JH. 2013. *Campbell's Operative Orthopaedics*, 12th Ed. Philadelphia, PA: Elsevier.
- Cannon WD, Jr, Vittori JM. 1992. The incidence of healing in arthroscopic meniscal repairs in anterior cruciate ligament-reconstructed knees versus stable knees. *Am J Sports Med* 20:176–181.
- Carney SL, Muir H. 1988. The structure and function of cartilage proteoglycans. *Physiol Rev* 68:858–910.
- Casteleyn PP, Handelberg F, Opdecam P. 1988. Traumatic haemarthrosis of the knee. *J Bone Joint Surg Br* 70:404–406.
- Cheung HS. 1987. Distribution of type I, II, III and V in the pepsin solubilized collagens in bovine menisci. *Connect Tissue Res* 16:343–356.
- Chevrier A, Nelea M, Hurtig MB, Hoemann CD, Buschmann MD. 2009. Meniscus structure in human, sheep, and rabbit for animal models of meniscus repair. *J Orthop Res* 27:1197–1203.
- Chiari C, Koller U, Dorotka R, Eder C, Plasenzotti R, Lang S, Ambrosio L, Tognana E, Kon E, Salter D, Nehrer S. 2006. A tissue engineering approach to meniscus regeneration in a sheep model. *Osteoarthritis Cartilage* 14:1056–1065.
- Clark CR, Ogden JA. 1983. Development of the menisci of the human knee joint. Morphological changes and their potential role in childhood meniscal injury. *J Bone Joint Surg Am* 65:538–547.
- Clayton RA, Court-Brown CM. 2008. The epidemiology of musculoskeletal tendinous and ligamentous injuries. *Injury*. 39:1338–1344.
- Cook JL, Fox DB, Malaviya P, Tomlinson JL, Farr J, Kuroki K, Cook CR. 2006. Evaluation of small intestinal submucosa grafts for meniscal regeneration in a clinically relevant posterior meniscectomy model in dogs. *J Knee Surg* 19:159–167.
- Cooper DE, Arnoczky SP, Warren RF. 1990. Arthroscopic meniscal repair. *Clin Sports Med* 9:589–607.
- Crawford K, Briggs KK, Rodkey WG, Steadman JR. 2007. Reliability, validity, and responsiveness of the IKDC score for meniscus injuries of the knee. *Arthroscopy* 23:839–844.
- Dandy DJ. 1990. The arthroscopic anatomy of symptomatic meniscal lesions. *J Bone Joint Surg Br* 72:628–633.
- Daniel DM, Stone ML, Dobson BE, Fithian DC, Rossman DJ, Kaufman KR. 1994. Fate of the ACL-injured patient. A prospective outcome study. *Am J Sports Med* 22:632–644.
- Danzig L, Resnick D, Gonsalves M, Akeson WH. 1983. Blood supply to the normal and abnormal menisci of the human knee. *Clin Orthop Relat Res* 172:271–276.
- Day B, Mackenzie WG, Shim SS, Leung G. 1985. The vascular and nerve supply of the human meniscus. *Arthroscopy* 1:58–62.
- Delos D, Rodeo SA. 2011. Enhancing meniscal repair through biology: Platelet-rich plasma as an alternative strategy. *Instr Course Lect* 60:453–460.
- Dong Y, Hu G, Dong Y, Hu Y, Xu Q. 2014. The effect of meniscal tears and resultant partial meniscectomies on the knee contact stresses: A finite element analysis. *Comput Methods Biomech Biomed Engin* 17:1452–1463.
- Dorsay TA, Helms CA. 2003. Bucket-handle meniscal tears of the knee: sensitivity and specificity of MRI signs. *Skeletal Radiol* 32:266–272.
- Drosos GI, Pozo JL. 2004. The causes and mechanisms of meniscal injuries in the sporting and non-sporting environment in an unselected population. *Knee* 11:143–149.
- Dudhia J, McAlinden A, Muir A, Bayliss M. 2004. The meniscus – structure, composition and pathology. In: Hazelman B, Riley G, Speed C, editors. *Soft Tissue Rheumatology*. New York, NY: Oxford University Press.
- Dye SF. 2003. Functional morphologic features of the human knee: an evolutionary perspective. *Clin Orthop Relat Res* 410:19–24.
- Englund M, Guermazi A, Lohmander LS. 2009. The meniscus in knee osteoarthritis. *Rheum Dis Clin North Am*. 35:579–590.
- Fairbank TJ. 1948. Knee joint changes after meniscectomy. *J Bone Joint Surg Br* 30B:664–670.
- Fithian DC, Kelly MA, Mow VC. 1990. Material properties and structure-function relationships in the menisci. *Clin Orthop Relat Res* 252:19–31.
- Fox AJ, Bedi A, Rodeo SA. 2012. The basic science of human knee menisci: Structure, composition, and function. *Sports Health* 4:340–351.
- Fox MG. 2007. MR imaging of the meniscus: Review, current trends, and clinical implications. *Magn Reson Imaging Clin N Am* 15:103–123.
- Fu SC, Cheng WH, Cheuk YC, Mok TY, Rolf CG, Yung SH, Chan KM. 2013. Effect of graft tensioning on mechanical restoration in a rat model of anterior cruciate ligament reconstruction using free tendon graft. *Knee Surg Sports Traumatol Arthrosc* 21:1226–1233.
- Fukazawa I, Hatta T, Uchio Y, Otani H. 2009. Development of the meniscus of the knee joint in human fetuses. *Congenit Anom (Kyoto)*. 49:27–32.
- Fukubayashi T, Kurosawa H. 1980. The contact area and pressure distribution pattern of the knee. A study of normal and osteoarthrotic knee joints. *Acta Orthop Scand* 51:871–879.
- Fukubayashi T, Torzilli PA, Sherman MF, Warren RF. 1982. An in vitro biomechanical evaluation of anterior-posterior motion of the knee. Tibial displacement, rotation, and torque. *J Bone Joint Surg Am* 64:258–264.
- Fukuda Y, Takai S, Yoshino N, Murase K, Tsutsumi S, Ikeuchi K, Hirasawa Y. 2000. Impact load transmission of the knee joint-influence of leg alignment and the role of meniscus and articular cartilage. *Clin Biomech (Bristol, Avon)* 15:516–521.
- Gardner E. 1948. The innervations of the knee joint. *Anat Rec* 101:109–130.
- Gardner E, O'Rahilly R. 1968. The early development of the knee joint in staged human embryos. *J Anat* 102:289–299.
- Ghadially FN, Lalonde JM, Wedge JH. 1983. Ultrastructure of normal and torn menisci of the human knee joint. *J Anat* 136:773–791.
- Ghodadra NS, Mall NA, Grumet R, Sherman SL, Kirk S, Provencher MT, Bach BR, Jr. 2012. Interval arthroscopic comparison of anterior cruciate ligament reconstruction using bone-patellar tendon-bone autograft versus allograft: do grafts attenuate within the first year postoperatively? *Am J Sports Med* 40:1347–1354.
- Ghosh P, Sutherland J, Bellenger C, Read R, Darvodelsky A. 1990. The influence of weight-bearing exercise on articular cartilage of meniscectomized joints. An experimental study in sheep. *Clin Orthop Relat Res* 252:101–113.
- Gilbert S, Chen T, Hutchinson ID, Choi D, Voigt C, Warren RF, Maher SA. 2013. Dynamic contact mechanics on the tibial plateau of the human knee during activities of daily living. *J Biomech* 16:00555–00551.
- Gray JC. 1999. Neural and vascular anatomy of the menisci of the human knee. *J Orthop Sports Phys Ther* 29:23–30.
- Greis PE, Bardana DD, Holmstrom MC, Burks RT. 2002. Meniscal injury: I. Basic science and evaluation. *J Am Acad Orthop Surg* 10:168–176.
- Gronblad M, Korkala O, Liesi P, Karaharju E. 1985. Innervation of synovial membrane and meniscus. *Acta Orthop Scand* 56:484–486.
- Guisasola I, Vaquero J, Forriol F. 2002. Knee immobilization on meniscal healing after suture: an experimental study in sheep. *Clin Orthop Relat Res* 395:227–233.
- Haines RW. 1942. The tetrapod knee joint. *J Anat*. 76:270–301.
- Harner CD, Janaushek MA, Kanamori A, Yagi M, Vogrin TM, Woo SL. 2000. Biomechanical analysis of a double-bundle posterior cruciate ligament reconstruction. *Am J Sports Med* 28:144–151.

- Harper KW, Helms CA, Lambert HS, 3rd, Higgins LD. 2005. Radial meniscal tears: significance, incidence, and MR appearance. *AJR Am J Roentgenol* 185:1429–1434.
- Hauser RA, Philips HJ, Maddela HS. 2010. Animal Research Together with Five Patient Case Reports Demonstrate that Platelet Rich Plasma Prolotherapy is Effective in the Treatment of MRI-Documented Meniscal Tears. *J Prolother* 2:416–437.
- Hayes CW, Brigido MK, Jamadar DA, Propeck T. 2000. Mechanism-based pattern approach to classification of complex injuries of the knee depicted at MR imaging. *Radiographics* 20:S121–S134.
- Hede A, Jensen DB, Blyme P, Sonne-Holm S. 1990. Epidemiology of meniscal lesions in the knee. 1,215 open operations in Copenhagen 1982–84. *Acta Orthop Scand* 61:435–437.
- Helms CA. 2002. The meniscus: recent advances in MR imaging of the knee. *AJR Am J Roentgenol* 179:1115–1122.
- Henning CE, Lynch MA, Clark JR. 1987. Vascularity for healing of meniscus repairs. *Arthroscopy* 3:13–18.
- Henning CE, Lynch MA, Yearout KM, Vequist SW, Stallbaumer RJ, Decker KA. 1990. Arthroscopic meniscal repair using an exogenous fibrin clot. *Clin Orthop Relat Res* 252:64–72.
- Hergan D, Thut D, Sherman O, Day MS. 2011. Meniscal allograft transplantation. *Arthroscopy* 27:101–112.
- Herwig J, Egner E, Buddecke E. 1984. Chemical changes of human knee joint menisci in various stages of degeneration. *Ann Rheum Dis* 43:635–640.
- Hirschmann MT, Friederich NF. 2009. Meniscal lesions in children, classifications. In: Beaufils P, Verdonk R-, editors. *The Meniscus*. Berlin Heidelberg: Springer-Verlag. p 241–246.
- Hoch DH, Grodzinsky AJ, Koob TJ, Albert ML, Eyre DR. 1983. Early changes in material properties of rabbit articular cartilage after meniscectomy. *J Orthop Res* 1:4–12.
- Irrgang JJ, Snyder-Mackler L, Wainner RS, Fu FH, Harner CD. 1998. Development of a patient-reported measure of function of the knee. *J Bone Joint Surg Am* 80:1132–1145.
- Irrgang JJ, Anderson AF, Boland AL, Harner CD, Neyret P, Richmond JC, Shelbourne KD. 2006. Responsiveness of the international knee documentation committee subjective knee form. *Am J Sports Med* 34:1567–1573.
- Jackson JP. 1968. Degenerative changes in the knee after meniscectomy. *Br Med J* 2:525–527.
- Jackson DW. 2008. *Reconstructive Knee Surgery*. Philadelphia, PA: Lippincott Williams and Wilkins.
- Jee WH, McCauley TR, Kim JM, Jun DJ, Lee YJ, Choi BG, Choi KH. 2003. Meniscal tear configurations: categorization with MR imaging. *AJR Am J Roentgenol* 180:93–97.
- Jerosch J, Prymka M, Castro WH. 1996. Proprioception of knee joints with a lesion of the medial meniscus. *Acta Orthop Belg* 62: 41–45.
- Johannsen AM, Civitarese DM, Padalecki JR, Goldsmith MT, Wijdicks CA, LaPrade RF. 2012. Qualitative and quantitative anatomic analysis of the posterior root attachments of the medial and lateral menisci. *Am J Sports Med* 40:2342–2347.
- Johnson RJ, Kettelkamp DB, Clark W, Leaverton P. 1974. Factors effecting late results after meniscectomy. *J Bone Joint Surg Am* 56:719–729.
- Jones RE, Smith EC, Reisch JS. 1978. Effects of medial meniscectomy in patients older than forty years. *J Bone Joint Surg Am* 60: 783–786.
- Karahan M, Kocaoglu B, Cabukoglu C, Akgun U, Nuran R. 2010. Effect of partial medial meniscectomy on the proprioceptive function of the knee. *Arch Orthop Trauma Surg* 130:427–431.
- Kennedy JC, Alexander JJ, Hayes KC. 1982. Nerve supply of the human knee and its functional importance. *Am J Sports Med* 10: 329–335.
- Kettelkamp DB, Jacobs AW. 1972. Tibiofemoral contact area—Determination and implications. *J Bone Joint Surg Am* 54:349–356.
- Krause WR, Pope MH, Johnson RJ, Wilder DG. 1976. Mechanical changes in the knee after meniscectomy. *J Bone Joint Surg Am* 58:599–604.
- Kurosawa H, Fukubayashi T, Nakajima H. 1980. Load-bearing mode of the knee joint: physical behavior of the knee joint with or without menisci. *Clin Orthop Relat Res* 149:283–290.
- Laible C, Stein DA, Kiridly DN. 2013. Meniscal repair. *J Am Acad Orthop Surg* 21:204–213.
- Last RJ. 1950. The popliteus muscle and the lateral meniscus. *J bone Joint Surg Br* 32:93–99.
- Lecas LK, Helms CA, Kosarek FJ, Garret WE. 2000. Inferiorly displaced flap tears of the medial meniscus: MR appearance and clinical significance. *AJR Am J Roentgenol* 174:161–164.
- Lee SJ, Aadalen KJ, Malaviya P, Lorenz EP, Hayden JK, Farr J, Kang RW, Cole BJ. 2006. Tibiofemoral contact mechanics after serial medial meniscectomies in the human cadaveric knee. *Am J Sports Med* 34:1334–1344.
- Levy IM, Torzilli PA, Warren RF. 1982. The effect of medial meniscectomy on anterior-posterior motion of the knee. *J Bone Joint Surg Am* 64:883–888.
- Levy IM, Torzilli PA, Gould JD, Warren RF. 1989. The effect of lateral meniscectomy on motion of the knee. *J Bone Joint Surg Am* 71: 401–406.
- Lutfi AM. 1975. Morphological changes in the articular cartilage after meniscectomy. An experimental study in the monkey. *J Bone Joint Surg Br* 57:525–528.
- MacConaill MA. 1932. The function of intra-articular fibrocartilages, with special reference to the knee and inferior radio-ulnar joints. *J Anat* 66:210–227.
- MacConaill MA. 1946. Studies in the mechanics of synovial joints. *Irish Journal of Medical Science* 21:223–235.
- MacConaill MA. 1950. The movements of bones and joints 3. The synovial fluid and its assistants. *Journal of Bone & Joint Surgery* 32:244–252.
- Maffulli N, Longo UG, Campi S, Denaro V. 2010. Meniscal tears. *Open Access J Sports Med* 1:45–54. eCollection 2010.
- Maffulli N, Longo UG, Campi S, Denaro V. 2012. Meniscal tears (Meniscectomy, Meniscopexy, Meniscal Transplants/Scaffolds). *Evidence-Based Orthopedics* 803–811.
- Magee T, Shapiro M, Williams D. 2002. MR accuracy and arthroscopic incidence of meniscal radial tears. *Skeletal Radiol* 31:686–689.
- Magee TH, Hinson GW. 1998. MRI of meniscal bucket-handle tears. *Skeletal Radiol* 27:495–499.
- Maher SA, Rodeo SA, Potter HG, Bonassar LJ, Wright TM, Warren RF. 2011. A pre-clinical test platform for the functional evaluation of scaffolds for musculoskeletal defects: the meniscus. *HSS J* 7: 157–163.
- Majewski M, Susanne H, Klaus S. 2006. Epidemiology of athletic knee injuries: A 10-year study. *Knee* 13:184–188.
- Makris EA, Hadidi P, Athanasiou KA. 2011. The knee meniscus: structure-function, pathophysiology, current repair techniques, and prospects for regeneration. *Biomaterials* 32:7411–7431.
- Mandelbaum BR, Finerman GA, Reicher MA, Hartzman S, Bassett LW, Gold RH, Rauschnig W, Dorey F. 1986. Magnetic resonance imaging as a tool for evaluation of traumatic knee injuries. Anatomical and pathoanatomical correlations. *Am J Sports Med* 14: 361–370.
- Markolf KL, Mensch JS, Amstutz HC. 1976. Stiffness and laxity of the knee—the contributions of the supporting structures. A quantitative in vitro study. *J Bone Joint Surg Am* 58:583–594.
- Markolf KL, Bargar WL, Shoemaker SC, Amstutz HC. 1981. The role of joint load in knee stability. *J Bone Joint Surg Am* 63:570–585.
- McDermott ID, Amis AA. 2006. The consequences of meniscectomy. *J Bone Joint Surg Br* 88:1549–1556.
- McDermott ID, Masouros SD, Amis AA. 2008. Biomechanics of the menisci of the knee. *Current Orthopaedics* 22:193–201.
- McGinity JB, Geuss LF, Marvin RA. 1977. Partial or total meniscectomy: a comparative analysis. *J Bone Joint Surg Am* 59:763–766.
- McKeon BP, Bono JV, Richmond JC. 2009. *Knee Arthroscopy*. New York, NY: Springer Science and Business Media.
- Messner K, Gao J. 1998. The menisci of the knee joint. Anatomical and functional characteristics, and a rationale for clinical treatment. *J Anat* 193:161–178.

- Metcalf RW. 1981. Operative arthroscopy of the knee. *Instr Course Lect* 30:357–396.
- Metcalf MH, Barrett GR. 2004. Prospective evaluation of 1485 meniscal tear patterns in patients with stable knees. *Am J Sports Med* 32:675–680.
- Meyers E, Zhu W, Mow V. 1988. Viscoelastic properties of articular cartilage and meniscus. In: Nimmi M, editor. *Collagen: Chemistry, Biology and Biotechnology*. Boca Raton, FL: CRC.
- Milachowski KA, Weismeier K, Wirth CJ. 1989. Homologous meniscus transplantation. Experimental and clinical results. *Int Orthop* 13:1–11.
- Mine T, Kimura M, Sakka A, Kawai S. 2000. Innervation of nociceptors in the menisci of the knee joint: an immunohistochemical study. *Arch Orthop Trauma Surg* 120:201–204.
- Mononen ME, Jurvelin JS, Korhonen RK. 2013. Effects of radial tears and partial meniscectomy of lateral meniscus on the knee joint mechanics during the stance phase of the gait cycle—A 3D finite element study. *J Orthop Res* 31:1208–1217.
- Mordecai SC, Al-Hadithy N, Ware HE, M. GC. 2014. Treatment of meniscal tears: an evidence based approach. *World J Orthop* 5: 233–241.
- Mossman DJ, Sargeant WAS. 1983. The footprints of extinct animals. *Sci Am* 248:78–79.
- Mow VC, Gu WY, Chen HC. 2005. Structure and function of articular cartilage and meniscus. In: Mow VC, Huijskes R, editors. *Basic Orthopaedic Biomechanics and Mechano-Biology*, 3rd Ed. Philadelphia: Lippincott Williams & Wilkins.
- Muellner T, Weinstabl R, Schabus R, Vecsei V, Kainberger F. 1997. The diagnosis of meniscal tears in athletes. A comparison of clinical and magnetic resonance imaging investigations. *Am J Sports Med* 25:7–12.
- Musahl V, Citak M, O’Loughlin PF, Choi D, Bedi A, Pearle AD. 2010. The effect of medial versus lateral meniscectomy on the stability of the anterior cruciate ligament-deficient knee. *Am J Sports Med* 38:1591–1597.
- Nakata K, Shino K, Hamada M, Mae T, Miyama T, Shinjo H, Horibe S, Tada K, Ochi T, Yoshikawa H. 2001. Human meniscus cell: characterization of the primary culture and use for tissue engineering. *Clin Orthop Relat Res* 391:S208–S218.
- Nepple JJ, Dunn WR, Wright RW. 2012. Meniscal repair outcomes at greater than five years: a systematic literature review and meta-analysis. *J Bone Joint Surg Am* 94:2222–2227.
- Newman AP, Anderson DR, Daniels AU, Dales MC. 1989. Mechanics of the healed meniscus in a canine model. *Am J Sports Med* 17: 164–175.
- Nielsen AB, Yde J. 1991. Epidemiology of acute knee injuries: a prospective hospital investigation. *J Trauma* 31:1644–1648.
- Noble J, Hamblen DL. 1975. The pathology of the degenerate meniscus lesion. *J Bone Joint Surg Br* 57:180–186.
- Northmore-Ball MD, Dandy DJ, Jackson RW. 1983. Arthroscopic, open partial, and total meniscectomy. A comparative study. *J Bone Joint Surg Br* 65:400–404.
- Ochi M, Uchio Y, Okuda K, Shu N, Yamaguchi H, Sakai Y. 2001. Expression of cytokines after meniscal rasping to promote meniscal healing. *Arthroscopy* 17:724–731.
- Ode GE, Van Thiel GS, McArthur SA, Dishkin-Paset J, Leurgans SE, Shewman EF, Wang VM, Cole BJ. 2012. Effects of serial sectioning and repair of radial tears in the lateral meniscus. *Am J Sports Med* 40:1863–1870.
- Oei EH, Nikken JJ, Verstijnen AC, Ginai AZ, Myriam Hunink MG. 2003. MR imaging of the menisci and cruciate ligaments: A systematic review. *Radiology* 226:837–848.
- Oretorp N, Gillquist J, Liljedahl SO. 1979. Long term results of surgery for non-acute anteromedial rotatory instability of the knee. *Acta Orthop Scand* 50:329–336.
- Outerbridge RE. 1961. The etiology of chondromalacia patellae. *J Bone Joint Surg Br* 43-B:752–757.
- Pagnani MJ, Warren RF, Arnoczky SP, Wickiewicz T. 1995. Anatomy of the knee. In: Nicholas JA, Hershman EB, editors. *The Lower Extremity and Spine in Sports Medicine*. 2nd ed. St. Louis, MO: Mosby. p 581–614.
- Palastanga N, Soames R. 2011. *Anatomy and Human Movement, Structure and Function*. Philadelphia, PA: Elsevier Health Sciences.
- Pearle A. 2011. Changes in tibiofemoral contact mechanics following tears of the medial meniscus. *J Bone Joint Surg Am* 93:1–2.
- Philips BB. 2003. Classification of meniscal tears. In: Canale T, editor. *Campbells Operative Orthopaedics*. Philadelphia: Mosby. p 2528–2529.
- Poehling GG, Ruch DS, Chabon SJ. 1990. The landscape of meniscal injuries. *Clin Sports Med* 9:539–549.
- Preuschoft H, Tardieu C. 1996. Biomechanical reasons for the divergent morphology of the knee joint and the distal epiphyseal suture in hominoids. *Folia Primatol (Basel)* 66:82–92.
- Pujol N, Beaufils P. 2009. Healing results of meniscal tears left in situ during anterior cruciate ligament reconstruction: a review of clinical studies. *Knee Surg Sports Traumatol Arthrosc* 17:396–401.
- Pujol N, Panarella L, Selmi TA, Neyret P, Fithian D, Beaufils P. 2008. Meniscal healing after meniscal repair: A CT arthrography assessment. *Am J Sports Med* 36:1489–1495.
- Pujol N, Boisrenoult P. 2009. Meniscus and Osteoarthritis. In: Beaufils P, Verdonk R, editors. *The Meniscus*. Berlin Heidelberg: Springer-Verlag. p 61–66.
- Radin EL, Rose RM. 1986. Role of subchondral bone in the initiation and progression of cartilage damage. *Clin Orthop Relat Res* 213: 34–40.
- Radin EL, de Lamotte F, Maquet P. 1984. Role of the menisci in the distribution of stress in the knee. *Clin Orthop Relat Res* 185: 290–294.
- Rath E, Richmond JC. 2000. The menisci: Basic science and advances in treatment. *Br J Sports Med* 34:252–257.
- Reicher MA, Hartzman S, Duckwiler GR, Bassett LW, Anderson LJ, Gold RH. 1986. Meniscal injuries: Detection using MR imaging. *Radiology* 159:753–757.
- Reider B, Arcand MA, Diehl LH, Mroczek K, Abulencia A, Stroud CC, Palm M, Gilbertson J, Staszak P. 2003. Proprioception of the knee before and after anterior cruciate ligament reconstruction. *Arthroscopy* 19:2–12.
- Renstrom P, Johnson RJ. 1990. Anatomy and biomechanics of the menisci. *Clin Sports Med* 9:523–538.
- Retterer E. 1907. De la forme et des connexions que presentent les fibro- cartilages du genou chez quelques singes d’Afrique. *Cr Soc Biol* 63:20–25.
- Ricklin P, Ruttimann A, Del Bouno MS. 1983. *Diagnosis, Differential Diagnosis and Therapy*. 2nd Ed. Stuttgart, Germany: Verlag Georg Thieme.
- Rijk PC. 2004. Meniscal allograft transplantation—part I: Background, results, graft selection and preservation, and surgical considerations. *Arthroscopy* 20:728–743.
- Robinson P. 2010. *Essential Radiology for Sports Medicine. Knee Injuries*. Springer.
- Rodkey WG, Steadman JR, Li ST. 1999. A clinical study of collagen meniscus implants to restore the injured meniscus. *Clin Orthop Relat Res* 367:S281–S292.
- Rodkey WG. 2000. Basic biology of the meniscus and response to injury. *Instr Course Lect* 49:189–193.
- Rodkey WG, DeHaven KE, Montgomery WH, 3rd, Baker CL, Jr, Beck CL, Jr, Hormel SE, Steadman JR, Cole BJ, Briggs KK. 2008. Comparison of the collagen meniscus implant with partial meniscectomy. A prospective randomized trial. *J Bone Joint Surg Am* 90: 1413–1426.
- Roos H, Lauren M, Adalberth T, Roos EM, Jonsson K, Lohmander LS. 1998. Knee osteoarthritis after meniscectomy: Prevalence of radiographic changes after twenty-one years, compared with matched controls. *Arthritis Rheum* 41:687–693.
- Roos EM, Ostenberg A, Roos H, Ek Dahl C, Lohmander LS. 2001. Long-term outcome of meniscectomy: symptoms, function, and performance tests in patients with or without radiographic osteoarthritis compared to matched controls. *Osteoarthritis Cartilage* 9:316–324.

- Rosenberg TD, Paulos LE, Parker RD, Coward DB, Scott SM. 1988. The forty-five-degree posteroanterior flexion weight-bearing radiograph of the knee. *J Bone Joint Surg Am* 70:1479-1483.
- Ruff C, Weingardt JP, Russ PD, Kilcoyne RF. 1998. MR imaging patterns of displaced meniscus injuries of the knee. *AJR Am J Roentgenol* 170:63-67.
- Saygi B, Yildirim Y, Berker N, Ofuoglu D, Karadag-Saygi E, Karahan M. 2005. Evaluation of the neurosensory function of the medial meniscus in humans. *Arthroscopy* 21:1468-1472.
- Schepesis AA, Busconi BD. 2006. *Sports Medicine. Lower Extremity*. Lippincott Williams & Wilkins.
- Scott GA, Jolly BL, Henning CE. 1986. Combined posterior incision and arthroscopic intra-articular repair of the meniscus. An examination of factors affecting healing. *J Bone Joint Surg Am* 68:847-861.
- Scotti C, Pozzi A, Mangiavini L, Vitari F, Boschetti F, Domeneghini C, Fraschini G, Peretti GM. 2009. Healing of meniscal tissue by cellular fibrin glue: an in vivo study. *Knee Surg Sports Traumatol Arthrosc* 17:645-651.
- Seedhom BB. 1976. Loadbearing function of the menisci. *Physiotherapy* 62:223.
- Seedhom BB, Hargreaves DJ. 1979. Transmission of the load in the knee joint with special reference to the role in the menisci: part II. Experimental results, discussion and conclusion. *Eng Med* 8:220-228.
- Sekiya JK, Ellingson CI. 2006. Meniscal allograft transplantation. *J Am Acad Orthop Surg* 14:164-174.
- Sharifah MI, Lee CL, Suraya A, Johan A, Syed AF, Tan SP. 2013. Accuracy of MRI in the diagnosis of meniscal tears in patients with chronic ACL tears. *Knee Surg Sports Traumatol Arthrosc* 17:17.
- Shelbourne KD, Carr DR. 2003. Meniscal repair compared with meniscectomy for bucket-handle medial meniscal tears in anterior cruciate ligament-reconstructed knees. *Am J Sports Med* 31:718-723.
- Shelbourne KD, Klotz C. 2006. What I have learned about the ACL: utilizing a progressive rehabilitation scheme to achieve total knee symmetry after anterior cruciate ligament reconstruction. *J Orthop Sci* 11:318-325.
- Shelbourne KD, Patel DV, Martini DJ. 1996. Classification and management of arthrofibrosis of the knee after anterior cruciate ligament reconstruction. *Am J Sports Med* 24:857-862.
- Shoemaker SC, Markolf KL. 1986. The role of the meniscus in the anterior-posterior stability of the loaded anterior cruciate-deficient knee. Effects of partial versus total excision. *J Bone Joint Surg Am* 68:71-79.
- Shrive NG, O'Connor JJ, Goodfellow JW. 1978. Load-bearing in the knee joint. *Clin Orthop Relat Res* 131:279-287.
- Singson RD, Feldman F, Staron R, Kiernan H. 1991. MR imaging of displaced bucket-handle tear of the medial meniscus. *AJR Am J Roentgenol* 156:121-124.
- Skaags DL, Mow VC. 1990. Function of the radial tie fibers in the meniscus. *Trans Orthop Res Soc* 15:248.
- Skinner HB, Barrack RL, Cook SD. 1984. Age-related decline in proprioception. *Clin Orthop Relat Res* 184:208-211.
- Smillie IS. 1978. *Injuries to the Knee Joint*. Edinburgh and London: Churchill Livingstone.
- Sommerlath KG. 1991. Results of meniscal repair and partial meniscectomy in stable knees. *Int Orthop* 15:347-350.
- Spilker RL, Donzelli PS, Mow VC. 1992. A transversely isotropic biphasic finite element model of the meniscus. *J Biomech* 25:1027-1045.
- Stone KR, Steadman JR, Rodkey WG, Li ST. 1997. Regeneration of meniscal cartilage with use of a collagen scaffold. Analysis of preliminary data. *J Bone Joint Surg Am* 79:1770-1777.
- Subhas N, Sakamoto FA, Mariscalco MW, Polster JM, Obuchowski NA, Jones MH. 2012. Accuracy of MRI in the diagnosis of meniscal tears in older patients. *AJR Am J Roentgenol* 198:W575-W580.
- Sutton JB. 1897. *Ligaments: Their Nature and Morphology*. 2nd Edition. London: Lewis.
- Sweigart MA, Athanasiou KA. 2001. Toward tissue engineering of the knee meniscus. *Tissue Eng* 7:111-129.
- Tardieu C. 1999. Ontogeny and phylogeny of femoro-tibial characters in humans and hominid fossils: functional influence and genetic determinism. *Am J Phys Anthropol* 110:365-377.
- Tardieu C, Dupont JY. 2001. The origin of femoral trochlear dysplasia: comparative anatomy, evolution, and growth of the patello-femoral joint. *Rev Chir Orthop Reparatrice Appar Mot* 87:373-383.
- Taylor SA, Rodeo SA. 2013. Augmentation techniques for isolated meniscal tears. *Curr Rev Musculoskelet Med* 6:95-101.
- Tengrootenhuysen M, Meermans G, Pittoors K, van Riet R, Victor J. 2011. Long-term outcome after meniscal repair. *Knee Surg Sports Traumatol Arthrosc* 19:236-241.
- Thompson WO, Thaete FL, Fu FH, Dye SF. 1991. Tibial meniscal dynamics using three-dimensional reconstruction of magnetic resonance images. *Am J Sports Med* 19:210-215; discussion 215-216.
- Toman CV, Dunn WR, Spindler KP, Amendola A, Andrish JT, Bergfeld JA, Flanigan D, Jones MH, Kaeding CC, Marx RG, Matava MJ, McCarty EC, Parker RD, Wolcott M, Vidal A, Wolf BR, Huston LJ, Harrell FE, Jr, Wright RW. 2009. Success of meniscal repair at anterior cruciate ligament reconstruction. *Am J Sports Med* 37:1111-1115.
- Tuckman GA, Miller WJ, Remo JW, Fritts HM, Rozansky MI. 1994. Radial tears of the menisci: MR findings. *AJR Am J Roentgenol* 163:395-400.
- Vallois H. 1914. *Etude Anatomique de l'Articulation du Genou Chez les Primates*. Montpellier, France: L'Abeille.
- Van der Bracht H, Verdonk R, Verbruggen G, Elewaut D, Verdonk P. 2007. Cell based meniscus tissue engineering. In: Ashammakhi N, Reis RL, Chiellini E, editors. *Topics in Tissue Engineering*.
- van Trommel MF, Simonian PT, Potter HG, Wickiewicz TL. 1998. Arthroscopic meniscal repair with fibrin clot of complete radial tears of the lateral meniscus in the avascular zone. *Arthroscopy* 14:360-365.
- Vanhoenaker FM, Maas M, Gielen JL. 2007. *Imaging of Orthopaedic Sports Injuries*. Berlin Heidelberg: Springer-Verlag.
- Verdonk P, Beaufils P, Bellemans J, Djan P, Heinrichs EL, Huisse W, Laprell H, Siebold R, Verdonk R. 2012. Successful treatment of painful irreparable partial meniscal defects with a polyurethane scaffold: two-year safety and clinical outcomes. *Am J Sports Med* 40:844-853.
- Verdonk PC, Forsyth RG, Wang J, Almqvist KF, Verdonk R, Veys EM, Verbruggen G. 2005. Characterisation of human knee meniscus cell phenotype. *Osteoarthritis Cartilage* 13:548-560.
- Verdonk P, Vererfve P. 2009. Traumatic lesions: Stable knee, ACL knee. In: Beaufils P, Verdonk R, editors. *The Meniscus*. Berlin Heidelberg: Springer-Verlag. p 45-50.
- Verdonk R, Verdonk P, Huisse W, Forsyth R, Heinrichs EL. 2011. Tissue ingrowth after implantation of a novel, biodegradable polyurethane scaffold for treatment of partial meniscal lesions. *Am J Sports Med* 39:774-782.
- Verdonk R, Volpi P, Verdonk P, Van der Bracht H, Van Laer M, Almqvist KF, Vander Eecken S, Prospero E, Quaglia A. 2013. Indications and limits of meniscal allografts. *Injury* 44:S21-S27.
- Ververidis AN, Verettas DA, Kazakos KJ, Tilkeridis CE, Chatzipapas CN. 2006. Meniscal bucket handle tears: a retrospective study of arthroscopy and the relation to MRI. *Knee Surg Sports Traumatol Arthrosc* 14:343-349.
- Villegas DF, Hansen TA, Liu DF, Donahue TL. 2008. A quantitative study of the microstructure and biochemistry of the medial meniscal horn attachments. *Ann Biomed Eng* 36:123-131.
- Voloshin AS, Wosk J. 1983. Shock absorption of meniscectomized and painful knees: A comparative in vivo study. *J Biomed Eng* 5:157-161.
- Walker PS, Erkman MJ. 1975. The role of the menisci in force transmission across the knee. *Clin Orthop Relat Res* 109:184-192.
- Warren RF. 1990. Meniscectomy and repair in the anterior cruciate ligament-deficient patient. *Clin Orthop Relat Res* 252:55-63.
- Watt AJ, Halliday T, Raby N. 2000. The value of the absent bow tie sign in MRI of bucket-handle tears. *Clin Radiol* 55:622-626.
- Wickiewicz TL. 1990. Meniscal injuries in the cruciate-deficient knee. *Clin Sports Med* 9:681-694.

- Wilson AS, Legg PG, McNeur JC. 1969. Studies on the innervation of the medial meniscus in the human knee joint. *Anat Rec* 165:485–491.
- Yan R, Wang H, Yang Z, Ji ZH, Guo YM. 2011. Predicted probability of meniscus tears: comparing history and physical examination with MRI. *Swiss Med Wkly* 141:w13314.
- Yan D, Song Y, Pei F. 2014. Allograft ligament transplantation in anterior cruciate ligament reconstruction patients with meniscal tears. *Arch Orthop Trauma Surg* 30:30.
- Yasui K. 1978. Three dimensional architecture of normal human menisci. *Jpn Ortho Assoc* 52:391–399.
- Zaffagnini S, Marcheggiani Muccioli GM, Lopomo N, Bruni D, Giordano G, Ravazzolo G, Molinari M, Marcacci M. 2011. Prospective long-term outcomes of the medial collagen meniscus implant versus partial medial meniscectomy: a minimum 10-year follow-up study. *Am J Sports Med* 39:977–985.
- Zhang Z, Arnold JA, Williams T, McCann B. 1995. Repairs by trephination and suturing of longitudinal injuries in the avascular area of the meniscus in goats. *Am J Sports Med* 23:35–41.
- Zimny ML. 1988. Mechanoreceptors in articular tissues. *Am J Anat* 182:16–32.
- Zimny ML, Albright DJ, Dabezies E. 1988. Mechanoreceptors in the human medial meniscus. *Acta Anat (Basel)* 133:35–40.
- Zur G, Linder-Ganz E, Elsner JJ, Shani J, Brenner O, Agar G, Hershman EB, Arnoczky SP, Guilak F, Shterling A. 2011. Chondroprotective effects of a polycarbonate-urethane meniscal implant: Histopathological results in a sheep model. *Knee Surg Sports Traumatol Arthrosc* 19:255–263.