J Shoulder Elbow Surg (2018) 27, 1898–1906

Journal of Shoulder and Elbow Surgery

www.elsevier.com/locate/ymse

ELBOW

Major complications after distal biceps tendon repairs: retrospective cohort analysis of 970 cases

Samuel E. Ford, MD[a], Jason S. Andersen, MD[b], David M. Macknet, MD[a], Patrick M. Connor, MD[b], Bryan J. Loeffler, MD[c], R. Glenn Gaston, MD[c,*]

[a]*Department of Orthopaedic Surgery, Carolina Medical Center, Charlotte, NC, USA*
[b]*Shoulder and Elbow Center, Sports Medicine Center, OrthoCarolina, Charlotte, NC, USA*
[c]*OrthoCarolina Hand Center, Charlotte, NC, USA*

Background: The major complication and reoperation rates after distal biceps repair are poorly defined. The purpose of this large retrospective cohort study of distal biceps repairs performed by multiple surgeons within a large orthopedic group was to more clearly define the rates and risk factors of clinically impactful major complications and reoperations.

Methods: All distal biceps tendon repairs performed from January 2005 through April 2017 with a minimum 2-month follow-up were identified using Current Procedural Terminology code 24342. We included 970 patients. The primary outcome measure was the total major complication rate. Reoperations, minor complications, and risk factors were also tracked.

Results: Repairs were performed via a single anterior incision in 652 cases and a 2-incision exposure in 318 cases. A 7.5% major complication rate and 4.5% reoperation rate were observed overall. Major complications occurred at the following rates: proximal radioulnar synostosis, 1.0%; heterotopic ossification or loss of range of motion with reoperation, 0.9%; tendon rerupture, 1.6%; deep infection, 0.5%; posterior interosseous nerve palsy, 1.9%; and complex regional pain syndrome, 0.6%. The 2-incision exposure was identified as a significant risk factor for the development of proximal radioulnar synostosis when compared with single-incision repair techniques ($P = .0003$; odds ratio, 19), occurring in 2.8% of 2-incision exposure cases. Lateral antebrachial cutaneous nerve neuritis or numbness and radial sensory nerve neuritis or numbness were documented more frequently in the postoperative period among patients treated with a single-incision exposure ($P < .0001$ and $P = .034$, respectively).

Conclusions: Distal biceps repair is associated with a 7.5% major complication rate and 4.5% reoperation rate. The use of a 2-incision technique for repair increases the risk of radioulnar synostosis.

Level of evidence: Level III; Retrospective Cohort Design; Treatment Study

Keywords: Distal biceps; proximal radioulnar synostosis; complications; reoperation; rerupture; heterotopic ossification; single incision; two-incision exposure

Repair of distal biceps tendon tears carries a high risk because of the adjacent anatomy. Reported overall complication rates vary widely, ranging from 15%-36%.[1,2,9,10] The most common complication is sensory neuritis involving the lateral antebrachial cutaneous nerve (LABCN) or radial sensory

Institutional Review Board approval was received from Chesapeake IRB (Pro00020921).

*Reprint requests: R. Glenn Gaston, MD, OrthoCarolina Hand Center, 1915 Randolph Rd, Charlotte, NC 28207, USA.

E-mail address: glenn.gaston@orthocarolina.com (R.G. Gaston).

1058-2746/$ - see front matter
https://doi.org/10.1016/j.jse.2018.06.028

nerve (RSN), occurring at a combined rate of 6%-32% depending on the series; these symptoms typically resolve with conservative observation.[2,4,8-11] The risk of major complications associated with distal biceps tendon repair is inadequately defined by the existing literature because of inadequate power. Prior to 2017, no series reporting complications after distal biceps tendon repair had over 200 patients.[2,9] Reported rerupture rates also vary widely, ranging from 1.5%-5.4% among small, single-institution series.[2,4,8,9,14,15]

On the basis of the existing literature, the risk factors for postoperative sensory neuritis, tendon rerupture, and the need for revision surgery are not well defined. Several series have correlated the use of a single incision with higher complication rates, while multiple other studies have contradicted these findings.[2,8,10,11,13,15] Close examination of studies by Grewal et al,[8] Cain et al,[2] and Shields et al[13] shows that higher reported total complication rates with a single incision can be largely attributed to sensory neuropathies.[6] The frequency of less common major complications, including posterior interosseous nerve (PIN) palsy, symptomatic heterotopic ossification (HO), and proximal radioulnar synostosis, is not well documented because of the small size of reported series.[1,2,4,5,7,9-11,15] The purpose of this large retrospective cohort study of distal biceps repairs performed by multiple surgeons within a large orthopedic group was to more clearly define the rates and risk factors of clinically impactful major complications and reoperations.

Materials and methods

A retrospective comparative treatment study was conducted. A query of patients surgically treated by multiple surgeons within a large independent orthopedic group (with >100 surgeons) for distal biceps tendon repair from January 2005 through April 2017 was generated using Current Procedural Terminology (CPT) code 24342 for repair of ruptured distal biceps or triceps tendons. Patients were excluded from the study if they had less than 2 months of follow-up unless a major complication or reoperation occurred, if their injury was open, or if they underwent a distal triceps tendon repair. Chronic tears that required reconstruction with graft augmentation, as well as revision surgical procedures, were included.

The primary outcome variable was the development of a major complication, which was defined as the occurrence of at least 1 of the following: distal biceps tendon rerupture,[2,4,8,9,14,15] deep infection requiring operative intervention, PIN palsy, proximal radioulnar synostosis, symptomatic (painful or range of motion [ROM]–limiting) HO, functional ROM loss treated with surgical intervention (without HO), vascular injury, complex regional pain syndrome (CRPS), or any other postoperative complication or sequela that required reoperation. The treating surgeon diagnosed distal biceps tendon rerupture clinically, often confirming rerupture with magnetic resonance imaging, but no uniform criteria were used to test patients for rerupture. Proximal radioulnar synostosis was defined by the absence of pronosupination on clinical examination in combination with radiographic evidence of bony bridging between the proximal radius and ulna on plain radiographs or computed tomography. This complication was defined as being distinctly separate from nonbridging symptomatic HO, which may be subcutaneously palpable, focally tender, or painful with ROM or may limit terminal supination, pronation, flexion, or extension. Functional loss of ROM with reoperation was separately defined as a limitation in ulnohumeral motion in the absence of HO on radiographs. Deep infection was defined by the clinical need for operative débridement for infection control. PIN palsy was defined as focal weakness in digital and/or wrist extension out of proportion with postoperative weakness related to pain.

Secondary outcome measures included specific rates of major complications and of clinically relevant minor complications, as well as reoperation rates. Minor complications were recorded and included LABCN and RSN paresthesia,[2,4,8-11] postoperative cubital tunnel syndrome, symptomatic (painful or ROM-limiting) HO without repeated operative intervention, and superficial infection not requiring reoperation. Reasons for reoperation were recorded as an additional secondary outcome measure. Sensory neuritis or numbness in the LABCN or RSN distribution was considered clinically meaningful (and included) if symptoms persisted beyond 2 postoperative months.

The following variables were tracked as potential confounding variables: patient age, history of tobacco use,[12] sex, time from injury to surgery, associated injuries (if any), use of postoperative HO prophylaxis,[3] and postoperative rehabilitation details. The use and duration of postoperative rigid immobilization in a nonremovable splint or cast were specifically noted. The subsequent use of a hinged elbow brace or removable rigid elbow orthosis and its duration were also noted. Particular attention was paid to the restriction of terminal extension while in a hinged elbow brace and the time of initiation of active elbow flexion.

Additional operative findings were tracked as potential predictive variables. Tendon ruptures were classified either as full-thickness tears of the tendon from the proximal radius or as partial tears if attenuated or degenerative strands of the biceps tendon remained in continuity with the radial tuberosity, given that mobilization and scarring of a retracted full-thickness tear may predispose patients to a more adverse complication profile. The number of incisions used for exposure of the repair or reconstruction site was tracked as single, meaning an isolated anterior incision, or 2 incisions, indicating the combined use of anterior and dorsal incisions over the proximal forearm. Additional proximal incisions needed for biceps tendon retrieval were not included in this distinction. Single anterior incisions were recorded as either transverse or longitudinal if a determination could be made based on the operative report. The type of fixation was also recorded, including suture or a cortical button in isolation, suture or a cortical button with the addition of an interference screw, interference screw fixation alone, fixation with suture anchor(s), or repair with sutures tied over bone tunnels. Revision repairs were documented, and the use of autograft or allograft tendon for reconstruction of a retracted distal biceps tendon was recorded. The fellowship training of the treating surgeon was categorized as general (no fellowship), sports medicine, shoulder and elbow, or hand surgery.

Postoperative rehabilitation was not standardized and followed the preference of the treating surgeon. The formal distal biceps repair protocol that some surgeons prescribed for postoperative rehabilitation centered on abstaining from active elbow flexion for the first 6 postoperative weeks. Under this protocol, passive, tension-free ROM was advanced under a physical therapist's supervision, often with a brace in place to limit terminal extension. In addition, passive forearm pronation and supination were only allowed with the elbow in a position of 90° of flexion. After 6 weeks of progressive passive

ROM exercises, the hinged elbow brace was discontinued and active flexion was initiated; resisted active elbow flexion was only allowed 3 months after surgery.

Data were collected and stored in an electronic research database (REDCap). Standard descriptive statistics were calculated and reported, including measures of central tendency (mean or median) and variance (standard deviation or interquartile range), as well as frequencies and proportions. For bivariate analyses, the χ^2 or Fisher exact test was used for categorical data (eg, complications between groups) to determine statistical differences. For continuous variables (eg, age), the Wilcoxon rank sum test was used to compare differences between groups. All data were analyzed using SAS Enterprise Guide (version 9.3; SAS Institute, Cary, NC, USA). No data safety monitoring was necessary given the retrospective nature of the study.

Results

In total, 1515 cases were identified during the sample period using the single CPT code. After application of the aforementioned exclusion criteria, a consecutive sample of 970 cases was analyzed. We excluded 269 triceps tendon repairs, billed under the same CPT code, owing to the wrong procedure. An additional 12 patients were excluded after sustaining open biceps tendon ruptures. Finally, 264 patients were excluded because of incomplete records or inadequate follow-up. This series included 956 primary repairs and 14 revisions. Repairs were performed via a single anterior incision in 652 cases and a 2-incision exposure in 318 cases. The average patient age at the time of surgery was 49 years. Of the patients, 97.6% were male and 2.4% were female patients. Median patient follow-up was 3.8 months after surgery (minimum, 2 months; mean, 5.6 months). Sex and patient age were not found to correlate with the major complication, reoperation, or minor complication rate.

Major complications and reoperations

The total major complication rate was 7.5%, with 73 total major complications occurring. Individual major complications, displayed in Table I, occurred in raw frequencies (percentages) within the cohort as follows: PIN palsy, 18 (1.9%); distal biceps tendon rerupture, 15 (1.5%); proximal radioulnar synostosis, 10 (1.0%); symptomatic HO with reoperation, 8 (0.8%); deep infection, 5 (0.5%); CRPS, 6 (0.6%); and loss of flexion-extension arc ROM with reoperation, 4 (0.4%). Tendon reruptures occurred at a mean of 48 ± 38 postoperative days (7 weeks) after surgery.

The overall reoperation rate was 4.5%, encompassing 44 reoperations, the indications for which are detailed in Table II. For the 15 total reruptures in the cohort, 11 revision reconstructions (1.1%) were performed; 4 patients did not undergo revision. A total of 11 reoperations (1.1%) were performed for symptomatic HO or functional ROM loss. As treatment for the 10 patients with proximal radioulnar synostosis, 7 proximal radioulnar synostosis takedown procedures (0.7%) were performed; 2 patients did not undergo synostosis takedown, and a third patient was lost to follow-up after diagnosis of synostosis. All 5 patients in whom deep infections developed underwent operative débridement with or without retention of implants or preservation of biceps tendon repair at the discretion of the treating surgeon. Only 2 patients underwent operative intervention for management of PIN palsy. Two iatrogenic brachial artery lacerations occurred, both requiring intraoperative vascular consultation and immediate repair. Both patients recovered without long-term sequelae due to vascular insult. Two patients who underwent a 2-incision exposure required repeated operative intervention to repair iatrogenic extensor mass fascial dehiscence related to the initial exposure. A final 3 patients underwent 3 subsequent related reoperations: postoperative hematoma evacuation, LABCN

Table I Major complication rates after distal biceps rupture repair or reconstruction

Major complication	n	%
Distal biceps tendon rerupture	15	1.5
Deep infection	5	0.5
PIN palsy	18	1.9
Symptomatic HO with reoperation	8	0.8
Loss of ROM with reoperation	4	0.4
Proximal radioulnar synostosis	10	1.0
Complex regional pain syndrome	6	0.6
Brachial artery laceration	2	0.2
Fascial dehiscence with reoperation	2	0.2
Other	3	0.3
Total	73	7.5

PIN, posterior interosseous nerve; *HO*, heterotopic ossification; *ROM*, range of motion.
The most common complications, in order of decreasing frequency, were PIN palsy, tendon rerupture, and proximal radioulnar synostosis.

Table II Reoperation rates after distal biceps rupture repair or reconstruction

Reoperation indication	n	%
Tendon rerupture	11	1.1
HO or range-of-motion loss	11	1.1
Proximal radioulnar synostosis	7	0.7
Deep infection	5	0.5
PIN palsy	2	0.2
Brachial artery laceration	2	0.2
Extensor mass fascial dehiscence	2	0.2
Persistent neuritis	1	0.1
Other	3	0.7
Total	44	4.5

HO, heterotopic ossification; *PIN*, posterior interosseous nerve.
Reoperations were most frequently performed for tendon rerupture, symptomatic HO and/or range-of-motion loss, and proximal radioulnar synostosis. Conversely, at the time of final follow-up, only 11% of patients with PIN palsy (2 of 18) had undergone reoperation, accounting for most of the difference between major complication and reoperation rates.

Table III Potential risk factors for major complications

Covariate	Overall (n = 961)	Stratified by major complication		*P* value*
		Yes (n = 70)	No (n = 891)	
History of tobacco use, n				.577
Yes	350 (36.4%)	24 (34.3%)	326 (36.6%)	
No	560 (58.3%)	44 (62.9%)	516 (57.9%)	
Sex, n				>.99
Female	23 (2.4%)	1 (1.4%)	22 (2.5%)	
Male	938 (97.6%)	69 (98.6%)	869 (97.5%)	
Associated injury, n				>.99
Yes	21 (2.2%)	1 (1.4%)	20 (2.2%)	
No	940 (97.8%)	69 (98.6%)	871 (97.8%)	
Use of postoperative HO prophylaxis, n				.460
Yes	30 (3.1%)	3 (4.3%)	27 (3.0%)	
No	626 (65.1%)	43 (61.4%)	583 (65.4%)	
Age at surgery, mean (SD), yr	49.1 (9.5)	49.6 (9.2)	49.0 (9.5)	.648
Median time from injury to surgery (IQR), d	18.0 (10-39)	18.5 (10-53)	18.0 (10-38)	.674

HO, heterotopic ossification; *SD*, standard deviation; *IQR*, interquartile range.
A history of tobacco use, sex, the presence of associated injuries or problems, the use of HO prophylaxis, age at the time of surgery, and the time interval between injury and surgery were not found to correlate with major complications—overall and stratified by having had a major complication or not (961 unique medical record numbers/sides – bilateral patients).
* *P* values were determined by either the χ^2 or Fisher exact test for categorical variables, the Wilcoxon rank sum test for non-normally distributed numerical variables, or a 2-sample pooled-variance *t* test for normally distributed numerical variables.

neurolysis, and revision distal biceps reconstruction for persistent pain and weakness without evidence of tendon rerupture.

Regarding confounding variables, patient age, history of tobacco use, sex, associated injuries (if any), and use of postoperative HO prophylaxis were not found to correlate with major complications or reoperations (Tables III and IV). Thirty patients in total received perioperative HO prophylaxis, typically with indomethacin. Neither the major complication rate nor the reoperation rate varied with increased delay between injury and surgery ($P = .67$ and $P = .97$, respectively; Tables III and IV).

With regard to operative variables, analyses of a single- versus 2-incision approach, full versus partial tear morphology, and fixation technique were performed. The use of a single- versus 2-incision approach did not correlate with a difference in the total major complication rate or reoperation rate (Table V). However, the odds of proximal radioulnar synostosis formation was 18.9 times higher with the use of a 2-incision approach for repair than with a single incision for exposure (95% confidence interval, 2.4-150.3; $P = .0003$). Only 1 case of proximal radioulnar synostosis occurred among repairs performed with a single incision. Rates of symptomatic HO or ROM loss, tendon rerupture, and PIN palsy were not found to differ between single- and 2-incision exposures.

Neither the type of tear (full vs partial) nor the fixation method used was found to correlate with total major complications, individual major complications, or reoperation rates (Supplementary Table S1). The use of bone tunnels and suture fixation was found to be associated with a higher rate of proximal radioulnar synostosis ($P = .0016$; Table VI, Fig. 1). Specifically, pair-wise comparisons with Bonferroni adjustment for multiple tests indicated that the proximal radioulnar synostosis incidence differed significantly between bone tunnel fixation and fixation using a suture button with an interference screw ($P = .0217$). Otherwise, fixation type was not found to correlate with other specific major complications. Moreover, the addition of an interference screw to suspensory suture button fixation (554 combined cases) was not associated with a decrease in tendon rerupture incidence versus other fixation types. While 12 cases were completed with interference screw fixation alone, no major complications occurred in this group, and meaningful statistical comparisons with other fixation types are of limited use given the small group size.

At the discretion of the treating surgeon, 38 cases required allograft augmentation for reconstruction for subacute, chronic, and/or revision tears. Allograft augmentation was required for reconstruction of the distal biceps tendon at a median of 8.5 weeks (range, 3-34 weeks) after injury, as compared with a 3-week median time interval between injury and surgery (range, 1-5 weeks) among patients who did not require allograft augmentation for repair ($P < .001$). On univariate analysis, use of allograft was not associated with an increase in major complication and reoperation rates ($P > .99$ and $P = .253$, respectively).

Minor complications

The total minor complication rate for the cohort was 21.5%, consisting predominantly of postoperative sensory nerve

Table IV Potential risk factors for reoperation

Covariate	Overall (n = 961)	Stratified by reoperation		*P* value*
		Yes (n = 47)	No (n = 914)	
History of tobacco use, n				.599
Yes	350 (36.4%)	16 (34.0%)	334 (36.5%)	
No	560 (58.3%)	30 (63.8%)	530 (58.0%)	
Sex, n				>.99
Female	23 (2.4%)	1 (2.1%)	22 (2.4%)	
Male	938 (97.6%)	46 (97.9%)	892 (97.6%)	
Associated injury, n				.619
Yes	21 (2.2%)	—	21 (2.3%)	
No	940 (97.8%)	47 (100.0%)	893 (97.7%)	
Use of postoperative HO prophylaxis, n				
Yes	30 (3.1%)	2 (4.3%)	28 (3.1%)	
No	626 (65.1%)	28 (59.6%)	598 (65.4%)	
Age at surgery, mean (SD), yr	49.1 (9.5)	49.3 (9.6)	49.1 (9.5)	.854
Median time from injury to surgery (IQR), d	18.0 (10-39)	17.0 (8-63)	18.0 (10-39)	.970

HO, heterotopic ossification; *SD*, standard deviation; *IQR*, interquartile range.
A history of tobacco use, sex, the presence of associated injuries or problems, the use of HO prophylaxis, age at the time of surgery, and the time interval between injury and surgery were not found to correlate with reoperations—overall and stratified by having had a reoperation or not (961 unique medical record numbers/sides – bilateral patients).
* *P* values were determined by either the χ^2 or Fisher exact test for categorical variables, the Wilcoxon rank sum test for non-normally distributed numerical variables, or a 2-sample pooled-variance *t* test for normally distributed numerical variables.

Table V Major complication and reoperation rates by single- versus 2-incision exposure

Covariate	No. of incisions, n		*P* value	Odds ratio	95% CI
	Two incisions (n = 318)	Single incision (n = 652)			
Major complication	28 (8.1%)	45 (6.9%)	.292	1.3	0.8-2.1
Reoperation	20 (6.3%)	28 (4.3%)	.179	1.5	0.8-2.7
Tendon rerupture	2 (0.6%)	13 (2.0%)	.164	0.3	0.1-1.5
Proximal radioulnar synostosis	9 (2.8%)	1 (0.2%)	.0003	18.9	2.4-150.3
PIN palsy	6 (1.9%)	12 (1.8%)	.960	1.0	0.4-2.8

CI, confidence interval; *PIN*, posterior interosseous nerve.
No differences were observed, with the number of patients available, in total major complication or reoperation rates based on the number of incisions used for exposure. The use of a 2-incision exposure strongly correlated with an increased incidence of proximal radioulnar synostosis ($P = .0003$; odds ratio, 19).

symptoms in the LABCN (13.0%) or RSN (4.9%) distributions (17.9% combined, with 0.8% occurring in both; Table VII). Other minor complications occurred at lower rates, as detailed in Table VII. The odds of having a minor complication was 1.4 times higher in patients who underwent distal biceps repair more than 15 days after injury (95% confidence interval, 1.1-2.0; $P = .023$). Regarding other potential confounding variables, patient age, history of tobacco use, sex, time from injury to surgery, associated injuries (if any), and use of postoperative HO prophylaxis were not found to correlate with total minor complication rates.

Both LABCN and RSN symptoms were more common in patients treated with a single-incision technique ($P < .0001$ and $P = .034$, respectively), translating into a higher documented rate of overall minor complications after repair or reconstruction using a single-incision technique ($P < .0001$; Table VIII, Fig. 2). The total minor complication rate was found to be higher for patients treated with a single longitudinal incision versus a single transverse incision (32% vs 23%, $P = .017$; Table VIII). However, with the number of cases within the transverse and longitudinal subgroups available for review, significant differences were not found for specific neurapraxia types.

Postoperative rehabilitation

Overall, major complication, reoperation, and minor complication rates were not impacted by prolonged rigid immobilization. However, immobilization for longer than 28 postoperative days correlated with a higher incidence of proximal radioulnar synostosis ($P < .001$, Supplementary Table S2). Analysis of patients treated with a 2-incision technique, specifically, confirms this finding ($P < .001$).

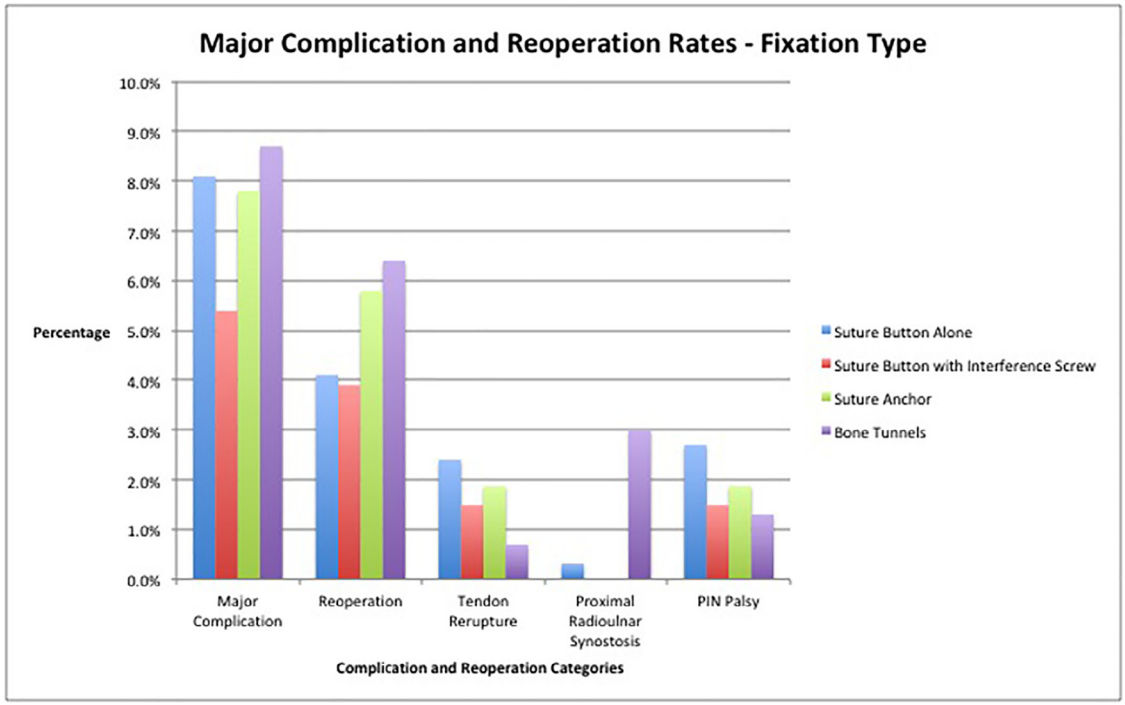

Figure 1 Rates of major complications and reoperations by fixation type. When controlling for exposure, we observed no differences, with the number of patients available, in total major complications, individual major complications, or the reoperation rate based on the type of fixation used for distal biceps repair. *PIN*, posterior interosseous nerve.

Other postoperative rehabilitation variables did not correlate with differences in major complication, reoperation, or minor complication rates. Specific variables examined included initiation of active elbow flexion prior to 3 postoperative weeks, hinged elbow brace or removable splint use for shorter than 4 weeks, and use of a terminal-extension block function on a hinged elbow brace during progression of passive extension. Early active elbow flexion (before 3 weeks), short duration of hinged elbow brace or removable splint use (<4 weeks), and avoidance of a terminal-extension block while using a hinged elbow brace all, specifically, did not correlate with a higher rate of tendon rerupture ($P = .79$, $P = .94$, and $P = .58$, respectively).

Surgeon data

A total of 73 surgeons performed distal biceps repairs during the study period, and no cases were excluded based on surgeon case volume. Fellowship-trained surgeons performed 79% of cases and were most commonly trained in sports medicine (59%), followed by shoulder and elbow (16%) and hand (9%)

Table VI Major complication and reoperation rates by fixation method

Covariate	Fixation type, n				*P* value
	Suture button alone (n = 295)	Suture button with interference screw (n = 259)	Suture anchor (n = 103)	Bone tunnels (n = 298)	
Major complication	24 (8.1%)	14 (5.4%)	8 (7.8%)	26 (8.7%)	.484
Reoperation	12 (4.1%)	10 (3.9%)	6 (5.8%)	19 (6.4%)	.456
Tendon rerupture	7 (2.4%)	4 (1.5%)	2 (1.9%)	2 (0.7%)	.353
Proximal radioulnar synostosis	1 (0.3%)	0 (0%)	0 (0%)	9 (3.0%)	.0016*
PIN palsy	8 (2.7%)	4 (1.5%)	2 (1.9%)	4 (1.3%)	.628

PIN, posterior interosseous nerve.
No differences were observed, with the number of patients available, in total major complications, individual major complications, or reoperation rates based on the fixation method used for distal biceps repair.
* Pair-wise comparisons with Bonferroni adjustment for multiple tests indicated that the incidence of proximal radioulnar synostosis differed significantly between bone tunnel fixation and fixation using a suture button with an interference screw ($P = .0217$).

Table VII Minor complication rates

Minor complication	n	%
LABCN neuritis or numbness	126	13.0
RSN neuritis or numbness	48	4.9
Cubital tunnel syndrome	9	0.9
Lateral epicondylitis	16	1.7
Symptomatic HO (nonoperative)	4	0.4
Superficial infection (nonoperative)	6	0.6
Total	209	21.5

LABCN, lateral antebrachial cutaneous nerve; *RSN*, radial sensory nerve; *HO*, heterotopic ossification.
Consisting mostly of LABCN and RSN neuritis, total minor complication rates were relatively high: 22.9% overall. Postoperative cubital tunnel syndrome and lateral epicondylitis, among other minor complications, may be related to immobilization and postoperative rehabilitation after distal biceps reconstruction, so they were included in the analysis.

surgery. Surgeons without formal fellowship training were more likely to use a 2-incision exposure ($P < .0001$). Surgeons with sports medicine training were 3.7 times more likely than fellowship-trained hand surgeons to use a 2-incision exposure as well ($P < .0001$). No difference in total major and minor complication rates was observed based on surgeons' fellowship training background ($P = .24$ and $P = .15$, respectively).

A surgical volume analysis was performed to examine whether low-volume surgeons, defined as surgeons performing 5 distal biceps repairs or fewer over the study period, had higher major complication and reoperation rates. Seventy cases performed by 31 low-volume surgeons were identified. Cases performed by these surgeons were not found to be at higher risk of major complications and reoperations ($P = .73$ and $P > .99$, respectively).

Discussion

Within this cohort study, major complications and reoperations occurred in 7.5% and 4.5% of cases, respectively. These findings are important to discuss with patients when making shared surgical decisions during the informed-consent process. Specifically, tendon rerupture and PIN palsy occur relatively commonly, create dysfunction for the patient when they occur, and may require reoperation. For patients undergoing repair with a 2-incision exposure, proximal radioulnar synostosis occurred at a rate of 2.8% among 2-incision approaches, which was markedly higher than the rate that occurred with a single incision. Finally, judicious use of rigid immobilization should be carefully implemented and only continued beyond 28 postoperative days under special circumstances, especially after 2-incision repair, as prolonged rigid immobilization increases the risk of proximal radioulnar joint synostosis. In the setting of revision or poor tissue quality, if prolonged immobilization is considered necessary by the treating surgeon, HO prophylaxis with a nonsteroidal anti-inflammatory medication such as indomethacin may be warranted.

Regarding other major complications, it is important to note that the brachial artery is at risk during anterior antebrachial exposure and that iatrogenic injury can occur—twice in this series. Major complication and reoperation rates did not differ by sex, history of tobacco use, age, exposure type (single vs 2 incisions), tear morphology (full vs partial), or type of fixation used. With the number of cases available for review, the tendon rerupture rate did not differ when suture button fixation was augmented with an interference screw, suggesting that fixation augmentation with an interference screw may not be necessary. Similarly, the number of patients in this series (N = 970) was insufficient to endorse the null hypothesis in comparing rerupture rates between the single- and 2-incision cohorts. Power analysis with a target power of 0.80 sets a threshold of 1886 patients necessary to statistically address this issue.

The 21.5% total rate of minor complications was similar to rates reported in prior literature (6%-32%).[2,4,8-11] Sensory nerve distribution symptoms, occurring in 13.0% of patients in the LABCN distribution and 4.9% of patients in the RSN distribution, are inherent to the exposure required for distal biceps repair. Similar to rates reported in prior retrospective literature, the rates of documented LABCN and RSN neuritis are likely an under-representation of the true frequency of symptoms. Surgeons without fellowship training and those with sports medicine training were more likely to perform 2-incision exposures in this series than were surgeons who received shoulder and elbow or hand fellowship training. Surgeons with specific upper-extremity backgrounds could be more cognizant of the peripheral sensory nerve examination, possibly explaining the observed difference in reported LABCN and RSN rates. True LABCN and RSN distribution symptoms may occur at rates closer to those reported in the single-incision exposure cohort, as those cases were more likely to be performed by surgeons with upper-extremity training: 16.1% for LABCN and 5.8% for RSN (21.9% combined, total minor complication rate of 27.6%).

Recently, a 784-patient cohort study was published by Dunphy et al,[6] detailing complications in patients within the Kaiser Permanente system undergoing repair predominantly via a single-incision exposure (81.5%). They reported higher rates of heterotopic bone formation (7.6% vs 2.7%), PIN palsy (3.4% vs 0.8%), and reoperation (8.3% vs 2.3%) after repair with a 2-incision exposure versus single-incision techniques. Proximal radioulnar synostosis was not specifically delineated from other forms of heterotopic bone formation in their series. In total, the rate of HO reported in their series was 3.6% compared with a total of 2.2% in our cohort (proximal radioulnar synostosis in 1.0%, otherwise symptomatic HO with reoperation in 0.8%, and symptomatic HO without operative intervention in 0.4%). It is also unclear what portion of the 3.6% of patients with heterotopic bone formation was symptomatic or required reoperation. PIN palsy and reoperation rates were not found to differ between the single- and 2-incision

Table VIII Exposure-related predictors of minor complications

Covariate	No. of incisions			Type of single incision (n = 652)		
	Two incisions (n = 318), n	Single incision (n = 652), n	*P* value	Transverse (n = 315), n	Longitudinal (n = 221), n	*P* value
LABCN	16 (5.0%)	110 (16.9%)	<.0001	45 (14.3%)	43 (19.5%)	.112
RSN	9 (2.8%)	39 (6.0%)	.034	14 (4.4%)	18 (8.1%)	.075
Total minor	46 (14.5%)	171 (26.2%)	<.0001	72 (22.9%)	71 (32.1%)	.0169

LABCN, lateral antebrachial cutaneous nerve; *RSN*, radial sensory nerve.
The use of a 2-incision technique correlated with a lower reported rate of minor complications ($P < .0001$). Reported rates of both LABCN and RSN symptoms (numbness, tingling, burning, pain, and so on) were dramatically higher among patients treated with single-incision exposures ($P < .0001$ and $P = .034$, respectively). The total minor complication rate was found to be higher for patients treated with a single longitudinal incision versus a single transverse incision (32% vs 23%, $P = .017$).

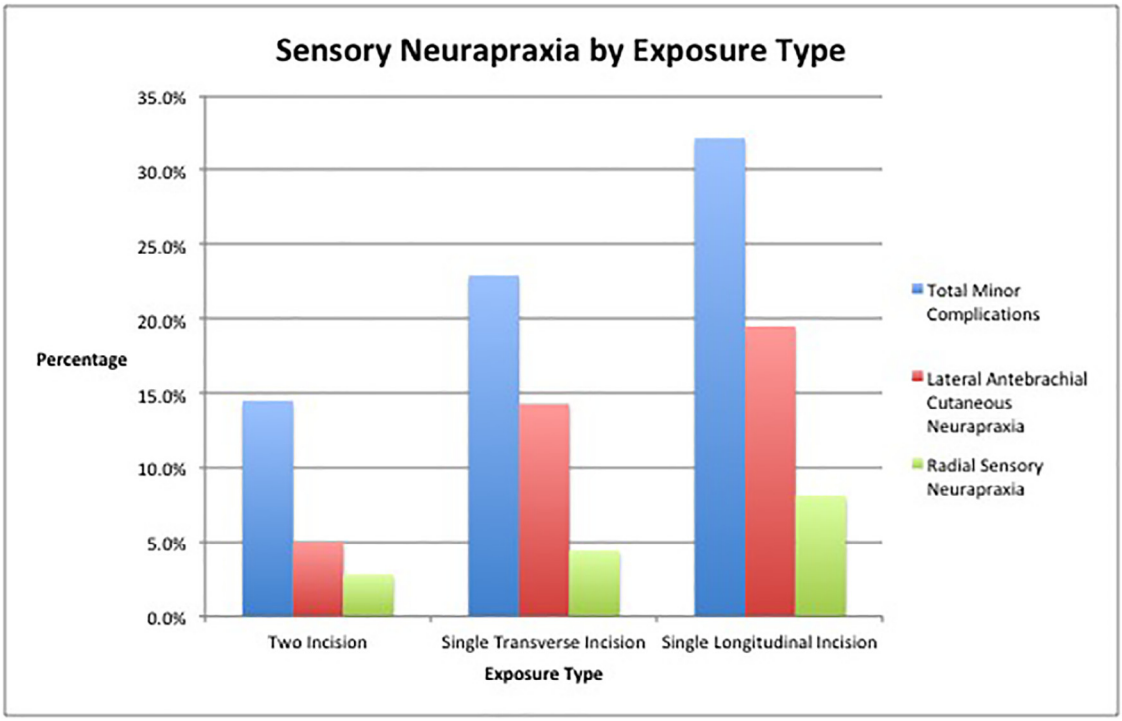

Figure 2 Sensory neurapraxia and total minor complication rates broken down by exposure variables: single incision versus 2 incisions and single transverse versus single longitudinal. Both lateral antebrachial cutaneous nerve neuritis or numbness and radial sensory nerve neuritis or numbness were documented in the medical record more frequently in the postoperative period among patients treated with a single-incision technique ($P < .0001$ and $P = .034$, respectively), translating into a higher documented rate of overall minor complications after repair or reconstruction using a single-incision technique ($P < .0001$). The use of a single longitudinal incision was found to correlate with a higher minor complication rate ($P = .017$), but with the number of cases available for subgroup analysis, a significant difference was not observed specifically within the lateral antebrachial cutaneous nerve and radial sensory nerve subgroups ($P = .11$ and $P = .08$, respectively).

groups with the number of cases available for review in our series.

This study has several strengths. It represents the largest series of distal biceps tendon repairs in the literature, including more than twice as many 2-incision repairs as any other published study. The focus of this series was to define rates of clinically meaningful major complications and reoperations, providing clinicians with a solid reference to stand on when counseling patients preoperatively before distal biceps repair. The cases were performed by more than 70 surgeons within a large community-encompassing private orthopedic group, which makes the results both generalizable and more likely to be inclusive of complications in the event of care transfers.

This cohort study also has several weaknesses. It is retrospective in nature; thus, postoperative examinations were performed at the discretion and specificity of the treating surgeon primarily during the 90-day global postoperative period. Specifically, tendon reruptures may have been missed on postoperative examination by the treating surgeon, and imaging modalities were not used to confirm the structural

integrity of repaired tendons. In addition, as patients did not return to the clinic for a standardized final outcome visit for strength, ROM, and functional outcome score assessment, the full clinical impact of the major complications that occurred was not able to be determined. It is possible that some patients transferred their care outside of this group and their complications that may have led to reoperations may have been missed. Despite the large number of patients in this cohort, for certain analyses, the study was underpowered to confirm the null hypotheses. For example, the tendon rerupture rate did not differ when suture button fixation was augmented with an interference screw, but 1886 patients were needed to generate enough power to confirm this null hypothesis. Postoperative rehabilitation was not standardized for the cohort and was inconsistently documented by the treating surgeons. Finally, the number of patients who received HO prophylaxis in this study was insufficient to make definitive recommendations regarding routine prophylaxis use. A prospectively collected database evaluating functional outcomes, as well as major complications and reoperations, has the potential to better define the impact of distal biceps tendon rupture and repair on patients.

Conclusions

In this large cohort series of distal biceps tendon repair, the total major complication rate was 7.5%. The most common major complications were PIN palsy, 18 (1.9%); distal biceps tendon rerupture, 15 (1.5%); proximal radioulnar synostosis, 10 (1.0%); and symptomatic HO with reoperation, 8 (0.8%). Proximal radioulnar synostosis formation was found to correlate strongly with the use of a 2-incision exposure for repair. In addition, patients immobilized with a rigid splint or cast for longer than 28 postoperative days were placed at higher risk of proximal radioulnar synostosis ($P = .0006$), especially in the 2-incision cohort. To reduce the risk of proximal radioulnar synostosis, a single-incision and ROM exercises with less than 4 weeks of immobilization are recommended.

Acknowledgments

The authors thank Bryce van Doren, MPA, MPH, for assistance with statistical analysis.

Disclaimer

Funding for the study was internal and without commercial or industry support

The authors, their immediate families, and any research foundations with which they are affiliated have not received any financial payments or other benefits from any commercial entity related to the subject of this article.

Supplementary data

Supplementary data to this article can be found online at https://doi.org/10.1016/j.jse.2018.06.028.

References

1. Banerjee M, Shafizadeh S, Bouillon B, Tjardes T, Wafaisade A, Balke M. High complication rate following distal biceps refixation with cortical button. Arch Orthop Trauma Surg 2013;133:1361-6. http://dx.doi.org/10.1007/s00402-013-1819-1
2. Cain RA, Nydick JA, Stein MI, Williams BD, Polikandriotis JA, Hess AV. Complications following distal biceps repair. J Hand Surg Am 2012;37:2112-7. http://dx.doi.org/10.1016/j.jhsa.2012.06.022
3. Costopoulos CL, Abboud JA, Ramsey ML, Getz CL, Sholder DS, Taras JP, et al. The use of indomethacin in the prevention of postoperative radioulnar synostosis after distal biceps repair. J Shoulder Elbow Surg 2017;26:295-8. http://dx.doi.org/10.1016/j.jse.2016.11.011
4. Cusick MC, Cottrell BJ, Cain RA, Mighell MA. Low incidence of tendon rerupture after distal biceps repair by cortical button and interference screw. J Shoulder Elbow Surg 2014;23:1532-6. http://dx.doi.org/10.1016/j.jse.2014.04.013
5. Daluiski A, Schreiber JJ, Paul S, Hotchkiss RN. Outcomes of anconeus interposition for proximal radioulnar synostosis. J Shoulder Elbow Surg 2014;23:1882-7. http://dx.doi.org/10.1016/j.jse.2014.07.011
6. Dunphy TR, Hudson J, Batech M, Acevedo DC, Mirzayan R. Surgical treatment of distal biceps tendon ruptures: an analysis of complications in 784 surgical repairs. Am J Sports Med 2017;45:3020-9. http://dx.doi.org/10.1177/0363546517720200
7. Failla JM, Amadio PC, Morrey BF, Beckenbaugh RD. Proximal radioulnar synostosis after repair of distal biceps brachii rupture by the two-incision technique. Report of four cases. Clin Orthop Relat Res 1990;253:133-6.
8. Grewal R, Athwal GS, MacDermid JC, Faber KJ, Drosdowech DS, El-Hawary R, et al. Single versus double-incision technique for the repair of acute distal biceps tendon ruptures: a randomized clinical trial. J Bone Joint Surg Am 2012;94:1166-74. http://dx.doi.org/10.2106/JBJS.K.00436
9. Hinchey JW, Aronowitz JG, Sanchez-Sotelo J, Morrey BF. Re-rupture rate of primarily repaired distal biceps tendon injuries. J Shoulder Elbow Surg 2014;23:850-4. http://dx.doi.org/10.1016/j.jse.2014.02.006
10. Kelly EW, Morrey BF, O'Driscoll SW. Complications of repair of the distal biceps tendon with the modified two-incision technique. J Bone Joint Surg Am 2000;82:1575-81
11. Recordon JAF, Misur PN, Isaksson F, Poon PC. Endobutton versus transosseous suture repair of distal biceps rupture using the two-incision technique: a comparison series. J Shoulder Elbow Surg 2015;24:928-33. http://dx.doi.org/10.1016/j.jse.2014.12.032
12. Safran MR, Graham SM. Distal biceps tendon ruptures: incidence, demographics, and the effect of smoking. Clin Orthop Relat Res 2002;404:275-83.
13. Shields E, Olsen JR, Williams RB, Rouse L, Maloney M, Voloshin I. Distal biceps brachii tendon repairs: a single-incision technique using a cortical button with interference screw versus a double-incision technique using suture fixation through bone tunnels. Am J Sports Med 2015;43:1072-6. http://dx.doi.org/10.1177/0363546515570465
14. Wang D, Joshi NB, Petrigliano FA, Cohen JR, Lord EL, Wang JC, et al. Trends associated with distal biceps tendon repair in the United States, 2007 to 2011. J Shoulder Elbow Surg 2016;25:676-80. http://dx.doi.org/10.1016/j.jse.2015.11.012
15. Watson JN, Moretti VM, Schwindel L, Hutchinson MR. Repair techniques for acute distal biceps tendon ruptures: a systematic review. J Bone Joint Surg Am 2014;96:2086-90. http://dx.doi.org/10.2106/JBJS.M.00481