Closed intramedullary nailing of femoral fractures. A report of five hundred and twenty cases

RA Winquist, ST Hansen and DK Clawson
J Bone Joint Surg Am. 1984;66:529-539.

Closed Intramedullary Nailing of Femoral Fractures

A Report of Five Hundred and Twenty Cases*

BY ROBERT A. WINQUIST, M.D.†, SIGVARD T. HANSEN, JR., M.D.‡, AND D. KAY CLAWSON, M.D.§, SEATTLE, WASHINGTON

From University Hospital and Harborview Medical Center, Seattle

ABSTRACT: Intramedullary nailing was performed on 520 femoral fractures in 500 patients. The series included eighty-six open fractures and 261 comminuted fractures. Closed intramedullary nailing was used in 497 femora and open intramedullary nailing with cerclage wiring, in twenty-three. The union rate was 99.1 per cent. The range of motion of the knee at follow-up averaged 130 degrees. Complications included four infections (0.9 per cent). Shortening of more than two centimeters occurred in ten patients (2.0 per cent) and malrotation of more than 20 degrees was observed in twelve patients (2.3 per cent). After prompt emergency measures had been taken, routine treatment included strong preoperative traction followed by accurate positioning of the patient on the operating table; selection of the correct insertion point for a properly sized, prebent, flexible, bullet-tipped nail; and accurate reduction of the fracture. Careful rehabilitation of the patient also contributed to the excellence of the results.

In 1940, Küntscher[18] stated that closed intramedullary nailing of the femur offers an ideal anatomical, functional, and physiological treatment for fresh femoral fractures. Subsequent reports of the results in many series have substantiated this statement[1,2,5,6,8,10,17,27,29,34]. At University Hospital and Harborview Medical Center, we began to apply Küntscher's principles in 1968, and we reported our initial results with closed intramedullary nailing in 1971[6]. We have continued to use the procedure extensively, and are presenting our results in a large series of fractures of the femoral shaft treated by intramedullary nailing. We also summarize the preoperative treatment, operative technique, and postoperative management, emphasizing the changes that we have instituted.

Clinical Material

We reviewed a series of 520 fractures of the femoral shaft in 500 patients who were treated by intramedullary nailing at University Hospital and Harborview Medical Center, Seattle, between 1968 and 1979. This consecutive series included the first femoral fracture treated with closed intramedullary nailing at our institution and all subsequent femoral fractures that were managed by this method, including forty-five that were reported on previously[6]. The patients ranged in age from ten years and ten months to ninety-two years old (mean, 29.5 years). There were 347 men and 153 women. One hundred and eighty-seven patients were transferred to our institutions for the operation. Although many staff and resident physicians performed the surgical procedures, we supervised almost all of them.

Eighty-six fractures were open, and the remaining fractures were closed. The soft-tissue injuries were classified as grade I, II, or III, depending on the size of the skin wound and, more importantly, the extent of soft-tissue stripping from bone, reflecting disruption of the external blood supply. There were seventy-six grade-I fractures (small skin wound with minimum or no stripping of soft tissue from bone), eight grade-II fractures (moderate skin and muscle injury with wound contamination), and two grade-III fractures (severe injury with devitalized skin, muscle, and neuromuscular structures threatening the survival of the limb)[9]. In general, patients with a grade-III open femoral fracture were treated by other methods.

The fracture was located in the proximal one-third of the femur in eighty-five limbs, in the middle one-third in 325, and in the distal one-third in 110. There were 124 transverse fractures; 101 short oblique fractures; thirty spiral or long oblique fractures; 261 comminuted fractures, including twenty-six segmental fractures; and four longitudinal fractures.

The comminution of the fractures was categorized as type I, II, III, or IV, depending on the degree (Fig. 1)[35]. In the ninety-two fractures with type-I comminution, only a small piece of bone had broken away. The fifty-four fractures with type-II comminution had a larger butterfly fragment, but the cortex was at least 50 per cent intact, allowing control of rotation and length. In fifty-four fractures with type-III comminution a large butterfly fragment was present, precluding control of rotation or length, or both. There were thirty-five fractures with type-IV comminution; that is, severe comminution with no abutment of cortices at the level of the fracture to prevent shortening.

Injury was caused by a variety of mechanisms: automobile accidents (216 fractures), motorcycle accidents (108 fractures), automobile-pedestrian accidents (seventy-nine fractures), and miscellaneous causes (twenty-three fractures). Thirty-five fractures were sustained in a fall from a height and twenty-two, from a fall at home. Twenty-one

* Read in part at the Annual Meeting of The American Academy of Orthopaedic Surgeons, New Orleans, Louisiana, January 23, 1982.

† 901 Boren, Suite 1600, Seattle, Washington 98104.

‡ Department of Orthopaedics, University of Washington, Seattle, Washington 98195.

§ University of Kansas Medical Center, 2A, 39th and Rainbow Boulevard, Kansas City, Kansas 66103.

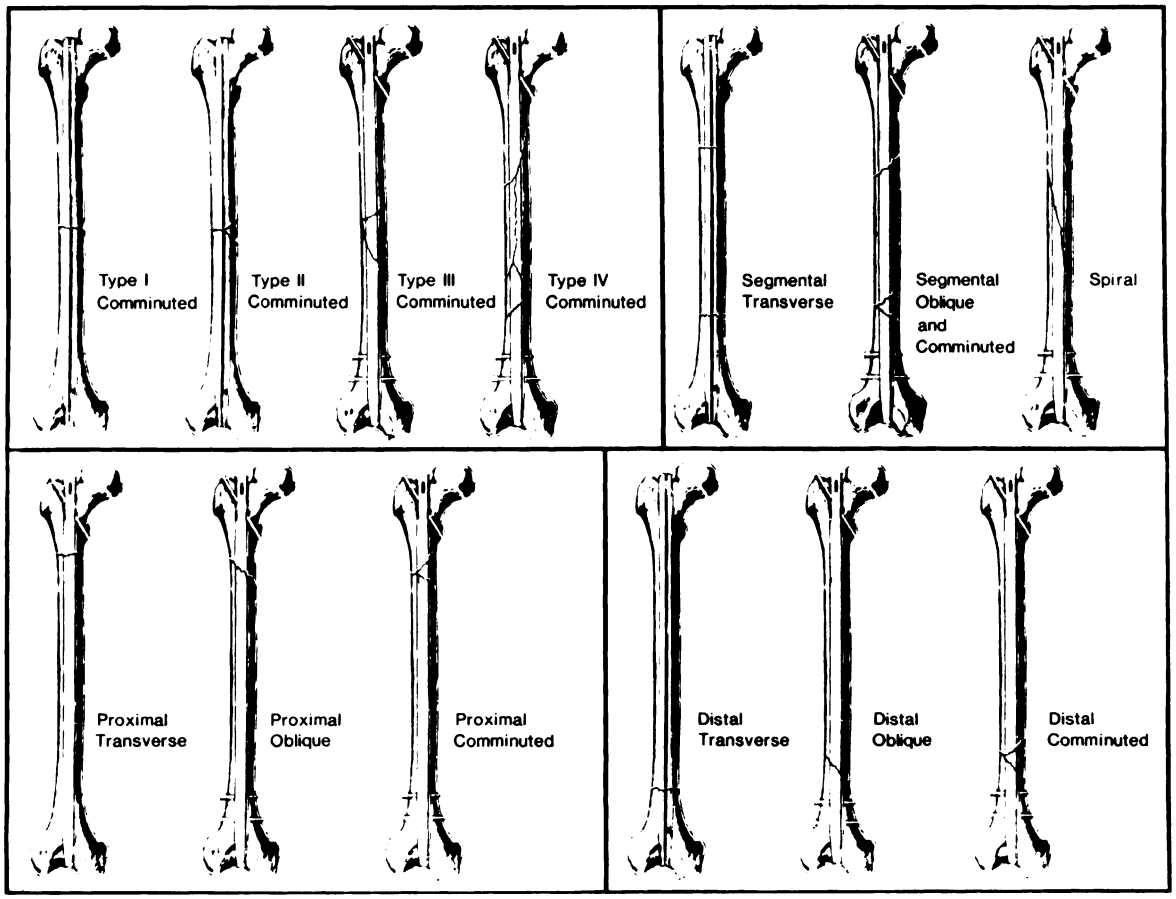

FIG. 1

The types of comminuted fractures are illustrated. Our recommended treatment method (standard intramedullary nail or interlocking nail) for femoral fractures of various patterns is also indicated.

fractures were sustained in sports activities; twelve, in a bicycle accident; and four were a gunshot wound.

Associated injuries were extremely common and played an important part in the determination of initial treatment of the fracture and in the rehabilitation of the patient. One hundred and forty-three patients had injuries to the head, chest, or abdomen. Twenty-seven had a bilateral femoral fracture; fifty-four had ipsilateral femoral and tibial fractures; and twenty-seven had an ipsilateral fracture of the hip, including femoral neck and intertrochanteric fractures. Eighteen had an ipsilateral patellar fracture and twenty-three sustained significant ipsilateral ligament injuries of the knee. Only twelve patients had an associated arterial injury and only ten had an associated nerve injury.

Methods

Preoperative Treatment

Emergency care was given, with special attention to cardiopulmonary status, abdominal status, and the status of the central nervous system. Roentgenograms of the injured femur were then made, as well as routine roentgenograms of the pelvis and ipsilateral knee. Examination of the knee for points of tenderness allowed detection of related ligament injuries. The arterial status of the lower limb was analyzed carefully, particularly when the fracture was in the distal one-third of the femur. The patient was then placed in skeletal traction in the emergency room. Usually balanced suspension traction was used because it provided greater comfort for the patient, but fixed traction was applied if the patient had to be transported. We used rather strong traction, ranging from twenty-five to thirty-five pounds (eleven to sixteen kilograms) in women and from thirty-five to forty-five pounds (sixteen to twenty kilograms) in men. Sufficient traction was applied to restore normal femoral length or to slightly distract the fracture. Lateral roentgenograms were made to ascertain the adequacy of the traction because anteroposterior roentgenograms can lead to a false measurement of distraction[10].

Early in the series, the need for preoperative distraction of the fracture was not sufficiently appreciated. Experience showed, however, that when the fracture was allowed to shorten, reduction became extremely difficult. Thus, we began to emphasize traction as a vital part of the delayed procedure. We prefer to gain slight distraction preoperatively on the hospital ward and to use minimum traction during operation.

Although we used prophylactic antibiotics routinely, we changed the drug regimen during the period of the study. Initially, we gave methicillin and kanamycin twelve hours preoperatively and seventy-two hours postoperatively[6], but

later we changed to a cephalosporin, with one dose administered one hour before operation and four doses given during the twenty-four hours after operation.

As emphasized in our previous report[10], roentgenograms of the normal femur were made at a tube-to-plate distance of one meter, using an ossimeter to allow accurate measurement of the length of the femur and the width of the medullary canal. These measurements allowed the physician to anticipate the appropriate size of the nail. The normal femur was measured from the tip of the trochanter to the lateral joint-line of the knee because this measurement gave the most accurate determination of length. The initial roentgenograms were also used to determine the correct insertion point for the nail in the region of the trochanter.

The timing of the operation was considered carefully for each patient. Initially we delayed the operation for five to seven days, as had been emphasized in previous reports[4,6,19,20,31]. One advantage of this delay was an increased rate of union[4,20,31]. A second advantage, emphasized by Küntscher[19] and by Clawson et al.[6], was that the danger of development of a fat-embolism syndrome was past. A third advantage was that the surgeon and operating-room team had additional time to consider and prepare for the individual patient. After we had gained extensive experience with multiply injured patients, however, it became evident that there was an advantage to immediate stabilization of the femoral fracture so as to provide better initial treatment and decrease the mortality rate[3,11,28]. Because the condition of the multiply injured patient tends to worsen two to three days after injury rather than to improve, prompt stabilization of the fracture or fractures decreases further blood loss and injury to the soft tissues and allows earlier mobilization of the patient with chest and abdominal injuries. When a patient had an associated head injury we performed closed intramedullary nailing as early as possible.

The potential for development of a fat-embolism syndrome was an important consideration in the timing of the operation. Patients with multiple injuries, including those with more than one long-bone fracture, were observed routinely for twenty-four hours in an intensive-care unit, with frequent monitoring of blood gases and if necessary administration of proper pulmonary support. In our early experience with delayed nailing of 250 acute fractures, we did not have a single patient with clinically significant fat embolism postoperatively, and therefore we concluded that the nailing contributes very little to the chance of fat embolism[28]. Because the onset of a fat-embolism syndrome generally occurs twelve to thirty-six hours after injury, we now prefer either to perform the nailing immediately or to delay the operation for five to seven days. The effects of hemorrhage and muscle spasm, which are maximum in the intervening three to four days, make closed reduction technically difficult during that interval.

Our treatment for patients with an open fracture changed somewhat with experience. At the beginning of the series, we treated all open fractures with primary débridement, wound closure approximately seven days after injury, and intramedullary nailing at an average of fourteen days after injury. Later in the series, we performed primary cerclage wiring of butterfly fractures at the time of the initial débridement, but continued to delay intramedullary nailing for approximately fourteen days. Our approach by the end of the series was to perform primary débridement and immediate internal fixation with an intramedullary nail in all grade-I and grade-II open femoral fractures, leaving the wound open with an antibiotic coverage[32], and closing the wound after five to seven days. A further change in the care of patients with an open fracture was the recognition that nutrition plays a vital role in rehabilitation; nutritional needs are now analyzed, met routinely, and followed carefully.

At the beginning of the series we considered the minimum age for treatment with intramedullary nailing to be sixteen years, but in 1973 we began to lower the age-limit. Between 1973 and 1979, closed intramedullary nailing was performed in thirty femoral fractures in twenty-eight patients ranging in age from ten years and ten months to fifteen years and seven months old. In fourteen patients, fusion of the epiphysis was evident roentgenographically; in the other fourteen, the length of the nail was selected to ensure that the nail did not penetrate the distal femoral epiphysis.

Operative Treatment

The operative technique has been modified slightly since the time of our first report[6]. The modifications include: (1) a change in the position of the patient on the fracture-table, (2) a change in the insertion point for the nail in the region of the trochanter, (3) a decrease in the amount of reaming, and (4) a change from the original straight Küntscher nails to pre-bent nails.

Early in the series, when we positioned the patient on the fracture-table we allowed the uninvolved lower limb to drop into wide abduction, but this position was awkward for the patient and impeded the surgeon's view of the limb to be operated on. In 1974 we began to place the uninvolved lower limb in a straight line with the body, and the hip of the injured extremity was placed in slight flexion and slight adduction with straight traction. If strong traction was required or if the fracture was distal, a small Kirschner pin was placed in the distal part of the femur at operation, the knee was flexed, and traction was applied through the femoral pin to prevent stretching of the sciatic nerve.

We strongly prefer to place the patient in the lateral position[10]. Even now we use the supine position occasionally, but only to avoid multiple positionings for the multiply injured patient or to facilitate retrograde intramedullary nailing in ipsilateral fractures of the femoral neck and shaft. We have found, however, that the supine position poses more technical difficulties than does the lateral position with regard to insertion of the nail, particularly with more complex fractures.

During the study period a variety of fracture-tables and image intensifiers were used, and it became apparent that the two must function well together and that the orthopaedist must be familiar with both. The table that has been used

during the last few years has a perineal post that can be offset distally. This table also allows traction during operation and easy access with an image intensifier. We switched to an image intensifier that is smaller and more mobile than the older units, allows better visualization of the fracture site, and has image retention, which markedly decreases radiation exposure.

When the patient was placed on the table, the perineal post was swung distally to allow visualization of the trochanter in the anteroposterior and lateral planes. The axilla was supported to prevent neural injury. The uninvolved lower limb was then placed in traction in a straight line with the body. The testes were allowed to hang free. The thigh on the side that was not to be operated on was carefully supported, either by raising the pelvic pad or by lowering the perineal post. This support prevented venous congestion of the involved extremity and abduction of the proximal fracture fragment by the perineal post.

After the patient was positioned on the table, correct positioning of the fragments with reference to rotation was essential. We originally arranged the limb so that the patella was parallel to the floor, but unfortunately this practice led to external rotation at the fracture site in several patients[22]. In subsequent patients we rotated the limb gently inward and outward to achieve the proper rotational position through relaxation of the soft tissues. Careful attention to the skin folds then allowed us to detect excessive tension from internal or external rotation. This method proved to be both accurate and easy.

The closed reduction required an experienced unscrubbed surgeon who participated actively throughout the operation. First, he or she examined the preoperative anteroposterior and lateral roentgenograms carefully to determine the direction of reduction of each fragment. Traction was then applied to allow the appropriate length to be gained. The surgeon had to take care to avoid excessive traction, which would have pulled the soft tissues too tightly, making the reduction even more difficult, and also would potentially have jeopardized the peroneal nerve by stretching it. After studying the roentgenograms, the unscrubbed surgeon performed the reduction by applying localized pressure just proximal and distal to the fracture with either leaded gloves or rings. He or she checked the reduction with anteroposterior fluoroscopy and held it carefully, converting to lateral fluoroscopy to ascertain that the reduction had been achieved. At this point the surgeon had to think in three dimensions rather than continuing to work in a single plane. The feasibility of reducing the fracture was ensured and the mechanism of reduction was ascertained before the patient was prepared and draped.

A rotatory manipulation was frequently required, and occasionally an increased angulation was needed[10], before reduction of oblique fractures could be achieved. In proximal fractures, an intramedullary nail was inserted in the proximal canal during operation to aid the reduction. We considered proximal fractures to be suitable for intramedullary nailing if they were at least 2.5 centimeters distal to the trochanter[19,27]. In more distal fractures a femoral traction pin was inserted anteriorly just proximal to the adductor tubercle to allow reduction of the distal fragment, which was being pulled posteriorly by the gastrocnemius muscles and posterior part of the capsule. The pin was drilled from inferomedial to superolateral to allow us to pull the fracture out of valgus angulation. The knee was then flexed to allow the gastrocnemius muscle and posterior part of the capsule to relax, and traction was applied through the femoral pin. The foot was placed on a Mayo stand, which was raised or lowered to control rotation. For intramedullary nailing of distal fractures we prefer that there be at least ten centimeters of intact bone above the intercondylar notch.

Obtaining the correct point of insertion on the trochanter is the most important feature of the operative portion of treatment. Küntscher[19] and Müller et al.[24] advised the selection of a point on the lateral aspect of the trochanter to reduce the risk of intracapsular infection and avascular necrosis of the femoral head. We followed this advice early in our series. Unfortunately, because that point is so far lateral to the axis of the medullary cavity, eccentric reaming and comminution of the fracture site frequently occurred in the medial part of the femoral cortex during insertion of the nail, particularly in the more proximal fractures. Thus, we have chosen an insertion point in the piriformis fossa just medial to the body of the trochanter and posterior to the gluteus medius muscle. We now check this point carefully with anteroposterior and lateral fluoroscopy before proceeding further with the operation. Inspection of this point under both anteroposterior and lateral image intensification — probably the most important technical aspect of the operation — ensures that the insertion point is accurate.

After insertion of a sharp awl, a T-handled hand-drill was used to penetrate the proximal metaphyseal bone. A bulb-tipped guide with a slight bend was inserted. The bend, which is essential for closed reduction, is only two centimeters from the end of the bulb to allow passage around corners. The bulb-tipped guide was moved gently down to the fracture site. The unscrubbed surgeon reduced the fracture, and the scrubbed surgeon lined up the bulb-tipped guide approximately. Both surgeons remained still while the image intensifier was switched to a lateral plane. Minimum adjustments were made, and the bulb-tipped guide was inserted with light tapping of a mallet. If the reduction was in question, both views were checked repeatedly until the bulb-tipped guide was successfully placed in the distal fracture fragment. The guide was then moved down to the subchondral bone of the distal part of the femur, and its length was measured to provide a final determination of the length of the nail.

The reaming was started with an eight or nine-millimeter end-cutting reamer. During each passage of a reamer across the reduced fracture site, careful monitoring of the reduction was required to prevent eccentric reaming. The size of the reamers was progressively increased by one millimeter in diameter until the surgeon felt that the reamer was in contact with the cortex. The reaming then progressed

by one-half-millimeter increments. It was essential that the bulb-tipped guide remained centrally placed and that the reduction remained accurate. Observation of the fracture with both anteroposterior and lateral fluoroscopy prevented excessive thinning of the cortex. The bulb-tipped guide was held during reaming to prevent it from backing out, and the surgeon was careful to keep sponges and gloves from being wrapped up in the reamer.

Early in the series we reamed the cortex to the thickness necessary for obtaining a 2.5-centimeter (one-inch) length of contact between the nail and the cortical wall both proximal and distal to the fracture. Often the cortex was reamed to as much as one-half of its original thickness. We found that this reaming was excessive, however, because it necessitated the use of a nail with a larger diameter, which increased the tendency toward comminution of the fracture, with a resultant loss of stability. Later we tended to ream the cortex at the isthmus of the medullary canal for only one to three millimeters at the most and to use smaller nails. From our original average nail diameter of sixteen millimeters in men and 14.5 millimeters in women, we switched to an average diameter of 14.5 millimeters in men and 13.5 millimeters in women. This change seemed to prevent further comminution of the fracture fragments during driving of the nail.

We frequently over-reamed the proximal fragment by 0.5 millimeter, except in fractures of the proximal one-third of the femur. Breakage of the reamer was not uncommon in our experience; removal of the bulb-tipped guide allowed retrieval of the broken reamer. Occasionally a reamer jammed as it was backed out, particularly if a small comminuted fragment had been pulled up from the fracture site into the isthmus, where it blocked extraction of the reamer. In that event, a small guide was passed alongside the reamer to push the fragment down to the fracture site and allow the broken reamer to be extracted.

Although we always tended to use flexible cloverleaf Küntscher nails, the technically improved versions were employed as they became available. The cloverleaf nail that was used initially was straight, with a blunt tip. Because the shape of this nail did not match the contour of the femur, its use led to splitting and further comminution of the bone. We then changed to a pre-bent nail with a bullet tip. The pre-bent aspect of this nail decreased the incidence both of splitting and of further comminution of the femur, and the bullet tip allowed easier passage across the fracture site. At the end of the study period we switched to a pre-bent cloverleaf nail with a conical tip, which further facilitated passage of the nail across the fracture site. This nail extends the full length of the femoral canal down to subchondral bone and is twelve millimeters in diameter or more.

After reaming, we inserted a larger nail-driving guide to help keep the nail central in the canal. Again, as the nail passed the fracture site, accurate reduction was necessary to prevent comminution of bone. Supporting the fracture during final driving of the nail was important, particularly in distal fractures. Once the nail was in position, the wound was closed and the patient was transferred to a regular bed, where the traction pin was removed and the knee ligaments were examined carefully[26]. Rotation of the extremity was also checked, and if it was not accurate the patient was turned to a prone position and attempts were made to correct it. The lower limb was then set gently in an antirotational splint.

For fractures requiring cerclage wiring, such as type-III or IV comminuted fractures, the patient was also placed in the lateral position on the fracture-table and the lateral aspects of the hip and thigh were prepared with iodine alcohol down to the knee to allow lateral exposure of the femur if open reduction became necessary. The fracture was approached through a lateral incision, and the cerclage wire was applied to the fragment before reaming was begun. The nailing was then performed in a manner similar to that already described.

Postoperative Management

After the operation the patient was taken to the recovery room and received blood transfusions only if necessary. Quadriceps muscle-setting exercises and straight leg-lifting were begun on the morning after operation. As soon as the patient had control of the extremity, he or she was allowed to begin walking with crutches and protected weight-bearing. The patient was encouraged to use the crutches for at least six weeks, until good control of the quadriceps muscle had been obtained.

An important change that was made in postoperative management was an increased emphasis on quadriceps rehabilitation after the patient's discharge from the hospital. Early in our series, the patient was discharged from the hospital while still using crutches, and little attention was given to continuing rehabilitation. Later we came to realize that it was important for the patient to work with a physical therapist for about three months to strengthen the quadriceps and to regain motion of the knee more rapidly. After the hospitalization period, quadriceps muscle rehabilitation consisted only of straight leg-lifting with weights and was carefully supervised for at least three months[25]. Range-of-motion exercises of the knee were given minimum attention for the first four to six weeks. Once the patient had gained 90 degrees of knee motion, he or she attempted to gain complete knee flexion with an exercise that involved sitting back gently on the heels from a kneeling position. Patients with severe quadriceps-muscle injury or with inflammatory callus that looked similar to myositis were not encouraged to pursue the exercises for range of motion of the knee too vigorously because early manipulations caused increased inflammation and provided only a transient gain in motion. These patients required a longer period to obtain knee motion, but with gentle work and patience they continued to gain motion over four or five months. Toward the end of the series, the patients were tested on an isokinetic muscle-training machine (Cybex II) whenever possible to obtain an objective measure of the level of rehabilitation.

Postoperative traction or a spica cast was sometimes

required for patients with a somewhat unstable fracture or who were considered to be unreliable[35]. Occasionally, a patient with a distal fracture was kept non-weight-bearing with a cast-brace postoperatively. This treatment was generally continued for four to six weeks, after which partial weight-bearing was allowed. In patients with a slightly comminuted fracture, such as a type-II injury, toe-touch weight-bearing was prescribed for the first six weeks.

The protocol for preventing pulmonary embolism in our patients was to prescribe aspirin and to have the patient begin walking as soon as possible.

Our routine for removal of the nail was limited to young people, and the procedure was done one year or more after injury, as convenient. Removal of the nail required planning and appropriate equipment but tended to be relatively simple. In our series we removed 169 nails and did not encounter any that could not be removed. The patients were allowed unlimited weight-bearing without crutches after removal of the nail. No stress fractures of the femoral neck or shaft occurred.

Results

The patients' progress was followed by means of clinical examinations and roentgenograms by us and by the referring physicians. Forty-seven patients were lost to follow-up, and eleven died within one year of injury. The other 442 patients were followed for at least one year.

Of the eleven patients who died within a year of injury, one did so two months after injury from complications of severe brain trauma; five died from associated multiple injuries; three patients, averaging seventy-five years old, died in a nursing home two, six, and nine months after injury; and the remaining two patients died of causes unrelated to the injury. No death was directly related to the femoral fracture.

The average time from injury to nailing was seven days. Forty-one nailing procedures were performed acutely in patients with an open fracture or in multiply injured patients. We tended to perform more acute nailing procedures as the series progressed. For patients with an isolated femoral fracture, the average hospital time was 13.3 days, the time before walking with crutches was begun averaged 3.2 days after operation, and the time on crutches averaged 5.8 weeks. For multiply injured patients, the total hospital time averaged 26.9 days.

The time to bone union, as determined from roentgenograms, was difficult to ascertain. According to our judgment, 87 per cent of the fractures appeared to be solidly united at three months. The operating time for individual patients decreased during the study period and was approximately an hour by the end of the series. Because of associated blood loss from the injury, the blood loss attrib-

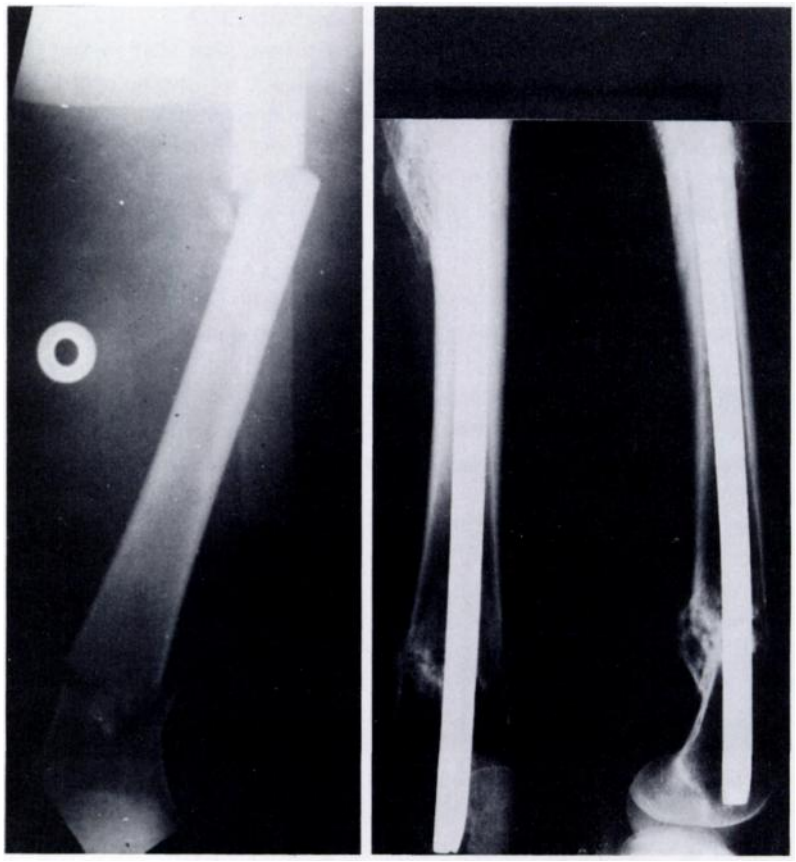

FIG. 2-A FIG. 2-B

Fig. 2-A: A twenty-six-year-old man sustained a segmental fracture of the femur in a fall from a power pole.
Fig. 2-B: Eleven months after injury the bone has united.

utable to the operative procedure itself was difficult to determine, but it was about one and one-half to two units, including losses from reaming and subsequent bleeding at the fracture site.

In patients who were younger than fifty years, the average diameter of the nail was 13.3 millimeters in women and 14.6 millimeters in men. In both men and women who were older than fifty years, the average diameter of the nail was 16.0 millimeters. The incidence of significant injuries to the knee ligaments was 9.0 per cent[26].

The postoperative range of motion of the knees was excellent, averaging 132 degrees (Figs. 2-A and 2-B). Only thirteen patients had knee flexion of less than 125 degrees; the least amount of flexion was 90 degrees, in a patient with an ipsilateral tibial fracture. Two patients attained 100 degrees of flexion; three patients, 105 degrees; four, 110 degrees; and three, 115 degrees.

Complications

Despite the closed nailing technique and careful management of the open fractures, there were four infections in the series, giving an infection rate of 0.9 per cent.

One infection developed around a closed fracture in a forty-three-year-old chronic alcoholic who had had previous infections in multiple areas. Unfortunately, prophylactic antibiotics were not administered, and this oversight may have had a role in the development of the infection. The nailing itself was technically faultless, but two months after operation a serious wound infection and pain developed about the hip. The patient's sedimentation rate was 105 millimeters per hour. Both the fracture site and the site at the proximal end of the nail were decompressed, and *Staphylococcus aureus* was grown on culture. The wounds were packed, a larger nail was inserted (because the original nail was backing out)[14,21], and antibiotic treatment was begun. Healing was uneventful, and the nail was removed one year later. At nine years of follow-up the patient had not had a recurrence.

The second infection was in a patient with an open fracture that was debrided routinely. A delayed closure was performed after one week, at which time the wound appeared clean. The fracture was nailed fourteen days after injury, and again the wound appeared benign. Two weeks after nailing a fever developed and there was erythema about the wound. The wound was drained again at the fracture site and at the proximal end of the nail, and *Clostridium perfringens* was grown on culture. The patient was treated with antibiotics and wound dressings. The fracture proceeded to union, and the nail was removed one year later. Although spores were seen in the specimens taken at the time of nail removal, the infection did not recur in four years of follow-up.

The third infection developed in a nineteen-year-old woman with multiple injuries, including a grade-I open, split segmental fracture of the right femur. Intramedullary nailing and cerclage wiring of the fragments was performed several days after débridement of the wound. The fracture fragments had no soft-tissue attachments. Six weeks after nailing, a fever developed and there was marked swelling of the thigh. Cultures grew *Enterococcus cloacae*. The fracture was again debrided and drained, and the proximal end of the nail was decompressed. Serial dressing changes were performed. After further healing of the bone, the nail was removed and a large sequestrum was debrided. A Wagner external-fixation device was applied, and open cancellous bone-grafting was performed. At four-year follow-up examination the patient had solid bone union, no signs of infection, and 135 degrees of knee flexion.

A fourth infection was seen in a fifty-seven-year-old man with chest and abdominal injuries and multiple fractures of long bones. He underwent closed intramedullary nailing of a closed femoral fracture and an infection developed after he had a gram-negative septicemia related to the abdominal injuries. After débridement of the fracture site and decompression of the nail, the wound healed without any sign of subsequent infection.

There were four patients with non-union, an incidence of 0.9 per cent for the series[11]. One non-union occurred in a seventy-three-year-old woman with a grade-II open fracture in the distal one-third of the femur. The wound was debrided and intramedullary nailing was performed immediately. The wound healed uneventfully, but nine months after the injury the patient still had slight aching at the fracture site; roentgenograms showed a non-union. The nail was replaced with a larger one, and four months later the bone appeared to have united.

The second non-union occurred in an eighteen-year-old woman whose injuries included a massively swollen thigh and a split segmental fracture of the femur. The fracture was nailed two weeks after injury, and despite attempts to maintain the length of the femur by traction, shortening occurred. The nail was reinserted but again shortening became evident despite the application of thirty-five pounds (sixteen kilograms) of traction, and the nail was again reinserted. At three months the fracture was still tending to shorten even with twenty-five pounds (eleven kilograms) of traction, and it was thought that the fracture was not healing in a satisfactory position. Therefore the fracture was exposed surgically, cerclage wiring was applied, and re-nailing and bone-grafting was performed. The patient was considered to have had a non-union despite the fracture's progress to union after this treatment.

The third non-union occurred in a sixty-seven-year-old man who had had a plate inserted in the femur for a fracture at the age of seven years and had sustained a stress fracture distal to the plate sixty years later. That fracture was treated with closed intramedullary nailing, but it failed to unite and required subsequent treatment.

A fourth non-union occurred in a sixty-three-year-old man with multiple injuries, including a contralateral above-the-knee amputation. Nailing of the open femoral fracture posed no technical problems. The patient was not permitted to bear weight for four months, but at eleven months the femur still had not healed. We removed the nail and inserted

a larger one using closed technique, and the bone subsequently united.

Shortening of more than two centimeters occurred in ten (2 per cent) of the patients. The maximum amount of shortening was 5.0 centimeters, in a patient with a split segmental type-IV comminuted fracture. The patient refused postoperative traction and signed out of the hospital against medical advice. Shortening of 2.8 to 4.0 centimeters occurred in three other patients with a type-IV comminuted fracture and in three with a fracture that was comminuted during intramedullary nailing. Shortening of 3.0 to 4.5 centimeters occurred in two fractures that became comminuted when the patients fell at home after discharge from the hospital. Also, one patient with a type-I comminuted fracture of the proximal one-third of the femur had 2.5 centimeters of shortening. Three patients had shortening of 2.1 to 2.4 centimeters.

Shortening of 1.0 to 2.0 centimeters occurred in thirty-seven limbs (7.1 per cent), primarily in patients with a type-II (five of fifty-four), type-III (eight of fifty-four), or type-IV (eight of thirty-five) comminuted fracture and in elderly patients with a spiral fracture (nine of thirty). Shortening rarely occurred in patients with a type-I comminuted fracture (two of ninety-two), a segmental fracture (three of twenty-six), or a fracture with stable pattern[34] — that is, a short oblique (three of 101) or a transverse fracture (none of 128).

Patients with 2.0 centimeters of shortening or less rarely had any limb or back pain[30,36]. Our present guidelines are to accept 1.5 centimeters of shortening in young patients and as much as 2.5 centimeters of shortening in most patients who are more than sixty-five years old, particularly if the fracture is spiral.

We used open reduction and cerclage wiring in twenty-three patients to obtain rotational stability and regain length, and we used postoperative traction in thirteen to maintain length.

External rotational malunion (10 degrees or more) occurred in forty-three patients, and in twelve of them the deformity was more than 20 degrees. One patient had 60 degrees of deformity, two had 45 degrees, and six had 30 to 40 degrees. Internal and external rotation was measured by a goniometer with the patient prone and the knee flexed 90 degrees. It is interesting that five of the twelve patients with the greatest rotatory deformity had a fracture of the proximal one-third of the femur, whereas the maximum rotatory deformity in any distal fracture was 20 degrees. There were no internal rotational deformities. Seven patients had pain in the knee and an awkward gait because of the deformity. Two of these patients, in whom the deformity was detected before union of the fracture, had manipulation under anesthesia to align the bones before they united. The deformities (60 and 45 degrees) were corrected. Three patients required closed intramedullary derotation osteotomy; their deformities measured 20, 30, and 45 degrees. Two other patients, with 30 and 40 degrees of deformity, were symptomatic but decided not to undergo surgical correction.

There were five causes of rotatory malunion in the patients in our series, and often there was more than one cause in a particular patient.

1. Early in the series, external rotational deformities were produced by the position of the patient on the operating table, with the patella parallel to the floor. This problem was eliminated when we permitted the lower limb to rotate freely and determined the correct rotation from the relaxed position of the soft tissues.

2. Malrotation also occurred on occasion immediately after operation, before the patient had gained good muscle control. The unrestrained lower limb tended to fall into external rotation, and a deformity was produced. Later we began to use an antirotational splint during the early postoperative period.

3. A third cause of malrotation, instability of the fracture, was commonly seen in type-III and IV comminuted fractures[35]. To control rotation in these fractures, we began to use a cerclage wire, a postoperative spica cast, postoperative traction, or a combination of these methods.

4. Malrotation was sometimes observed, presumably because of muscle imbalance, in slightly comminuted or transverse fractures of the proximal one-third of the femur. By the end of the study period, we sometimes used a single-hip spica cast postoperatively if the fracture site approached the proximal limits for the use of an intramedullary nail. Occasionally we opted to use a different implant, such as the Zickel nail.

5. A fifth cause of malrotation was a fall by a patient while walking with crutches. Five patients with a rotational malunion fell at home during the first two to three weeks after nailing. No malunion had been observed in these patients prior to the fall.

Valgus angulation occurred in eight patients in our series; all had a fracture in the distal one-third of the femur. Seven of these deformities were due to technical complications related to the nailing. Inadequate support of the thigh and consequent inadequate reduction of the fracture during the procedure caused the fracture to be nailed in a valgus position[10]. In the eighth patient, a segmental fracture with a distal oblique fracture line slipped after nailing, and the fracture fragments drifted into valgus angulation. The angulation, which ranged from 5 to 11 degrees in the eight patients, was never symptomatic and did not require correction. Toward the end of the series, we began to use cylinder casts or cast-braces for four to six weeks for patients with an unstable distal fracture. Varus angulation occurred in four patients, all with a mid-shaft fracture. The bow of the nail was turned too far laterally, and the nail pushed the fracture into slight varus angulation. The angulation, which did not exceed 5 degrees, was asymptomatic in all patients and did not require correction.

Ten patients had a peroneal-nerve palsy. In six the palsy was caused by the initial injury. In the other four it was related to the surgical procedure; that is, inadequate distraction of the fracture before operation necessitated very strong traction during operation. These four cases of palsy occurred early in the series; recovery was complete in three

patients and about 80 per cent in the fourth. No palsies occurred after we changed the position of the patient on the fracture-table. The uninvolved lower limb is now pulled in a straight line with the body; the extremity to be operated on is slightly flexed at the hip and the knee is kept straight. This position simulates a straight-leg-raising test, and if strong traction is applied the sciatic nerve can be stretched. Therefore, if strong traction is to be used in the operating room, we now insert a femoral pin in the distal part of the femur and keep the knee bent to relax the nerve.

A fat-embolism syndrome, or adult respiratory-distress syndrome, was seen in fifty-five patients and was related to the severity of the initial injury and accompanying shock. These patients were given routine treatment, including pulmonary support. There were no deaths, and all of the patients recovered completely.

There were nine patients with a pulmonary embolism. Eight had multiple injuries and the ninth patient, who died from the embolism, had an isolated femoral fracture.

Discussion

In the present series of 520 femoral-shaft fractures treated by the same method, intramedullary nailing, it is important to note that although we chose that single form of treatment we modified and refined it in important ways over the eleven-year study period. We continue to revise our procedures with experience. We have made major changes in our approach to the patient, in the equipment and technique used for intramedullary nailing, and in the indications for this fixation method with regard to fracture pattern.

In the years encompassed by this study there were major advances in trauma care at our institution, and our over-all approach to patients with fractures of the femur changed accordingly. In 1968, when this series began, the prevalent attitude was that if the patient survived after hours in the emergency room and days or weeks on the hospital ward or in the intensive-care unit, he or she was then considered a candidate for intramedullary nailing. With continued improvements in the care of the trauma victim at every stage of treatment, we gradually changed to a more aggressive approach, and now attempt immediate fracture fixation. The objective is to aid the patient's survival as well as to enhance the function of the limb. Continual upgrading of our city's paramedic system over the past ten years has been important in advancing trauma care, as has the dramatic improvement in the response of the emergency-room staff at our trauma center. In the last seven years, placement of the trauma patient under the care of the general surgeon, with the orthopaedist as the consultant, has also enhanced patient care.

Early in the series our great concern over the possibility of fat embolism from intramedullary reaming and nailing led us to delay the nailing for five to seven days after injury. During the last decade, however, we have performed intramedullary nailing earlier relative to the time of injury, and we have noticed no increase in the incidence of fat embolism. Rapid restoration of fluids in these patients may have aided in preventing this complication. Also, because blood gases were carefully monitored in the intensive-care unit, no deaths occurred from a fat-embolism syndrome alone. With attention to blood-gas measurements, this syndrome was anticipated early and treated promptly in the fifty-five patients who sustained the complication. Studies by Meeks et al.[22] and Riska et al.[28] support our finding that immediate fixation of the femoral fracture does not increase the risk of fat embolism. Furthermore, a primary advantage of early fixation of all long-bone fractures is that it allows earlier mobilization of the patient, thus facilitating pulmonary care and preventing secondary complications related to prolonged bed rest and traction.

As we reached the end of the study period, immediate internal fixation was performed in all patients with multiple long-bone fractures, including those with bilateral femoral fracture or ipsilateral fractures of the femur and tibia and those with a femoral shaft fracture and concomitant injuries to the head, chest, or abdomen. It is important to note that the more seriously injured the patient was, the greater was the need for earlier internal fixation.

Our change, late in the evolution of the regimen, to immediate internal fixation of all grade-I and II open femoral-shaft fractures produced no increase in the number of infections and eased the care of the patients considerably. The increased attention to the nutritional needs of the patients also seems to have contributed to the excellence of our results.

Major modifications have been made in the equipment and surgical technique for intramedullary nailing. Only the basic concept of closed nailing remained the same throughout the series; all of the procedural facets of the regimen itself were refined as our experience grew. We used strong preoperative traction when delayed open reduction was planned, we changed to a better fracture-table and image intensifier, and we modified the patient's position on the table. These three refinements led to a simpler technique for closed reduction of the fracture. A change in the point of insertion for the intramedullary nail, from the tip of the trochanter to the piriformis fossa, prevented eccentric reaming and comminution of the medial part of the femoral cortex; a change in the shape and size[33] of the nail, as technically improved nails became available, led to a decrease in the complications of splitting and further comminution of the bone and also permitted easier passage of the nail across the fracture site; and our emphasis on rehabilitation of the quadriceps also contributed greatly to the improvement in postoperative range of motion of the knee in our patients (average, 132 degrees, with no patient having less than 90 degrees). These results far surpass those obtained with any other method of treating femoral fractures[23].

Although for the younger patient there are alternative methods of fracture treatment with a low risk, we thought that after gaining a few years' experience with intramedullary nailing our technical expertise was sufficiently great, and the complication rate was sufficiently low, to shift the

risk-benefit ratio in favor of intramedullary nailing in this population. Internal fixation of the femoral fracture offered a significant benefit over other methods in younger patients with a head injury, multiple injuries, an open fracture, or an ipsilateral tibial fracture[15].

A review of our results has led us to modify our procedure somewhat with regard to certain fracture patterns. Because our initial approach of performing closed intramedullary nailing for almost all femoral-shaft fractures led to unsatisfactory amounts of rotation[7] and shortening in several types of fractures, we now use interlocking nails in those situations[12,13,16] (Fig. 1), two screws usually being used in the distal fragment and one, in the proximal fragment.

In our experience, transverse fractures in the middle one-third of the femur are ideal for intramedullary nailing, and we have not encountered rotatory malunion in them or in transverse fractures in the distal one-third of the bone. Because significant rotatory malunion has occurred in transverse fractures in the proximal one-third of the bone, we have recently used an interlocking nail with a proximal screw in these fractures.

Oblique fractures present a similar problem. We have found that oblique fractures in the mid-part of the shaft of the femur are well suited for intramedullary nailing, but with oblique fractures in the proximal part of the femur both shortening and rotation may occur because of the wide metaphysis. Shortening and angulation also tend to occur in oblique fractures in the distal part of the femur. Therefore, we now tend to use interlocking nails in oblique fractures near either end of the femur.

Although the patients with a spiral fracture in this series had only about two centimeters of shortening, we found that interlocking nails offered a better treatment option for them as well. Throughout the series, we usually treated spiral fractures with cerclage wiring and intramedullary nailing, but we now believe that the use of interlocking nails is a superior means of maintaining length that still allows us to adhere to the principle of closed reduction. This principle is particularly important in older patients, in whom long spiral fractures predominate.

We have found that segmental fractures can generally be treated with simple closed intramedullary nailing if the perimeter of the cortex in the intercalated segment is intact. If the fracture is near the proximal or distal end of the femur, or if it is comminuted at either fracture site, at present we often use interlocking nails. We carefully assess each level of the fracture to determine where an interlocking nail might be needed (Fig. 1).

Our study showed that type-I comminuted fractures can be treated successfully with intramedullary nailing alone. Type-II fractures of the mid-part of the shaft can be treated with simple intramedullary nailing, but rotational problems in proximal or distal fractures with this degree of comminution have led us to consider the use of interlocking nails. Poor rotatory control and shortening in type-III comminuted fractures have led us to change our treatment for them as well. We found that a spica cast was often necessary for maintaining rotatory control in some of these fractures, or that cerclage wiring was required for reattaching a butterfly fragment to control rotation and maintain length. Blood loss was considerable when cerclage wiring was performed, and although fortunately there were no infections in this group of fractures, the appeal for treating this type of fracture in a closed manner persisted. Although we switched to the use of intramedullary nailing combined with traction, shortening still occurred. Thus, our current preference is to treat type-III comminuted fractures with interlocking nails. Because of the need for control of rotation and length in type-IV comminuted fractures, we treated these with nailing and traction or nailing and cerclage wiring. Since the completion of the study we have switched to the use of interlocking nails in these fractures to maintain closed reduction and allow rapid mobilization of the patient.

The excellent results in our large series suggest that intramedullary nailing is an ideal treatment for patients with a femoral shaft fracture. The fracture patterns that are appropriate for treatment with this method are readily recognizable. When properly selected, femoral shaft fractures can be treated successfully by intramedullary nailing with minimum complications. The immediate use of this method demands that the patient be evaluated carefully for associated injuries and be resuscitated adequately. The technique of intramedullary nailing is demanding, and the constant upgrading of the equipment necessitates up-to-date knowledge. Thus, we recommend that primary nailing not be attempted in the multiply injured patient unless an experienced multidisciplinary team is available to manage potential problems.

NOTE: The authors wish to thank Laurie Glass, Patty VanWagner, and Karen Morten for their assistance.

References

1. BÖHLER, JÖRG: Percutaneous Internal Fixation Utilizing the X-Ray Image Amplifier. J. Trauma, **5:** 150-161, 1965.
2. BÖHLER, JÖRG: Closed Intramedullary Nailing of the Femur. Clin. Orthop., **60:** 51-67, 1968.
3. BORDER, J. R.: Pulmonary and Cardiovascular Failure. *In* Basic Surgery, pp. 41-91. Edited by J. A. McCredie. New York, Macmillan, 1977.
4. CHARNLEY, JOHN, and GUINDY, ADLY: Delayed Operation in the Open Reduction of the Fractures of Long Bones. J. Bone and Joint Surg., **43-B(4):** 664-671, 1961.
5. CHRISTENSEN, N. O.: Technique, Errors and Safeguards in Modern Küntscher Nailing. Clin. Orthop., **115:** 182-188, 1976.
6. CLAWSON, D. K.; SMITH, R. F.; and HANSEN, S. T.: Closed Intramedullary Nailing of the Femur. J. Bone and Joint Surg., **53-A:** 681-692, June 1971.
7. DANCKWARDT-LILLIESTRÖM, GÖRAN, and SJÖGREN, STAFFAN: Postoperative Restoration of Muscle Strength after Intramedullary Nailing of Fractures of the Femoral Shaft. Acta Orthop. Scandinavica, **47:** 101-107, 1976.
8. GHERLINZONI, G.; VASCIAVEO, F.; and MURENA, P. F.: Closed Reduction Reaming and Nailing in Fractures of the Femoral Shaft. Italian J. Orthop. and Traumat., **1:** 117-131, 1975.
9. GUSTILO, R. B.: Management of Open Fractures and Their Complications, p. 19. Philadelphia, W. B. Saunders, 1982.
10. HANSEN, S. T., JR., and WINQUIST, R. A.: Closed Intramedullary Nailing of Fractures of the Femoral Shaft. Technical Considerations. *In*

Instructional Course Lectures, The American Academy of Orthopaedic Surgeons. Vol. 27, pp. 90-108. St. Louis, C. V. Mosby, 1978.
11. HANSEN, S. T., and WINQUIST, R. A.: Closed Intramedullary Nailing of the Femur. Küntscher Technique with Reaming. Clin. Orthop., **138:** 56-61, 1979.
12. HEMPEL, DIETRICH, and FISCHER, SIEGFRIED: Intramedullary Nailing. Translated by Hans Koenig and Thomas Koenig. English edition edited by Benno Lotz. New York, Thieme-Stratton, 1982.
13. KEMPF, I.; GROSSE, A.; and LAFFORGUE, D.: L'apport du verrouillage dans l'enclouage centro-médullaire des os longs. Rev. chir. orthop., **64:** 635-651, 1978.
14. KEY, J. A., and REYNOLDS, F. C.: The Treatment of Infection after Medullary Nailing. Surgery, **35:** 749-757, 1954.
15. KIRBY, R. M.; WINQUIST, R. A.; and HANSEN, S. T., JR.: Femoral Shaft Fractures in Adolescents: A Comparison Between Traction Plus Cast Treatment and Closed Intramedullary Nailing. J. Pediat. Orthop., **1:** 193-197, 1981.
16. KLEMM, K., and SCHELLMANN, W. D.: Dynamische und statische Verriegelung des Marknagels. Monatsschr. Unfallheilk., **75:** 568-575, 1972.
17. KOOTSTRA, GAUKE: Femoral Shaft Fractures in Adults. A Study of 329 Consecutive Cases with a Statistical Analysis of Different Methods of Treatment. Assen, The Netherlands, Van Gorcum, 1973.
18. KÜNTSCHER, G.: Die Marknagelung von Knochenbrüchen. Arch. klin. Chir., **200:** 443-455, 1940.
19. KÜNTSCHER, GERHARD: Practice of Intramedullary Nailing. Translated by H. H. Rinne. Springfield, Illinois, Charles C Thomas, 1967.
20. LAM, S. J.: The Place of Delayed Internal Fixation in the Treatment of Fractures of the Long Bones. J. Bone and Joint Surg., **46-B(3):** 393-397, 1964.
21. MACAUSLAND, W. R., JR.: Treatment of Sepsis after Intramedullary Nailing of Fractures of Femur. Clin. Orthop., **60:** 87-94, 1968.
22. MEEKS, R.; VIVODA, E.; and CREIGHTON, A.: Comparison of Mortality in Multiply Injured Patients According to the Type of Fracture Pattern. Read at the Annual Meeting of the Canadian Orthopaedic Association, Calgary, Alberta, June 9, 1980.
23. MIRA, A. J.; MARKLEY, KITTY; and GREER, R. B., III: A Critical Analysis of Quadriceps Function after Femoral Shaft Fracture in Adults. J. Bone and Joint Surg., **62-A:** 61-67, Jan. 1980.
24. MÜLLER, M. E.; ALLGÖWER, M.; and WILLENEGGER, H.: Manual der Osteosynthese. Berlin, Springer, 1969.
25. NICHOLS, P. J. R.: Rehabilitation after Fractures of the Shaft of the Femur. J. Bone and Joint Surg., **45-B(1):** 96-102, 1963.
26. PEDERSEN, H. E., and SERRA, J. B.: Injury to the Collateral Ligaments of the Knee Associated with Femoral Shaft Fractures. Clin. Orthop., **60:** 119-121, 1968.
27. RASCHER, J. J.; NAHIGIAN, S. H.; MACYS, J. R.; and BROWN, J. E.: Closed Nailing of Femoral-Shaft Fractures. J. Bone and Joint Surg., **54-A:** 534-544, April 1972.
28. RISKA, E. B.; VON BONSDORFF, H.; HAKKINEN, S.; JAROMA, H.; KIVILUOTO, O.; and PAAVILAINEN, T.: Prevention of Fat Embolism by Early Internal Fixation of Fractures in Patients with Multiple Injuries. Injury, **8:** 110-116, 1976.
29. ROKKANEN, P.; SLATIS, P.; and VANKKA, E.: Closed or Open Intramedullary Nailing of Femoral Shaft Fractures? A Comparison with Conservatively Treated Cases. J. Bone and Joint Surg., **51-B(2):** 313-323, 1969.
30. ROTHWELL, A. G.: Closed Küntscher Nailing for Comminuted Femoral Shaft Fractures. J. Bone and Joint Surg., **64-B(1):** 12-16, 1982.
31. SMITH, J. E. M.: The Results of Early and Delayed Internal Fixation of Fractures of the Shaft of the Femur. J. Bone and Joint Surg., **46-B(1):** 28-31, 1964.
32. SOTO-HALL, RALPH, and HORWITZ, THOMAS: The Treatment of Compound Fractures of the Femur. J. Am. Med. Assn., **130:** 128-134, 1946.
33. WINQUIST, R. A., and FRANKEL, V. H.: Complications of Implant Use. *In* Complications in Orthopaedic Surgery, edited by C. H. Epps, Jr. Vol. 1, pp. 99-127. Philadelphia, J. B. Lippincott, 1978.
34. WINQUIST, R. A., and HANSEN, S. T., JR.: Segmental Fractures of the Femur Treated by Closed Intramedullary Nailing. J. Bone and Joint Surg., **60-A:** 934-939, Oct. 1978.
35. WINQUIST, R. A., and HANSEN, S. T., JR.: Comminuted Fractures of the Femoral Shaft Treated by Intramedullary Nailing. Orthop. Clin. North America, **11:** 633-648, 1980.
36. WINQUIST, R. A.; HANSEN, S. T., JR.; and PEARSON, R. E.: Closed Intramedullary Shortening of the Femur. Clin. Orthop., **136:** 54-61, 1978.