Posterolateral Rotatory Instability of the Elbow: Part I. Mechanism of Injury and the Posterolateral Rotatory Drawer Test

Christopher L. Camp, M.D., Jay Smith, M.D., and Shawn W. O'Driscoll, M.D., Ph.D.

Abstract: Posterolateral rotatory instability (PLRI) is the most commonly encountered pattern of elbow instability. It is the result of disruption of the lateral collateral ligament complex leading to a posterolateral rotatory subluxation of the ulna and radial head. A number of examination maneuvers have been described to assist in clinical identification of PLRI. Despite this, some inconsistency in the description of these techniques remains in the orthopaedic literature. This Technical Note details the mechanism of injury and patient presentation, and emphasizes the primacy of the posterolateral rotatory drawer test in the assessment of PLRI while providing video instruction on how it should be performed.

The elbow is the second most commonly dislocated large joint in the body, with posterolateral rotatory instability (PLRI) being the most frequently observed pattern of instability.[1,2] Since its initial description in 1991, the mechanism, evaluation, and treatment of PLRI of the elbow has been studied in detail.[3] PLRI typically occurs as a result of a fall on the outstretched hand, generating an axial load, valgus force, and an external rotational moment (torque) about the forearm with respect to the humerus (Fig 1).[3] This causes the radial head and proximal ulna to subluxate posterolaterally away from the humerus in a rotatory fashion detaching or tearing the lateral collateral ligament (LCL) complex (stage 1: PLRI, Fig 2). With greater displacement, tissue disruption progresses anteriorly and posteriorly around the elbow to the medial side. In the process, the capsule is detached or torn (stage 2: perched dislocation, Fig 2). If the elbow fully dislocates, the soft tissue disruption progresses to involve the medial collateral ligament, which is typically peeled off bone (stages 3a and b). With further displacement, the dislocation forces continue to detach or tear the common flexor pronator origin, resulting in a grossly unstable elbow (stage 3c). The proximal radioulnar joint typically remains reduced due to the restraint provided by the annular ligament and forearm soft tissues.[1,3,4]

The most common cause of PLRI is trauma, but it may be associated with tennis elbow or iatrogenic injury from prior lateral elbow surgery.[4] It may also present as a tardy PLRI caused by cubitus varus from malunion of a childhood supracondylar humerus fracture.

To date, a number of physical examination techniques have been described including the posterolateral rotatory drawer test, lateral pivot-shift test, and various push-up tests (tabletop relocation test, chair push-up test, and prone push-up test).[1,3,5-8] These tests have been described numerous times in the literature and are occasionally reported in modified or inaccurate terms compared with their original descriptions. As a result, some confusion persists regarding the optimal method for evaluating PLRI in the clinical setting. The purpose of this Technical Note is to give clarity to the clinical evaluation of lateral elbow instability. Specifically, in Part I, we seek to provide descriptive and video instruction (Video 1) on the mechanism of injury of PLRI, detail the patient presentation, and demonstrate the posterolateral rotatory drawer test (Table 1). In Part II, supplementary physical examination maneuvers are described and dynamic imaging tests (fluoroscopic and ultrasonographic) are shown.

From the Department of Orthopedic Surgery and the Sports Medicine Center (C.L.C., S.W.O.); and Department of Physical Medicine and Rehabilitation and the Sports Medicine Center (J.S.), Mayo Clinic, College of Medicine, Rochester, Minnesota, U.S.A.

The authors report the following potential conflicts of interest or sources of funding: J.S. receives support from Sonex Health and Tenex Health. S.W.O. receives support from Tornier, Acumed LLC, and Aircast.

Received July 21, 2016; accepted October 18, 2016.

Address correspondence to Christopher L. Camp, M.D., Department of Orthopedic Surgery and the Sports Medicine Center, Mayo Clinic, College of Medicine, 200 First St., SW, Rochester, MN 55905, U.S.A. E-mail: camp.christopher@mayo.edu

2212-6287/16697/$36.00

http://dx.doi.org/10.1016/j.eats.2016.10.016

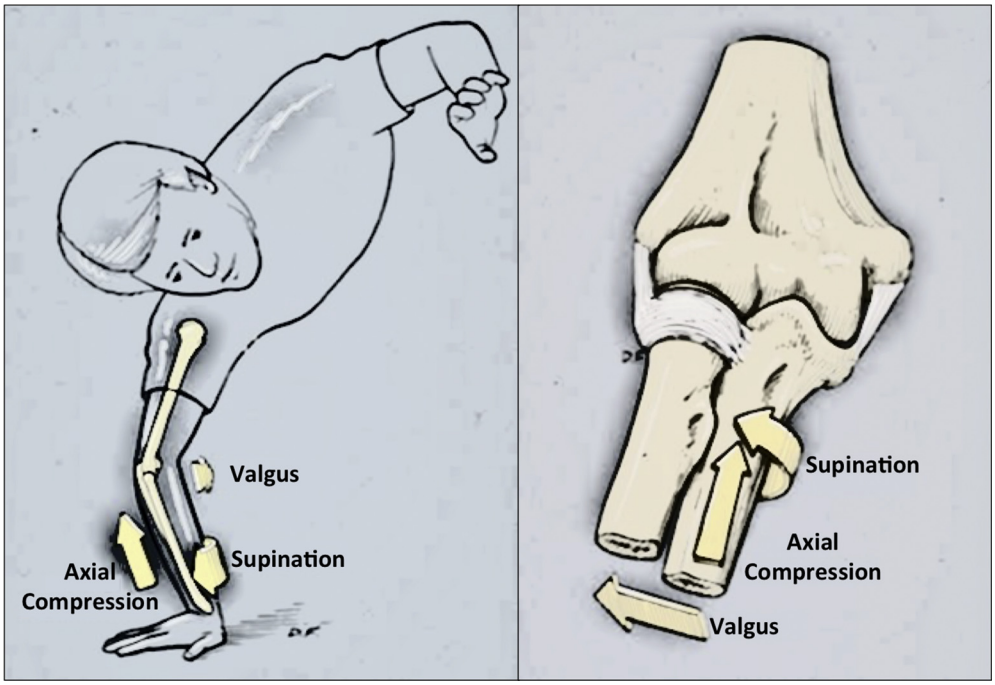

Fig 1. Posterolateral rotatory instability typically occurs as a result of a fall on the outstretched arm with the elbow initially in the extended position. As an axial load is applied to the arm, the elbow sustains a valgus moment and the distal humerus internally rotates against the forearm that is fixed to the ground. This results in relative supination of the forearm relative to the humerus. This combination of axial load, valgus force, and supination results in disruption of the lateral collateral ligament as the radial head and coronoid rotate posterolaterally off the distal humerus. Typically, the radius and ulna rotate together as a unit.

Evaluation Techniques

Patient History

There are 3 broad categories of presentation. Those in the first group (representing the majority of patients) present with mechanical symptoms of instability after elbow trauma. In most cases, the patient has experienced an elbow dislocation or subluxation, sometimes a fracture dislocation. Occasionally, the patient is not aware of actual instability, but complains of snapping, clicking, or a clunk.

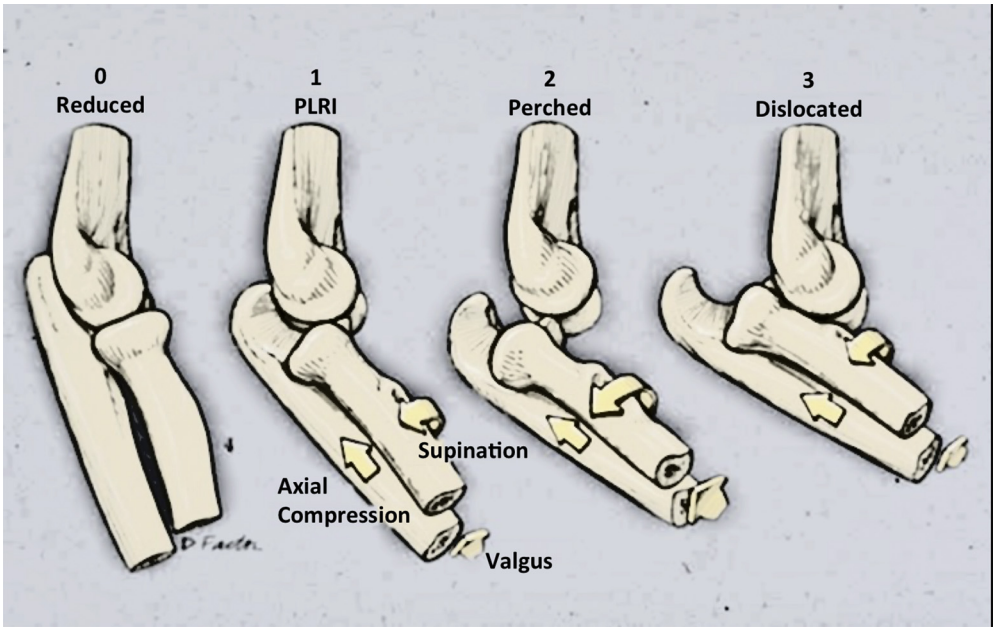

Fig 2. In the original classification of posterolateral rotatory instability, stage 1 represents lateral collateral ligament (LCL) injury, sometimes just the ulnar part of the LCL. In stage 2, the elbow continues to subluxate into a partial or perched dislocation. This corresponds to complete detachment of the LCL, part of the common extensor tendon origin, and a significant portion of the anterior and posterior capsule. Stage 3 represents a posterior elbow dislocation with incomplete (stage 3a) or complete (stage 3b) medial collateral ligament disruption. Stage 3c also includes avulsion or tearing of the common flexor-pronator origin from the medial epicondyle.

Table 1. Pearls and Pitfalls for Evaluating Posterolateral Rotatory Instability (PLRI) of the Elbow

Pearls	Pitfalls
Most common cause is trauma, whereas secondary causes include tennis elbow, iatrogenic injury, and tardy PLRI from cubitus varus or dysplasia	Failure to take a thorough history (trauma, prior surgery, etc.) will make diagnosis more difficult to make
Mechanism of injury is axial load, valgus, and a torque at the elbow causing external rotation of the forearm with respect to the humerus (but not necessarily supination of the radius with respect to the ulna)	Patients may present primarily with vague, lateral-sided pain rather than complaining of overt symptoms of instability
Soft tissue injury begins with the lateral collateral ligament complex and may progress around anteriorly and posteriorly (Horii circle) to disrupt the medial collateral ligament and even the common flexor pronator tendon origin	Patients with repetitive or voluntary instability can develop chondral injury or dysplasia of the radial head (especially if skeletally immature)
Patients typically complain of mechanical symptoms of instability, often with pain	If dysplasia is present, it may need to be addressed in addition to reconstruction of the lateral ulnar collateral ligament
The posterolateral rotatory drawer test is the most reliable examination maneuver in that it is highly sensitive and specific in experienced hands	Inadequate patient trust and relaxation will limit the utility of the examination
It is important to gain the patient's trust and relaxation during the examination	
Acute repair, or delayed reconstruction, of the lateral ulnar collateral ligament is the mainstay of treatment	

If the elbow has a tendency to remain subluxated for more than a few seconds during instability episodes, patients may have noticed a "bump" (prominent radial head) and/or a "dimple" (posterolateral capsule sucked into the joint). Occasionally, patients are able to reproduce the subluxation and reduction under their own volition.

The second group of patients present with lateral elbow pain, often without mechanical symptoms, and a history of tennis elbow or lateral elbow surgery. PLRI caused by tennis elbow typically presents with pain but no mechanical symptoms of instability. The patients with tennis elbow have often had prior lateral elbow cortisone injections, leading us to suspect that there could be a causal relation between the instability and the injections.

The third group of patients present with tardy PLRI due to altered elbow mechanics that cause gradual attenuation of the LCL complex.[9] These include, but are not limited to, patients with cubitus varus from a childhood supracondylar malunion and patients with dysplasia or hypoplasia of the coronoid (especially the anteromedial coronoid).

Examination

Clinical examination should include assessment of elbow mechanics and alignment, particularly for cubitus varus. Tests described to assess the integrity of the lateral ulnar collateral ligament and identify PLRI include the posterolateral rotatory drawer test,[7] lateral pivot-shift test (also called the PLRI test),[3] lateral pivot-shift apprehension test,[3] tabletop relocation test,[6] chair push-up test,[8] and prone push-up test.[8] Although each of these maneuvers has merit, the posterolateral rotatory drawer test is the primary examination method used to identify PLRI in the clinic, and it is the test that can most reliably be performed in both the awake and anesthetized patient.

Posterolateral Rotatory Drawer Test

Patient Positioning and Setup. The patient is placed supine with the arm overhead and the examiner standing at the head of the bed. The hand and wrist of the patient are held securely between the examiner's upper arm and chest, leaving both of the examiner's hands free. In this position, the shoulder reaches its limit of external rotation, facilitating control of humeral rotation. For the right elbow, the examiner's left hand is placed on the lateral aspect of the patient's distal humerus with the thumb on the posterior surface over the triceps tendon. The forearm is grasped with the right hand, placing the index and middle fingers along the anterior aspect of the proximal radius, and the thumb on the subcutaneous border of the ulna. For the left elbow, the examiner's hands are reversed.

Patient Relaxation. Patient relaxation is critical and is accomplished by 2 measures. First, by holding the arm securely between the examiner's upper arm and chest, the patient feels secure that the arm is not going to be allowed to slip or fall (Fig 3A). Second, the patient must be convinced that the examiner is not going to make any sudden or painful movements, especially any that might cause or permit the elbow to dislocate. To calm the patient, we explain what we are about to do stating that he or she will feel the elbow slipping around a little bit, but that it should not cause pain or permit the elbow to dislocate. An appropriately performed posterolateral rotatory drawer test should not cause pain.

Examination Maneuvers. The arm is gently moved through a range of motion, and various random movements that minimally stress the elbow are made

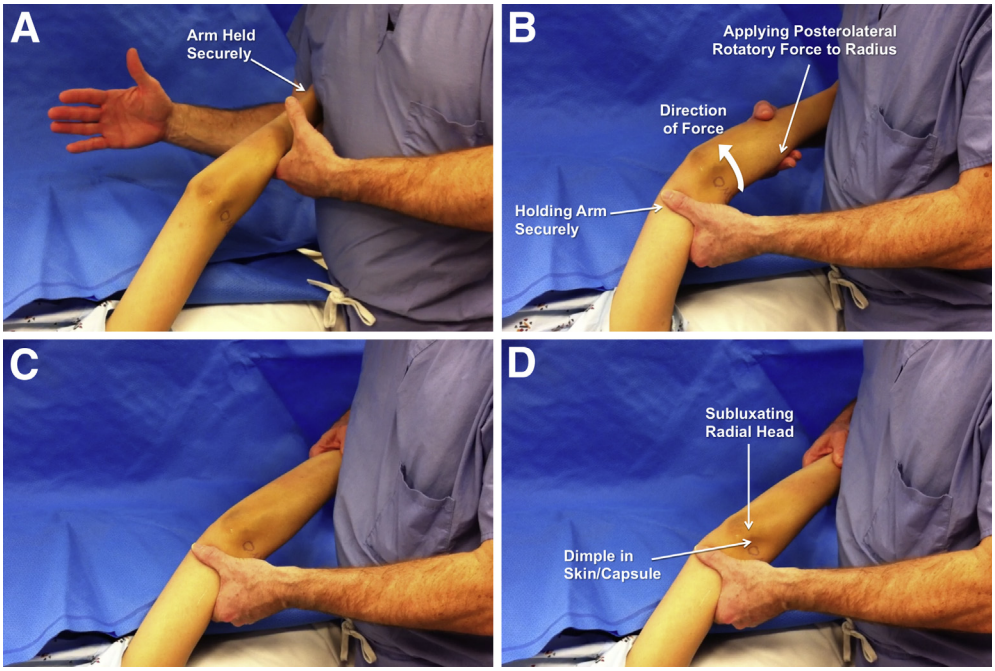

Fig 3. When examining the patient's left elbow, the arm is secured between the right arm and body of the examiner (A). The humerus is held securely with the examiner's left hand, while a posterolateral rotatory force is applied to the proximal radius with the fingertips of the right hand (B). Although maximal instability generally occurs between 20° and 40° of flexion, it should be assessed in multiple angles (C). A positive test is confirmed by a visible posterolateral subluxation of the radial head, which is typically accompanied by dimpling of the skin between the radial head and capitellum (D).

while asking the patient if he or she is experiencing pain. After several such movements without experiencing pain, the patient typically relaxes. When examining a left elbow, a posteriolateral rotatory force is applied to the proximal radius with the fingertips of the right hand while holding the humerus stationary with the left (Fig 3B). Subluxation is usually maximal in the range of 20° to 40°, but the test is repeated at various flexion angles from 0° to 90° to determine the location of maximum instability (Fig 3C). A positive posterolateral rotatory drawer test at a high flexion angle (80° to 90°) is indicative of marked laxity of the posterolateral capsule and not just the LCL. A positive posterolateral rotatory drawer test is indicated by a visible posterior subluxation of the radial head and dimpling of the skin between the radial head and the capitellum (Fig 3D). A confirmatory finding is a clunk perceived by the patient and examiner as it reduces.

Maneuvers to Assess the Severity of Instability. If the patient is able to relax adequately, and is not having too much discomfort, a slight valgus torque can be added to the elbow during the posterolateral rotatory drawer test. This will amplify the mechanical events observed and felt during both the subluxation and reduction. If there is moderate instability, it will result in the radial head momentarily being caught on the capitellum before reducing with a clunk.

Finally, the rotation of the forearm is initially in neutral. Changing the position of forearm rotation may amplify or diminish the response to the test. This is especially true if there is a contour abnormality in the shape of the radial head and/or an impaction defect in the posterior capitellum. However, the posterolateral rotatory drawer test itself does not involve actively subluxating the elbow by a supination torque (which used in the lateral pivot-shift test).

Discussion

PLRI is the most common pattern of elbow instability, and it occurs as a result of axial load, valgus force, and supination of the forearm (which can be relative, due to internal rotation of the humerus on a fixed forearm). The radius and ulna subluxate off the humerus, whereas the radioulnar joint remains reduced.[2,3,7] To date, a number of methods for evaluating PLRI have been described. Of these, the posterolateral rotatory drawer test is the most sensitive and reliable method for evaluating PLRI in the awake and anesthetized patient. When precise steps are followed, it can be performed in a predictable and

Table 2. Strengths and Limitations of the Posterolateral Rotatory Drawer Test

Strengths	Limitations
Most sensitive examination maneuver	Not always performed or described accurately
Allows assessment of the degree of instability	
Can be performed in the awake and anesthetized patient	
Does not cause pain or discomfort for the patient	

pain-free manner. The posterolateral rotatory drawer test has a number of distinct advantages such as follows: it can reliably be performed in the clinic and OR allowing for appropriate preoperative planning and intraoperative assessment of stability before and after stabilization surgery, permitting intraoperative identification and correction of iatrogenic instability that may result from lateral elbow surgery, and reliable assessment of the degree of instability (Table 2). The main limitations of this examination maneuver are the need for an appropriately relaxed patient and thorough understanding of the technique by the examiner, both of which can easily be overcome using the steps outlined in this Technical Note. Keys to assessing PLRI of the elbow include a detailed history focusing on the mechanism of injury and current symptoms and a thorough examination including the posterolateral rotatory drawer test (Table 1).

References

1. O'Driscoll SW. Classification and evaluation of recurrent instability of the elbow. *Clin Orthop Relat Res* 2000;(370):34-43.
2. Mehta JA, Bain GI. Elbow dislocations in adults and children. *Clin Sports Med* 2004;23:609-627, ix.
3. O'Driscoll SW, Bell DF, Morrey BF. Posterolateral rotatory instability of the elbow. *J Bone Joint Surg Am* 1991;73:440-446.
4. Sanchez-Sotelo J, Morrey BF, O'Driscoll SW. Ligamentous repair and reconstruction for posterolateral rotatory instability of the elbow. *J Bone Joint Surg Br* 2005;87:54-61.
5. Anakwenze OA, Kancherla VK, Iyengar J, Ahmad CS, Levine WN. Posterolateral rotatory instability of the elbow. *Am J Sports Med* 2014;42:485-491.
6. Arvind CH, Hargreaves DG. Tabletop relocation test: A new clinical test for posterolateral rotatory instability of the elbow. *J Shoulder Elbow Surg* 2006;15:707-708.
7. O'Driscoll SW, Jupiter JB, King GJ, Hotchkiss RN, Morrey BF. The unstable elbow. *Instr Course Lect* 2001;50:89-102.
8. Regan W, Lapner PC. Prospective evaluation of two diagnostic apprehension signs for posterolateral instability of the elbow. *J Shoulder Elbow Surg* 2006;15:344-346.
9. O'Driscoll SW, Spinner RJ, McKee MD, et al. Tardy posterolateral rotatory instability of the elbow due to cubitus varus. *J Bone Joint Surg Am* 2001;83:1358-1369.